

Immunohistochemical comparison of E-cadherin expression in oral lichen planus with and without dysplasia

Soudabeh Sargolzaei,^{a*} and Fatemeh Mohamadian^b

^aDepartment of Oral Pathology, School of Dentistry, Shahid Beheshti University of Medical Sciences, Tehran, Iran.

^bPrivate Dentist, Tehran, Iran.

*Correspondence to: Sargolzaei S. (email: soudabehsargolzaei@gmail.com).

(Submitted: 07 February 2017 – Revised version received: 30 April 2017 – Accepted: 02 May 2017 – Published online: Winter 2017)

Objectives E-cadherin is a transmembrane glycoprotein, which is responsible for cell adhesion and its expression decreases in dysplastic lesions. This study aimed to assess the expression of this marker in oral lichen planus (OLP) with and without dysplasia to assess its potential for use as a predictor of malignant transformation.

Methods This descriptive, cross-sectional study was conducted on 44 OLP specimens using immunohistochemistry (IHC) by streptavidin-biotin technique. For this purpose, E-cadherin antibody was used and the intensity score (IS), proportional score (PS) and total score (TS) were calculated. Data were analyzed using SPSS version 21. The relationship between the intensity of expression of E-cadherin and dysplastic changes was assessed using the Mann Whitney U test. $P < 0.05$ was considered significant.

Results The TS of E-cadherin expression was 3 to 6 and 3 in the superficial and deep layers of 100% of specimens with dysplasia, respectively. The TS of E-cadherin expression was 3 to 6 in the superficial layer of 82.5% of specimens and 3 in deep layers of 81.2% of specimens without dysplasia. According to the Mann Whitney U test, the expression of E-cadherin in the superficial ($P = 0.90$) and deep ($P = 0.35$) layers was not significantly different between the two groups of OLP with and without dysplasia.

Conclusion No significant difference was found in the expression of E-cadherin in OLP specimens with and without dysplasia. It may be concluded that in contrast to other preneoplastic lesions, dysplastic changes of OLP do not follow other malignant transformation patterns in the oral mucosa.

Keywords cadherins, lichen planus, oral, immunohistochemistry

Introduction

Lichen planus (LP) is a common inflammatory disease of the skin and mucosa, which also involves the oral epithelium. First introduced in 1869, this disease affects approximately 0.5–1% of the world's population; out of which, 50% develop cutaneous and 25% only manifest oral mucosal lesions.^{1,2} Cutaneous LP may manifest in the form of a small wound (usually 2 cm in diameter), which may even reach 3 cm in diameter. Cutaneous LP lesions are often itchy and may manifest as white to purple bilateral papules.³

Oral LP (OLP) is a chronic condition that may last for years and can be accompanied by genital mucosal or cutaneous lesions. OLP may occur in all parts of the oral cavity; however, it most commonly involves the buccal mucosa, the tongue and gingiva. These lesions often appear bilaterally and symmetrically in different forms such as papules, erosive plaque, reticular lesion, atrophic lesion or bullous lesion. Clinically, the reticular, papule and plaque types are painless white keratotic lesions; whereas, erosive, atrophic and bullous lesions cause burning sensation in the mouth and are associated with moderate to severe pain.⁴⁻⁶ Although no definite etiology has been found for LP, most researchers believe that it is an inflammatory autoimmune disease.⁷

The World Health Organization classifies OLP as a potentially malignant condition; although the risk of malignancy of oral LP is lower than that of leukoplakia and erythroplakia. Risk of malignant transformation of OLP to oral squamous cell carcinoma (OSCC) is 0.4 to 5% in a mean period of four years; thus, it can be stated that LP is a preneoplastic lesion.⁸

Pre-neoplastic lesions are those with a higher risk of transformation to neoplasms than the healthy tissues.⁹ Microscopically, these lesions show variable degrees of specific microscopical changes referred to as dysplasia.¹⁰ Oral epithelial dysplastic lesions may show different phenotypes of different stages of progression ranging from a normal healthy tissue to a neoplastic lesion. This malignant transformation can be categorized into three groups of mild, moderate and severe based on the degree of abnormality of the cells and thickness of dysplastic layers compared to healthy tissue. Assessment of the degree of malignancy can serve as a predictor of disease condition and prognosis.¹¹

Expression of several markers in OLP can increase the risk of its malignant transformation to OSCC; out of which, ALDH1, P53, BCL2, BAX, CD133, E-cadherin and PCNA can be named.¹²⁻¹⁵ Expression of COX2 and MMP is high in OSCC; moreover, these factors are rarely expressed in healthy mucosal tissue, moderately in LP and highly in OSCC; thus, their expression is an indicator of higher potential for malignancy.¹⁶ Considering the fact that dysplastic changes occur in many cases of OLP and its malignant transformation to OSCC has been frequently reported, it is particularly important to be able to predict its malignant transformation to OSCC as in leukoplakia and other preneoplastic lesions. Several studies have assessed the expression of E-cadherin in OSCC and also in different types of leukoplakia with variable degrees of epithelial dysplasia. However, studies on the expression of this marker in oral LP with and without dysplasia and those transformed to OSCC are scarce. Thus, this study sought to assess

Table 1. Frequency distribution of specimens based on the location of lesions

Type of lesion	Buccal mucosa	Gingiva	Tongue	Hard palate	Floor of the mouth	Total
OLP with dysplasia	6(50%)	2(16%)	2(16%)	1(8.3%)	1(8.3%)	12(100%)
OLP without dysplasia	22(68.8%)	6(18.7%)	4(12.5%)	0(0%)	0(0%)	32(100%)

the expression of E-cadherin in different types of OLP to find out whether this marker can be used to predict the risk of malignant transformation to OSCC.

Methods

This descriptive cross-sectional study was conducted on patient records and formalin-fixed, paraffin-embedded tissue blocks retrieved from the archives of the Department of Pathology, School of Dentistry, Shahid Beheshti University of Medical Sciences, from 2004 to 2014 with definite diagnosis of OLP whose diagnoses were confirmed by the pathologist of our team. This study was approved in the ethics committee of our university (code:157). Sampling was census. All tissue samples including 111 slides with definite diagnosis of OLP were retrieved; out of which, 67 were excluded due to tissue inadequacy. Thus, 44 specimens with adequate tissue remained in the study. A questionnaire asking for the age and sex of each patient, site of lesion and its microscopic diagnosis was filled out for each case based on the data extracted from patient records. The respective slides were retrieved and evaluated by a pathologist to confirm the primary diagnosis and assess the presence/absence of dysplasia. The sections were deparaffinized with xylene and rehydrated in graded ethanol, then to block endogenous peroxidase activity they were incubated in 0.3% hydrogen peroxidase in methanol for 30 minutes at room temperature. For antigen retrieval, specimens were incubated with retrieval solution (Tris 1/21; code 8382E510221 + EDTA 0.37 g; Merck, Darmstadt, Germany) with a PH of 6 for 15 minutes in a microwave. Then, the tissue specimens were incubated with primary antibodies at room temperature for one hour. For this purpose, E-cadherin monoclonal mouse anti-human antibody (Clone NCH-38, code M3612; Dako, Glostrup, Denmark) was used. The indirect peroxidase system En Vision Kit (Dako Real Envision + system+ HRP Rabbit/Mouse K 3468) was used. To visualize the staining, the sections were reacted by 3,3'-diaminobezidine (DAB, Code:K3468; Dako, Glostrup, Denmark). The specimens were subsequently counterstained with Mayer's hematoxylin and mounted. Invasive ductal carcinoma of the breast was used as the positive control and the healthy adjacent epithelium was used as the internal positive control. For the negative control, staining was done in absence of primary antibody and TBS was used instead of it.

Staining was considered positive when the cell membrane and cytoplasm of the epithelial cells showed abnormal staining. Expression of E-cadherin was assessed using the following two scales: The intensity score (IS) for staining quality and the proportional score (PS) or the percentage of stained cells. The total score (TS) was defined as the sum of IS and PS. Number of stained cells in the superficial and deep layers was determined under a light microscope. Based on the percentage of staining, four categories were defined for stained cells in the superficial layer as follows: Score 0: <50%, score 1: 50%–69%, score 2: 70%–89%, score 3: ≥90%. Based on the intensity of staining

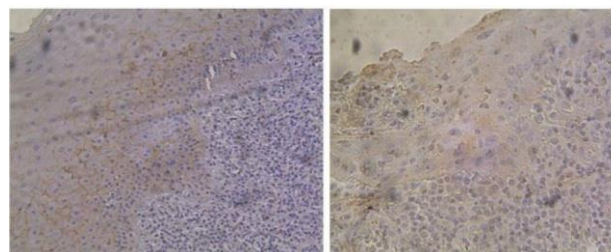


Fig 1. E-cadherin expression in superficial and deep layers of epithelial tissue of OLP. (A) High expression in superficial and low expression in deep layers of OLP without dysplasia. (B) No expression in superficial and deep layers of OLP with dysplasia. (A) x100, (B) x200.

(IS) of the cells in the superficial layer, four categories were defined: Score 0: –, score 1 = + (mild), score 2 = ++ (moderate), score 3: +++ (strong). Based on the number and percentage of stained cells in deep layers, four groups were defined: Score 0: <30%, score 1: 30% < PS < 90%, score 2: 100%. Based on the IS of cells in deep layers, two categories were defined: Score 0: No (negative) staining, score 1: positive staining.

Statistical Analysis

Data were analyzed using SPSS version 21 (SPSS Inc., IL, USA). The relationship between the immunoexpression of E-cadherin and presence of dysplasia in OLP was assessed by the Mann Whitney U test. Level of significance was set at $P < 0.05$.

Results

For intra-rater agreement, immunoexpression was evaluated two weeks later. For inter-rater agreement, another pathologist evaluated the specimens. Of all OLP specimens, dysplasia was present in 27.3% ($n = 12$) and absent in 72.7% ($n = 32$). Of OLP tissue specimens with dysplasia, 41.6% ($n = 5$) belonged to males and 58.3% ($n = 7$) belonged to females. Of OLP specimens without dysplasia, 31.3% ($n = 10$) belonged to males and 68.8% ($n = 22$) belonged to females. Fisher's exact test showed no significant difference between the two groups with and without dysplasia in terms of gender ($P = 0.72$). The mean age of patients was 51.1 years (range 38 to 75 years) and 52.8 years (range 31–75 years) in OLP with and without dysplasia groups, respectively. Independent t -test showed no significant difference in the mean age of patients between the two groups ($P = 0.69$). Table 1 shows the frequency distribution of specimens based on the location of lesions (Table 1).

In OLP specimens with dysplasia, the severity of dysplasia was mild in 91.6% ($n = 11$), moderate in 8.3% ($n = 1$) and severe in 0% ($n = 0$) (Fig. 1).

Table 2 shows the scores of staining of the superficial layer for E-cadherin. As seen in Table 2, score 2 of IS had the highest frequency (56.8%, $n = 25$); out of which, 18 (40.9%) were non-dysplastic while seven (15.9%) were dysplastic lesions. According to the Mann Whitney U test, the IS of the

Table 2. Frequency distribution of E-cadherin scores in the deep layer of epithelium

	Score	With dysplasia (number and percentage)	Without dysplasia (number and percentage)	Total	P value
IS	0	0(0)	1(3.1)	1(2.2)	$P = 0.76$
	1	4(33.3)	11(34.3)	15(34)	
	2	7(58.3)	18(56.2)	25(56.8)	
	3	1(8.3)	2(6.2)	3(6.8)	
PS	0	0(0)	3(9.3)	3(6.8)	$P = 0.96$
	1	4(33.3)	5(15.6)	9(20.4)	
	2	1(8.3)	6(18.7)	7(15.9)	
	3	7(58.3)	18(56.2)	25(56.8)	
TS	0	0(0)	1(3.1)	1(2.2)	$P = 0.90$
	1	0(0)	1(3.1)	1(2.2)	
	2	0(0)	2(6.2)	2(4.5)	
	3	3(25)	5(15.6)	8(18)	
	4	6(50)	12(37.5)	19(43.1)	
	5	3(25)	10(31.2)	13(29.5)	
	6	0(0)	1(3.1)	1(2.2)	

superficial layer for E-cadherin was not significantly different between the two groups of with and without dysplasia ($P = 0.76$). Score 3 of PS had the highest frequency among both dysplastic (58.3%, $n = 7$) and non-dysplastic (56.2%, $n = 18$) lesions. Based on the results of the Mann Whitney U test, the PS of the superficial layer for E-cadherin was not significantly different between the two groups of with and without dysplasia ($P = 0.96$). Score 4 of TS had the highest frequency in dysplastic (50%, $n = 6$) and non-dysplastic (37.5%, $n = 12$) lesions. According to the Mann Whitney U test, the TS of expression of E-cadherin in the superficial layer was not significantly different between the two groups of with and without dysplasia ($P = 0.90$).

Table 3 shows the frequency distribution of three scores in the deep layers. The IS for E-cadherin in the deep layers was score 1 in 100% ($n = 12$) of specimens in the dysplastic and 96.8% ($n = 31$) of specimens in the non-dysplastic group. The frequency of score 0 was 0% ($n = 0$) in the dysplastic and 3.1% ($n = 1$) in the non-dysplastic group. According to the Mann Whitney U test, the difference in this regard between the two groups was not significant ($P = 0.73$). Score 2 of PS had 100% frequency ($n = 12$) in dysplastic specimens. Score 2 also had the highest frequency (81.2%, $n = 26$) in the non-dysplastic group. According to the Mann Whitney U test, the PS of expression of E-cadherin in the deep layers was not significantly different between the two groups of with and without dysplasia ($P = 0.35$). Score 3 of TS was noted in 100% of dysplastic specimens ($n = 12$) while 81.2% ($n = 26$) of non-dysplastic specimens showed score 3. According to the Mann Whitney U test, the TS of expression of E-cadherin in the deep layer was not significantly different between the two groups of with and without dysplasia ($P = 0.35$).

Table 3. Frequency distribution of the PS and TS for E-cadherin in the deep layers

	Score	With dysplasia (number and percentage)	Without dysplasia (number and percentage)	Total	P value
IS	0	0(0)	1(3.1)	1(2.2)	$P = 0.73$
	1	12(100)	31(96.8)	43(97.7)	
PS	0	0(0)	4(12.5)	4(9)	$P = 0.35$
	1	0(0)	2(6.2)	2(4.5)	
	2	12(100)	26(81.2)	38(86.3)	
TS	0	0(0)	4(12.5)	3(6.3)	$P = 0.35$
	1	0(0)	1(3.1)	1(2.2)	
	2	0(0)	2(6.2)	2(6.3)	
	3	12(100)	26(81.2)	38(86.4)	

Of 12 dysplastic OLP lesions, in four specimens (33.3%), 50–69% of the cells were stained in the superficial layer. In one specimen (8.3%), 70–89% of superficial cells and in seven specimens, more than 90% of the superficial cells were stained.

Of 32 non-dysplastic OLP specimens, in three (9.3%), less than 50% of the cells were stained in the superficial layer. In five (15.6%), 50–69% of the cells, in six (18.7%), 70–89% of the cells and in 18 (56.2%) more than 90% of the cells were stained.

In all 12 dysplastic LP specimens, all the cells were stained in deep layers.

Of 32 non-dysplastic specimens, in four (12.5%) less than 30% of the cells were stained in deep layers; in two (4.5%), 30–90% and in 26 (86.2%) 100% were stained. Based on the Mann Whitney U test, the expression of E-cadherin was not significantly different between the groups ($P > 0.05$).

Also, a case of dysplastic OLP progressed to OSCC was found; despite the reduction in expression of E-cadherin in OSCC, this reduction was not statistically significant ($P > 0.05$).

Discussion

Cell adhesion molecules are proteins located on the surface of cells, which are responsible for adhesion of cells to each other or to the extracellular matrix. These proteins are intramembranous receptors composed of intracellular, intramembranous and extracellular components. The extracellular component is responsible for adhesion to intracellular component, hemophilic binding, adhesion to extracellular matrix and heterophilic binding. Adhesion molecules are divided into two groups of calcium-dependent and non-calcium dependent. The calcium-dependent group includes three groups of cadherins, integrins and selectins. Non-calcium dependent group includes lymphocyte homing receptors and IgSF.¹⁷ Cadherins are part of cell surface glycoproteins that play a critical role in cell adhesion and binding to calcium.^{1,2} Thus, this is referred to as calcium-dependent cell adhesion. At present, more than 16 cadherin molecules have been recognized. Different cadherins have similar structure and are named based on their tissue location. Difference in expression patterns of cadherins and dynamic

changes during development are among the significant properties of this molecular group. Due to the importance of cellular attachment loss in progression of malignant lesions, these markers have been extensively studied.¹⁸

E-cadherin is an intramembranous calcium-dependent glycoprotein found on the surface of most epithelial cells. This 120KD glycoprotein, also known as uvomorulin, L-CAM, ARC-1 and cell-CAM, is expressed in all epithelial cells. Its gene is located at position 16 q 22.1. Cells expressing E-cadherin attach to other cells expressing E-cadherin and do not adhere to cells expressing other types of cadherins.¹⁸⁻²⁰ E-cadherin is expressed in normal oral epithelium in the spinous layer and basal layer. This marker is mainly located in zonula adherens. Its extracellular component contains three domains, which are activated in presence of calcium. When interacted with E-cadherin on the surface of adjacent cells, a firm cell-cell attachment is formed. Its cytoplasmic tail is related to a group of intracellular anchor proteins known as catenins.¹⁸ Studies have shown that cadherins are important predictors of tissue morphology, growth and development and their expression is developmentally adjusted. Evidence shows that cell adhesion mediated by E-cadherin is required for accumulation of mesenchymal cells and their migration towards the epithelium.¹⁸ Assessment of an in vitro model of epithelial injury revealed that destruction of cell-cell attachment via the E-cadherin/catenin axis was associated with cell migration and epithelial regeneration.¹⁸ Cadherin/catenin axis plays an important role in molecular histology of the tumors and any significant change in expression or structure of these components results in a separation in the adherens junction, decreased tumor differentiation and formation of an aggressive phenotype. A significant association has been reported between decreased expression of E-cadherin and beta-catenin with oral epithelial dysplasia²¹ and between normal oral mucosa and OLP lesions;²² however, previous study showed no relationship between OLP and E-cadherin expression.²³ *In vitro* studies have shown that decreased cell adhesion by E-cadherin is associated with invasion and poorly differentiated phenotype in several cell lines of human carcinomas.^{18,24} Expression of E-cadherin has been evaluated in many human malignancies such as adenoma of the pancreas, esophagus, gastric mucosa and colon in vivo. Also, decreased or no expression of E-cadherin along with poorly differentiated phenotype and lymph node involvement in some cancers has been associated with tumor recurrence and higher morbidity and mortality.¹⁸

Recently, EGFR-type I and catenin expression in keratinocytes infected with HPV E7 and E6 protein was evaluated. Immortality of normal human keratinocytes by E6 and E7 changes the subcellular orientation of E-cadherin and catenin with a shift from cell membrane towards an intra-cytoplasmic position with no change in level of expression. Progression towards a more aggressive phenotype capable of invading the collagen is associated with down regulation of E-cadherin and increased expression of EGF-R. Based on a previous study, decreased membranous positioning and expression of the cytoplasmic E-cadherin are directly correlated with the degree of dysplasia seen in stratified squamous epithelium. Thus, as the no expression of E-cadherin is a late occurrence in cervical carcinoma, decreased or deranged expression of E-cadherin and its cellular positioning occur much sooner in the dysplastic phase; this indicates the pivotal role of destruction of E-cadherin/catenin axis in the initiation and progression of

tumors.¹⁸ Also, level of expression of E-cadherin is correlated with the aggressive behavior and poor prognosis, and the lower the expression of E-cadherin, the more aggressive the cancer and the poorer the prognosis.¹⁷

In the recent years, several biological markers have been used to obtain information regarding OSCC such as P53 proto-oncogene, cyclin D1, tyrosine kinase receptors for growth hormone, markers related to neovascularization, increased expression of metalloproteinases and changed expression of cadherins, which are all associated with poor prognosis.¹⁷ Assessment of the role of E-cadherin in determining the prognosis and progression of OSCC revealed that decreased expression of E-cadherin was associated with poor differentiation of cells, aggressive nature of tumor and metastasis.¹⁸

The current study immunohistochemically assessed the expression of E-cadherin in OLP specimens with and without dysplasia. Based on the results, score 3 and higher expression of E-cadherin occurred in the superficial layer of 88% of non-dysplastic specimens; whereas, 100% of dysplastic specimens showed score 3 expression of this marker. Overall, no significant difference was noted in the IS of E-cadherin expression between the two groups. However, decreased expression of E-cadherin in the lesion compared to the adjacent healthy tissue was noted. Although in samples with and without dysplasia, the frequency of score 6 was not significantly different (0% versus 3.1%), since the number of specimens with and without dysplasia was 12 and 32, respectively, this lack of a significant difference may be attributed to the difference in number of specimens in the two groups. Also, in deep layers, 81.3% of non-dysplastic specimens had score 3 expression while 100% of dysplastic samples showed score 3 expression. In deep layers, scores 4, 5 and 6 were not seen in any group. This means that in the deepest epithelial layers of OLP, expression of E-cadherin does not exceed score 3 (moderate expression). In the deepest layer, expression of E-cadherin was slightly higher in dysplastic specimens, but not significantly. In two studies conducted by Neppelberg et al,^{25,26} expression of E-cadherin was assessed in non-dysplastic and dysplastic LP specimens and OSCC. The afore-mentioned two studies were the only ones assessing the reduction in E-cadherin expression in LP specimens with and without dysplasia. They reported the reduction in expression of E-cadherin in LP specimens. However, their first study was a descriptive one and did not compare this reduction with the expression of this marker in other tissues. Instead, it assessed the reduction in expression of this marker in specimens that transformed to OSCC.²⁵ In the second study by Neppelberg et al,²⁶ decreased expression of E-cadherin in an active LP site was compared to that in the healthy adjacent tissue; however, it was also a descriptive study and no quantitative assessment was done. We immunohistochemically compared OLP with and without dysplasia. Search of the literature yielded no similar study for quantitative comparison with the current one. Thus, we compared our results with those of studies on leukoplakia with/without dysplasia. In our study, dysplastic specimens showed higher expression of E-cadherin, but not significantly. This result was different from the results of Kyrodinou et al,²⁷ in their study on different types of dysplastic leukoplakia and OSCC. They showed a significant association between the decreased expression of E-cadherin and increased risk of malignant transformation of dysplastic specimens and their higher aggressiveness and transformation to neoplastic lesions. Also, they qualitatively

showed decreased expression of E-cadherin in the superficial and deep layers.

Von Zeidler et al.¹¹ indicated a significant association between decreased expression of E-cadherin and increased risk of dysplasia in leukoplakia specimens; these results were different from our findings. Also, Santos-García et al,²⁸ immunohistochemically assessed the expression of E-cadherin, laminin and collagen IV in leukoplakia lesions with mild and moderate dysplasia and OSCC and showed a significant association between 20% reduction in expression of E-cadherin in specimens with mild and moderate dysplasia and 90% reduction in expression of E-cadherin in OSCC.²⁸ Ishida et al,²⁹ immunohistochemically assessed beta-catenin in leukoplakia specimens with and without dysplasia and indicated a significant difference in nuclear localization of beta-catenin in leukoplakia specimens with dysplasia compared to healthy tissues.

Asokan et al.³⁰ evaluated epigenetic changes of tumor suppressor genes including p15, p16, MGMT, hMLH and E-cadherin in leukoplakia lesions with and without dysplasia and OSCC and showed a direct association between inactivity of E-cadherin gene and increased risk of malignant transformation. They did not perform immunohistochemistry but reported an association between decreased expression of E-cadherin and increased risk of malignancy in dysplastic lesions. Their findings were in contrast to ours since we found no significant difference in the expression of E-cadherin in specimens with and without dysplasia. This suggests that in addition to decreased expression of E-cadherin, some other mechanisms are probably involved in initiation and malignant transformation of OLP especially in the dysplastic type. In our study, E-cadherin expression decreased in dysplastic

lesions but not significantly, which may be due to small sample size of dysplastic lesions¹¹ compared to those without dysplasia. Thus, future studies on a larger sample size are required to better elucidate this topic. Also, it is suggested to assess the expression of beta-catenin along with E-cadherin in further studies.

Conclusion

Based on the current results, no significant difference was found in the expression of E-cadherin between dysplastic and non-dysplastic OLP lesions. Also, 100% of dysplastic specimens indicated variable degrees of expression of E-cadherin. It may be concluded that presence of dysplasia in OLP does not follow the same molecular pattern as in other oral precancerous lesions such as leukoplakia and therefore it cannot be a direct predictor of the prognosis and malignant transformation of lesions to OSCC.

Acknowledgment

This study was derived from a thesis for DDS degree by Fatemeh Mohamadian, successfully completed under the supervision of Dr. Soudabeh Sargolzaei, Department of Oral and Maxillofacial Pathology, Dental School, Shahid Beheshti University of Medical Sciences, Tehran, Iran. This study was supported by the Research Deputy of Dental School, Shahid Beheshti University of Medical Sciences, Tehran, Iran (code # 12864).

Conflict of Interest

“None Declared.” n

References

- Zakrzewska JM. Oral lichen planus: a review. *Br J Oral Maxillofac Surg*. 2001;39:407.
- Canto AM, Müller H, Freitas RR, Santos PS. Oral lichen planus (OLP): clinical and complementary diagnosis. *An Bras Dermatol*. 2010;85:669–675.
- Scully C, el-Kom M. Lichen planus: review and update on pathogenesis. *J Oral Pathol*. 1985;14:431–458.
- Ismail SB, Kumar SK, Zain RB. Oral lichen planus and lichenoid reactions: etiopathogenesis, diagnosis, management and malignant transformation. *J Oral Sci*. 2007;49:89–106.
- Edwards PC, Kelsch R. Oral lichen planus: clinical presentation and management. *J Can Dent Assoc*. 2002;68:494–499.
- Eisen D. The evaluation of cutaneous, genital, scalp, nail, esophageal, and ocular involvement in patients with oral lichen planus. *Oral Surg Oral Med Oral Pathol Oral Radiol Endod*. 1999;88:431–436.
- Boyd AS, Neldner KH. Lichen planus. *J Am Acad Dermatol*. 1991;25:593–619.
- Shen ZY, Liu W, Zhu LK, Feng JQ, Tang GY, Zhou ZT. A retrospective clinicopathological study on oral lichen planus and malignant transformation: analysis of 518 cases. *Med Oral Patol Oral Cir Bucal*. 2012;17:e943–e47.
- Feller L, Lemmer J. Oral leukoplakia as it relates to HPV infection: A review. *Int J Dent*. 2012;54:0561.
- Neville BW, Damm DD, Allen CM, Chi AC. *Oral and maxillofacial pathology*. 4th ed., Elsevier Co. Canada, 2016; chaps 16:731–732.
- Von Zeidler SV, de Souza Botelho T, Mendonça EF, Batista AC. E-cadherin as a potential biomarker of malignant transformation in oral leukoplakia: a retrospective cohort study. *BMC Cancer*. 2014;14:972.
- Xu Z, Shen Z, Shi L, Sun H, Liu W, Zhou Z. Aldehyde dehydrogenase 1 expression correlated with malignant potential of oral lichen planus. *Ann Diagn Pathol*. 2013;17:408–411.
- Sousa FA, Paradella TC, Carvalho YR, Rosa LE. Immunohistochemical expression of PCNA, p53, bax and bcl-2 in oral lichen planus and epithelial dysplasia. *J Oral Sci*. 2009;51:117–121.
- Sun L, Feng J, Ma L, Liu W, Zhou Z. CD133 expression in oral lichen planus correlated with the risk for progression to oral squamous cell carcinoma. *Ann Diagn Pathol*. 2013;17:486–489.
- Ebrahimi M, Boldrup L, Wahlin YB, Coates PJ, Nylander K. Decreased expression of the p63 related proteins beta-catenin, E-cadherin and EGFR in oral lichen planus. *Oral Oncol*. 2008;44:634–638.
- Li TJ, Cui J. COX-2, MMP-7 expression in oral lichen planus and oral squamous cell carcinoma. *Asian Pac J Trop Med*. 2013;6:640–643.
- Brackenbury R, Rutishauser U, Edelman GM. Distinct calcium-independent and calcium-dependent adhesion systems of chicken embryo cells. *Proc Natl Acad Sci U S A*. 1981;78:387–391.
- El-Bahrawy MA, Pignatelli M. E-cadherin and catenins: molecules with versatile roles in normal and neoplastic epithelial cell biology. *Microsc Res Tech*. 1998;43:224–232.
- Wijnhoven BP, Dinjens WN, Pignatelli M. E-cadherin-catenin cell-cell adhesion complex and human cancer. *Br J Surg*. 2000;87:992–1005.
- Zhong LP, Li J, Zhang CP, Zhu HG, Sun J, Zhang ZY. Expression of E-cadherin in cervical lymph nodes from primary oral squamous cell carcinoma patients. *Arch Oral Biol*. 2007;52:740–747.
- Silva BS, Castro CA, Von Zeidler SL, Sousa SC, Batista AC, Yamamoto-Silva FP. Altered β -catenin expression in oral mucosal dysplasia: a comparative study. *J Appl Oral Sci*. 2015;23:472–478.
- DU Y, Li H. Expression of E-cadherin in oral lichen planus. *Exp Ther Med*. 2015;10:1544–1548.
- Sagari S, Sanadhya S, Doddamani M, Rajput R. Molecular markers in oral lichen planus: a systematic review. *J Oral Maxillofac Pathol*. 2016;20:115–121.
- Rosado P, Lequerica-Fernández P, Fernández S, Allonca E, Villalain L, de Vicente JC. E-cadherin and β -catenin expression in well-differentiated and moderately-differentiated oral squamous cell carcinoma: relations with clinical variables. *Br J Oral Maxillofac Surg*. 2013;51:149–156.
- Neppelberg E, Loro LL, Oijordsbakken G, Johannessen AC. Altered CD40 and E-cadherin expression—putative role in oral lichen planus. *J Oral Pathol Med*. 2007;36:153–160.
- Neppelberg E, Johannessen AC. DNA content, cyclooxygenase-2 expression and loss of E-cadherin expression do not predict risk of malignant transformation in oral lichen planus. *Eur Arch Otorhinolaryngol*. 2007;264:1223–1230.
- Kyrodinou M, Andreadis D, Drougou A, Amanatiadou EP, Angelis L, Barbatis C, et al. Desmoglein-3/ γ -catenin and E-cadherin/ β -catenin

- differential expression in oral leukoplakia and squamous cell carcinoma. *Clin Oral Investig.* 2014;18:199–210.
28. Santos-García A, Abad-Hernández MM, Fonseca-Sánchez E, Julián-González R, Galindo-Villardón P, Cruz-Hernández JJ, et al. E-cadherin, laminin and collagen IV expression in the evolution from dysplasia to oral squamous cell carcinoma. *Med Oral Patol Oral Cir Bucal.* 2006;11:E100–E105.
29. Ishida K, Ito S, Wada N, Deguchi H, Hata T, Hosoda M, et al. Nuclear localization of beta-catenin involved in precancerous change in oral leukoplakia. *Mol Cancer.* 2007;6:62.
30. Asokan GS, Jeelani S, Gnanasundaram N. Promoter hypermethylation profile of tumour suppressor genes in oral leukoplakia and oral squamous cell carcinoma. *J Clin Diagn Res.* 2014;8:ZC09–ZC12.

How to cite:

Sargolzaei S, Mohamadian F. Immunohistochemical Comparison of E-cadherin Expression in Oral Lichen Planus with and without Dysplasia. *J Dent Sch.* 2017;35(1):26–31.