

Prevalence of idiopathic osteosclerosis on cone beam computed tomography images

Zeynab Azizi,^a Hosein Mosaferi,^a Yaser Safi,^a Saivash Dabirzadeh,^b and Zahra Vasegh^{a*}

^aDepartment of Oral and Maxillofacial Radiology, School of Dentistry, Shahid Beheshti University of Medical Sciences, Tehran, Iran.

^bDentist, Tehran, Iran.

*Correspondence to: Vasegh Z. (email: dr.zvasegh@sbmu.ac.ir).

(Submitted: 23 January 2017 – Revised version received: 08 March 2017 – Accepted: 15 April 2017 – Published online: Spring 2017)

Objectives This study was performed to investigate the prevalence of idiopathic osteosclerosis on cone beam computed tomography (CBCT) images of patients.

Methods In this descriptive, cross-sectional study, 240 CBCT scans of patients (125 women, 115 men) referred to a private oral and maxillofacial radiology clinic in Tehran in 2013 were selected and evaluated. Presence of idiopathic osteosclerosis and its features including its location in the jaw, its association with teeth, presence or absence of root resorption, number, shape and size of lesions and age and gender of patients were assessed. Descriptive statistics were reported. Chi-square test and independent *t*-test were used for statistical analysis.

Results Idiopathic osteosclerosis was seen on CBCT images of 20 patients (8.33%). The lesion was more frequent in women than men, but the difference was not significant ($P = 0.50$). Also, the lesion was more common in the mandible than the maxilla (95.6% vs. 4.4%). Most lesions were observed in the molar (56.5%) and premolar (34.7%) areas of the lower jaw. Most lesions did not have any association with teeth (73.9%). More than half of the lesions (56.5%) were round in shape and the rest (43.4%) were irregular. The mean size of the lesions was 5.4 ± 1.8 and 5.7 ± 1.4 mm in the mesiodistal and superior-inferior aspects, respectively.

Conclusion The prevalence of idiopathic osteosclerosis of the jaws on CBCT images of an Iranian population was within the range reported by other studies. The lesions were more common in the mandibular molar region with no relation to teeth.

Keywords cone beam computed tomography, osteosclerosis, prevalence

Introduction

Osteosclerosis is defined as increased calcification and bone formation due to genetics, neoplastic lesions, hematological infections or metabolic or gastrointestinal disorders. Idiopathic osteosclerosis has also been reported.¹⁻⁵ Information about the prevalence of this condition, common age and gender of patients or the common site of involvement can be helpful for differentiating idiopathic osteosclerosis from other lesions with similar radiographic features such as periapical cemento-osseous dysplasia, hypercementosis and cementoblastoma.

Differential diagnosis of this condition is important in that idiopathic osteosclerosis does not require treatment, but some of the lesions in differential diagnosis require therapeutic interventions.⁶

Idiopathic osteosclerosis has been defined as local dense bone formation from endosteal surfaces of cortical bone into the cancellous bone. These bony islands are more common in the mandible than in the maxilla and most cases are seen in the premolar and molar areas.⁷ Generally, these lesions are asymptomatic and in rare cases they may cause external root resorption. In addition, in all cases, the teeth are vital and root resorption is generally self-limited.⁸⁻¹⁰

In radiographic view, lesions are often well-defined, round or oval-shaped without any radiolucency around them and they are directly in contact with the surrounding normal bone and have uniform radiopaque internal structure.⁸ Lesions with well-defined sclerotic borders and a radiolucent rim with dense bone at the center should be ruled out as peripheral cemento-osseous dysplasia or focal cemento-osseous dysplasia.

However, in very rare cases, lesions can cause tooth impaction or tooth displacement.⁸ Some researchers consider

it a reactive phenomenon to mild inflammation caused by slight injuries, pressure imposed on tooth or replacement of primary teeth by permanent teeth. On the other hand, it is believed that idiopathic osteosclerosis may be a developmental process, not a reactive lesion, and such changes in the structure of natural bone are likely to occur in the first three decades of bone maturation.¹¹

At the same time, a number of studies have been conducted on the prevalence of idiopathic osteosclerosis in various communities. The prevalence of idiopathic osteosclerosis has been different due to differences in populations studied as the result of presence of various diagnostic criteria. Thus, the lowest frequency was noted in a Turkish population with a prevalence rate of 2.3%,⁹ while the highest rate was recorded in Americans to be 11%.⁸

Based on the existing data and the differences in the prevalence and characteristics of idiopathic osteosclerosis in different studies, the present study was performed to assess the prevalence of idiopathic osteosclerosis based on age and gender of patients, location of the lesion in the jaw, shape of the lesion, number of lesions, association of lesion with teeth, root resorption and size of lesion in patients referred to a private oral and maxillofacial radiology center in Tehran in 2013.

Methods

This descriptive, cross-sectional study was carried out on 240 CBCT images of patients referred to a private oral and maxillofacial radiology clinic in 2013. For this purpose, CBCT images completely visualizing the patients' upper and lower jaws and had good quality (no artifacts) were selected. CBCT

images were evaluated and the relation of lesions to the tooth root and root resorption caused by the lesions were assessed. The study was approved in the ethics committee of our university (code:165-26.11.93).

As the mean prevalence of the lesion in previous studies^{6,8} was 10%, and with regard to the total number of scans in one-year period in the afore-mentioned center, the number of samples calculated assuming $d = 4\%$ and $\alpha = 0.05$.

These images were prepared using Scanora 3D (Sirona Sordex, Helsinki, Finland) imaging system.

Inclusion criteria

CBCT images completely visualizing the patients' upper and lower jaws with appropriate resolution were included.

Exclusion criteria

Poor quality CBCT images were excluded from the study.

Other Characteristic mixed radiopaque-radiolucent areas of periapical cemental dysplasia and other benign fibro-osseous lesions of periodontal ligamental origin (i.e., diffuse sclerosing osteomyelitis and florid osseous dysplasia).¹¹

Pathologic defects related or non-related to teeth.¹¹

Thickening of lamina dura around the malpositioned teeth.^{11,12}

Bridge or removable partial denture.^{11,12}

Radiopacities in the edentulous areas and exostosis.

The images were evaluated for the presence or absence of lesions and other variables including age, gender, location of the lesion in the jaws, the area of the lesion in each jaw, shape, size and number of lesions and association of lesions with tooth and root resorption.

To identify the lesion location, jaws were divided into anterior, premolars, molars and tuberosity areas in the maxilla as well as retromolar, and ramus areas in the mandible. In addition, the shape of the lesion was described as round or irregular on CBCT images (Fig. 1).

In order to evaluate the relationship between the tooth root and lesion, lesions were divided into four groups according to the criteria set by Geist and Katz:¹³

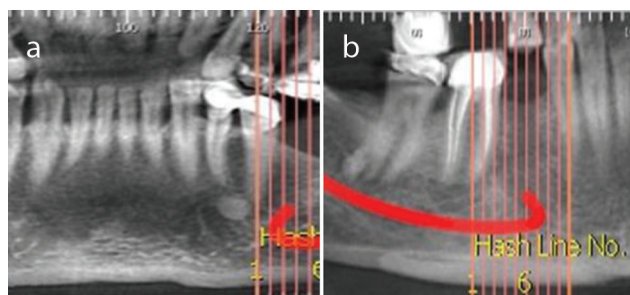


Fig 1. Classification of lesions in a) round or b) irregular.

1. Inter-radicular lesions located between tooth roots.
2. Apical and inter-radicular lesions in the apical region which are clearly located between roots.
3. Apical lesions that are entirely on the apex of roots.
4. Separate lesions that are clearly separate from the root and lamina-dura.

If there was any association between the tooth roots and the lesion, presence or absence of root resorption was also evaluated.

Each lesion was measured in terms of mesiodistal and superior-inferior dimensions.

A qualified observer (a dental student under supervision of an oral and maxillofacial radiologist) observed CBCT images on a standard light box in normal room lighting to detect idiopathic osteosclerosis. After exact assessment of the lesions in the axial, coronal and sagittal planes, osteosclerosis samples were diagnosed and recorded in the charts.

Data analysis

Data were analyzed using SPSS software version 19. The gender of patient and location and shape of lesions were determined and reported. The prevalence of idiopathic osteosclerosis according to gender of patients was analyzed using the Chi-square test. The mean age of patients was analyzed using independent *t*-test. In statistical comparisons, type one error (α) was considered as 0.05%.

Results

In this study, the CBCT scans of 240 patients (125 women, 115 men) were evaluated; 23 idiopathic osteosclerosis lesions were recognized in 20 patients. Based on the results, the prevalence of idiopathic osteosclerosis was 8.33%.

The prevalence rate of idiopathic osteosclerosis was not significantly different between males and females ($P = 0.503$).

Regarding the location of idiopathic osteosclerosis lesions, 22 lesions (95.6%) were in the lower jaw and one lesion (4.4%) was in the upper jaw. Table 1 shows the frequency and prevalence of idiopathic osteosclerosis lesions by location in the jaws.

Out of 23 idiopathic osteosclerosis lesions, 13 (56.5%) lesions were either round or oval and 10 cases (43.4%) were irregular.

The mean size of the lesions was 5.4 ± 1.8 mm in mesiodistal dimension and 5.7 ± 1.4 mm in the upper-lower dimension.

In addition, in one (20%) out of 5 cases with lesions which had apical relation with the tooth root, root resorption was observed.

Patients were between 24–72 years. Based on the results, the mean age in the affected and unaffected individuals was 42.75 ± 12.989 and 44.77 ± 11.49 years, respectively and independent

Table 1. Frequency of idiopathic osteosclerosis lesions in patients based on the affected jaw and location of the lesion in the jaw

Location of lesions	Number	Affected region				Total
		Anterior	Premolar	Molar	Retromolar & ramus/tuberosite	
Upper jaw	1(4.4%)	0	0	1	0	1
Lower jaw	22(95.6%)	1	8	13	0	22
Total of lesions	23 (100%)	1 (4.5%)	8 (36.3%)	14 (59.2%)	0	23 (100%)

Table 2. Frequency and prevalence of relationship between idiopathic

Location of lesion related with teeth	Number of lesion	Percentage
Apical	5	21.7%
Separate	17	73.9%
Inter radicular	1	4.3%
Apical & inter radicular	0	0%
Total	23	100%

t-test showed no statistically significant difference in this respect ($P = 0.509$).

Discussion

Idiopathic osteosclerosis presenting as dense or sclerotic bone changes without any definite etiology are more common in the lower jaw.⁸

The results of the present study showed that the prevalence of idiopathic osteosclerosis was 8.33% in a sample of the Iranian population. Table 3 shows the summary of 6 reports on frequency and gender distribution of idiopathic osteosclerosis in the literature sorted by frequency.

Farhadi et al,⁷ in a study on radiographic characteristics of idiopathic osteosclerosis lesions in patients referred to the Radiology Department of Tabriz Dental School estimated its prevalence rate to be 7.8%. Garau et al,¹⁴ also reported the prevalence of idiopathic osteosclerosis lesions to be 8.3% on panoramic radiographs of a group of Italian population with Sardinian race.

In a study with large sample size conducted by Miloglu et al,⁹ in Turkey, the prevalence of idiopathic osteosclerosis lesions on panoramic radiographs of patients referred to a dental school was reported to be 2.44%. It seems that the difference in prevalence reported in different studies may be due to different imaging methods. In the present study, CBCT was used because of its higher diagnostic value for evaluation of lesions, since it provides images in three planes.

Chia-Hui et al.⁸ studied the prevalence and radiographic characteristics of idiopathic osteosclerosis lesions on CBCT images of subjects from the Taiwanese and American populations. The results showed the prevalence of lesions in Taiwanese and American populations to be 5% and 11%, respectively.

It seems that the higher frequency of idiopathic osteosclerosis lesions in the present study of the Iranian population is due to the genetic factors and higher frequency of these lesions in the Eastern race.^{8,15} On the other hand, lack of a standard definition for idiopathic osteosclerosis affects these differences.

Most researchers reported no significant difference in the frequency of these lesions between men and women.^{8,16} Miloglu et al.⁹ found idiopathic osteosclerosis lesions in 96 women and 54 men. Farhadi et al,⁷ also reported that 4% of men and 10% of women had these lesions. The results of the present study showed that the prevalence of idiopathic osteosclerosis was

6.08% in men and 9.6% in women, which were not significantly different. But Moshfeghi et al.⁶ reported significantly higher prevalence of idiopathic osteosclerosis in women (11.8% vs. 6.3%, $f/m: 1.87; P < 0.01$).

Based on the results of this study, from 23 idiopathic osteosclerosis lesions, 56.5% were in the molar area, 34.7% were in the premolar area, and 4.3% were in the anterior mandible while 4.3% were in the molar area of the maxilla. In the study performed on Sardinian race in Italy, 98.2% of lesions were in the lower jaw, and the first molar area of the mandible had the highest frequency (35%).¹⁴ In the Turkish population, 98.9% of idiopathic osteosclerosis lesions were also located in the mandible and in most cases, lesions were identified in the molar (47.5%) and premolar area (32.6%).⁹ In the study by Farhadi et al,⁷ lesions were mostly in the lower jaw 93% and second premolar 28.1% and first molar 25% (52%) areas were more commonly affected. Chia et al.⁸ and Li et al.¹⁶ reported similar results.

More than half of the lesions in our study were round in shape (56.5%) and the rest were irregular (43.4%). Miloglu et al.⁹ showed that about 70% of lesions had a round shape and 30% had an irregular shape. Farhadi et al.⁷ showed that 28.1% of lesions were round and 40.6% were irregular in shape.

Li et al.¹⁶ studied the demographic and radiographic aspects of dens bone islands in the maxillofacial area in a Chinese population and reported that 40% of the lesions were round in shape and 30% had irregular shape.

According to the present study, 73.9% of idiopathic osteosclerosis lesions were separate, 21.7% were in the apical and 4.3% were in the inter-radicular position. Farhadi et al.⁷ concluded that 40.6% of the lesions were in separate position. In the study by Chia-Hui et al.⁸ on a Taiwanese population, 29% of the lesions were in the apical region and 57% were in a separate position; in the American population, 36% of the lesions were in the apical region and 60% were in a separate position.

Similar to the present study, Miloglu et al.⁹ measured the size of the lesions to be averagely 6.5 mm. Also, Chia-Hui et al.⁸ obtained the average size of the lesions to be 4.6 mm and 6.5 mm in the American and Taiwanese populations, respectively. It is noteworthy that panoramic images do not report the actual size, while CBCT images enable measurement of the actual size of lesions.

Conclusion

The prevalence of idiopathic osteosclerosis of the jaws on CBCT images of a group of Iranian population was estimated to be 8.33%. The lesions were more common in the mandible and in the molar region with no relation to the teeth and most of them were round in shape.

Acknowledgement

None.

Conflict of Interest

None. ■

References

1. Bsoul SA, Alborz S, Terezhalmay GT, Moore WS. Idiopathic osteosclerosis (enostosis, dense bone islands, focal periapical osteopetrosis). *Quintessence Int.* 2004;35:590–591.
2. Sukovic P. Cone beam computed tomography in craniofacial imaging. *Orthod Craniofac Res.* 2003;6:31–36.
3. Solanki J, Jain R, Singh R, Gupta S, Arya A, Tomar D. Prevalence of osteosclerosis among patients visiting dental institute in rural area of Western India. *J Clin Diagn Res.* 2015;9:ZC38–ZC40.
4. White S, Pharoah M. *Oral radiology principles and interpretation.* Canada, Mosby, 2014: 696.
5. Wood N, Gaoz P. *Differential diagnosis of oral and maxillofacial lesions.* 5 ed. USA, Mosby, 1997:460–462.
6. Moshfeghi M, Azimi F, Anvari M. Radiologic assessment and frequency of idiopathic osteosclerosis of jawbones: an interpopulation comparison. *Acta Radiol.* 2014;55:1239–1244.
7. Farhadi F, Ruhani M, Zarandi A. Frequency and pattern of idiopathic osteosclerosis and condensing osteitis lesions in panoramic radiography of Iranian patients. *Dent Res J (Isfahan).* 2016;13:322–326.
8. Chia-Hui C, Chien-Kuo W, Li-Min L, Yao-Der H, Geist JR, Yuk-Kwan C. Retrospective comparison of the frequency, distribution, and radiographic features of osteosclerosis of the jaws between Taiwanese and American cohorts using cone-beam computed tomography. *Oral Radiol.* 2014;30:53–63.
9. Miloglu O, Yalcin E, Buyukkurt MC, Acemoglu H. The frequency and characteristics of idiopathic osteosclerosis and condensing osteitis lesions in a Turkish patient population. *Med Oral Patol Oral Cir Bucal.* 2009;14:e640–e645.
10. Sisman Y, Ertas ET, Ertas H, Sekerci AE. The frequency and distribution of idiopathic osteosclerosis of the jaw. *Eur J Dent.* 2011;5:409–414.
11. Misirlioglu M, Nalcaci R, Adisen M, Yilmaz S. The evaluation of idiopathic osteosclerosis on panoramic radiographs with an investigation of lesion's relationship with mandibular canal by using cross-sectional cone-beam computed tomography images. *J Oral Maxillofac Radiol* 2013;1:48–54.
12. Naser A, Roshanzamir N. Prevalence of idiopathic osteosclerosis in an Iranian population. *Indian J Dent Res.* 2016;27:544–546.
13. Geist JR, Katz JO. The frequency and distribution of idiopathic osteosclerosis. *Oral Surg Oral Med Oral Pathol.* 1990;69:388–393.
14. Garau V, Deschino A, Piras D, Cotti E. Idiopathic osteosclerosis in jaw bones. Clinical statistic study on a population of Sardinian origin. *Minerva Stomatol.* 2002;51:377–383.
15. Yonetsu K, Yuasa K, Kanda S. Idiopathic osteosclerosis of the jaws: panoramic radiographic and computed tomographic findings. *Oral Surg, Oral Med, Oral Pathol, Oral Radiol, Endod.* 1997;83:517–521.
16. Li N, You M, Wang H, Ren J, Zhao S, Jiang M, Xu L, Liu Y et al. Bone islands of the craniomaxillofacial region. *J Cranio Max Dis.* 2013;2:5–9.

How to cite:

Azizi Z, Mosafery H, Safi Y, Dabirzadeh S, and Vasegh Z. Prevalence of idiopathic osteosclerosis on cone beam computed tomography images. *J Dent Sch.* 2017;35(2):36–39.