

# Revascularization of an Immature Maxillary First Premolar with Necrotic Tissue: A Case Report

Behnam Rahbani Nobar<sup>a</sup>, Nazila Akbarian Rad<sup>a</sup>, Sajede Ghorbanzade<sup>b</sup>, Fatemeh Ghorbanzade<sup>c</sup>

<sup>a</sup> Dept. of Endodontics, School of Dentistry, Shahid Beheshti University of Medical Sciences, Tehran, Iran.

<sup>b</sup> Dept. of Endodontics, Dental School, Birjand University of Medical Sciences, Birjand, Iran.

<sup>c</sup> Dental School, Birjand University of Medical Sciences, Birjand, Iran.

Correspondence to Nazila Akbarian Rad (e-mail: nazilakbarian@gmail.com).

(Submitted: 9 April 2018– Revised version received: 21 April 2018– Accepted: 25 April 2018– Published online: Winter 2018)

**Objectives** The purpose of this study was to present a case of regenerative endodontic procedure.

**Case** The maxillary 1<sup>st</sup> premolar of a 9-year-old patient was diagnosed as necrotic. Since the tooth was immature, we decided to treat this tooth with regenerative endodontic procedure. After disinfection of the canal, bleeding was induced by lacerating the peri-apical tissues and a blood clot was formed. Orifice was sealed by MTA and the tooth was restored. 6-months and 1-year follow-ups showed increased root thickness and closure of the apical.

**Conclusion** It can be concluded that the regenerative endodontic procedure used in this study was successful since there was an evident development in root width.

**Keywords** : Dental Pulp, Necrosis, Regeneration, Endodontics

## Introduction

The pulps of young permanent teeth are at risk of breakdown after traumatic injuries, dental caries, and restorative dentistry. Premature loss of a functioning pulp results in a fragile tooth with a compromised crown-to-root ratio, thin dentin walls, and a wide and often apically diverging root that presents significant endodontic and restorative challenges.<sup>1</sup> Frank advocated the use of Ca(OH)<sub>2</sub> to stimulate apexification.<sup>2</sup> Despite this technique's success, it has been indicated by Andreasen et al. that long-term calcium hydroxide as a root canal dressing weakens the root structure and may increase root fracture risk.<sup>3</sup> Use of an artificial apical barrier was an alternative for apexification procedure. This technique allowed immediate obturation of the canal.<sup>4</sup> MTA as an apical barrier was first introduced in 1996.<sup>5</sup> It has been indicated that MTA apical barrier technique is a successful method for obturating teeth with pulp necrosis and immature apices.<sup>6</sup> Nevertheless, none of the techniques mentioned above can induce root development.

Recently regenerative endodontic treatment has been introduced as biologically based procedures designed to replace damaged structures such as dentin, root structures, and cells of the pulp-dentin complex.<sup>7</sup> Regenerative endodontic protocols result in continued root maturation which means the teeth and root are not as inherently weak and susceptible to fracture as the traditional techniques of Ca(OH)<sub>2</sub> apexification and MTA barrier placements. Studies which have compared REPs with the traditional approaches of calcium hydroxide apexification and MTA apical barrier techniques have shown comparable outcomes.<sup>8-10</sup>

In the past the possibility of regeneration and regaining vitality was thought to be low because of the infection caused by bacterial contamination.<sup>11, 12</sup> Thus the most important factor for promoting pulpal regeneration is to properly disinfect the root canal system.<sup>13, 14</sup> Several techniques and methods have been advocated to reach this

goal: Using NaOCl alone or NaOCl in combination with chlorhexidine or hydrogen peroxide as irrigation agent to chemically disinfect the root canal space, placing triple antibiotic mixture (metronidazole, ciprofloxacin and minocycline) or calcium hydroxide as an intracanal medicament between the first and second visits.<sup>15-19</sup> If there are no signs of inflammation in the following visits, the intracanal medicament will be removed. The next step is to create a blood clot in the root canal system and seal the canal by placing MTA on the blood clot. Blood clot is formed by induced bleeding caused by irritating the periradicular tissue.<sup>19</sup> Successful outcome have been reported for the approach mentioned above.<sup>16, 20</sup> The present report describes treatment of an immature, necrotic, permanent maxillary 2<sup>nd</sup> premolar with apical periodontitis by using regenerative endodontic therapy.

## Case Report

In 2016 a healthy 9-year-old patient was referred to the Endodontic Department of the Dental School, Shahid Beheshti University of Medical Sciences. The patient had no remarkable medical history. Pain on chewing at the right side of the maxilla in the past two weeks was reported as chief complaint by the patient. Clinical and radiographic examination showed extensive caries of tooth #5 and amalgam filling of tooth #3 (Fig 1 and 2). Overall the patient's oral hygiene was good. Since there was extensive caries on tooth #5 it was assumed that this tooth might be the reason for patient's pain. The patient reported that the tooth in question only had pain on chewing. There was no facial asymmetry, no swelling and there was no enlargement of cervical and submandibular nodes present. No swelling and no sinus tracts were found relating to tooth #5. The tooth had normal mobility and periodontal pocket depth. Cold test by cold spray (Endo Frost, Roeko, Langenau, Germany) did not induce any response, while the response of teeth #4 and #28 to these tests were normal. Also the tooth was sensitive to percussion. Radiographic

examination showed periapical radiolucency and PDL widening of tooth #5 (Fig 2).

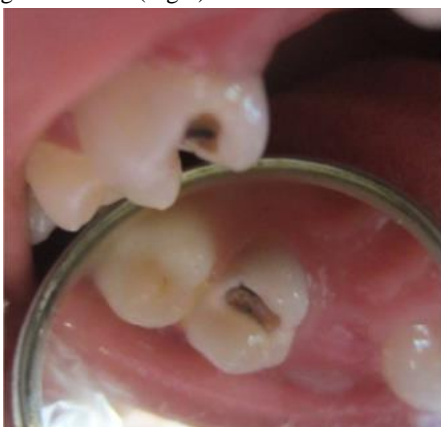

Figure 1- Clinical view of the tooth

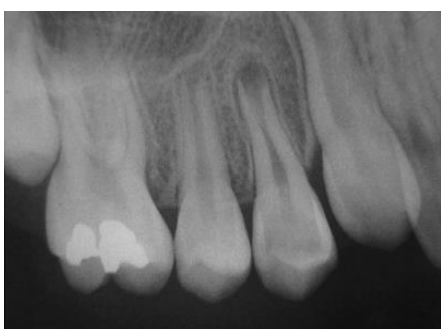

Figure 2- Initial radiograph of the tooth

It also showed that tooth #5 has an immature apex. Based on the results of clinical and radiographic examination, the pretreatment diagnosis for tooth #5 was pulp necrosis with symptomatic apical periodontitis. Considering the stage of root development and its wide open apex, the optimal treatment plan was regenerative endodontic therapy. Treatment plan was explained to the patient and her parents, and then a written consent was acquired. After local anesthesia by 2% Lidocaine with 1/80000 epinephrine (Persocaine-E, Darou pakhsh Co, Tehran, Iran) and rubber dam isolation, the access cavity was prepared with fissure diamond bur (Tizkavan, Tehran, Iran). Root canals were minimally instrumented and gently irrigated with 20ml of NaOCL 1.5% throughout the process of canal preparation (not used once) followed by 20 ml of normal saline. Canals were dried with paper points. Using lentulo-spiral, aqueous mixture of triple antibiotics containing equal portions (by weight) of metronidazole (Pars Daru, Tehran, Iran), ciprofloxacin (Amin Daru, Tehran, Iran) and clindamycin (Pars Daru, Tehran, Iran) at the concentration of 1.0 mg/ml was placed in the canals. The access cavity was sealed with coltosol (Ariadent, Tehran, Iran) and the patient was asked to come back three weeks later. The tooth was asymptomatic at the 2<sup>nd</sup> visit. 3% mepivacaine without vasoconstrictor (Darou Pakhsh, Tehran, Iran) was used as local anesthesia to facilitate the ability to trigger bleeding into the canal system. Then the tooth was isolated with rubber dam and the temporary restoration was removed. Antibiotic paste was removed by gentle filing and irrigation

with 20ml of 17% EDTA (Sina Teb, Tehran, Iran). Then the canals were dried with paper points. A pre-curved size #25 k-file was extended beyond root apex and rotated to lacerate the periradicular tissue and induce bleeding. The bleeding was controlled up to 4mm from the CEJ. MTA was prepared by mixing MTA powder (MTA-Angelus, Londrina, PR, Brazil) and distilled water according to manufacturer's instructions. Roughly 4mm of white MTA was placed in the coronal third of the canal by MTA carrier (Medesy, Maniago, Italy) and condensed using paper points. The access cavity was rinsed with saline and then a wet cotton pellet was placed inside access cavity. Access cavity was sealed with glass ionomer (GC Fuji II, GC Corp, Japan) and patient was then referred to restorative department for composite filling of this tooth (Fig 3A). The patient came back for 6 months and 12 months follow-ups. The tooth was asymptomatic and functional at follow-up visits. Radiographs were taken (Fig 3B and 3C). Apical lesion had almost resolved at the 6-months visit. At the 12-months follow-up there was an increase in root thickness and an apical barrier has been established at the root apex.

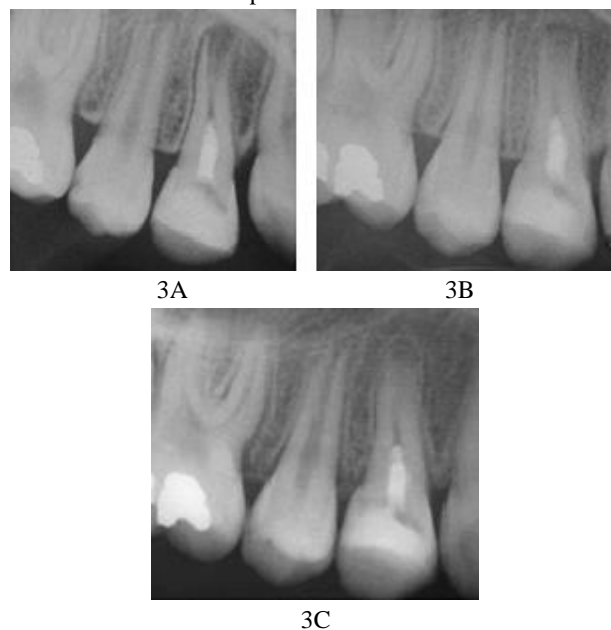


Fig 3- A: Post-regenerative endodontic procedure radiograph, B: 6 months follow-up, C: 12 months follow-up

## Discussion

Based on the results of the present study, hydroalcoholic extract of aloe vera had antibacterial activity against cariogenic bacteria especially *S. mutans*, and with an increase in its concentration and duration of exposure, its efficacy increased; however, its effect was significantly lower than that of 0.2% CHX mouthwash.

## Conclusion

It can be concluded that the regenerative endodontic procedure used in this study was successful since there was

an evident development in root width and establishment of an apical barrier.

### Conflict of Interests

None Declared ■

### Acknowledgement

The authors deny any conflicts of interest related to this study.

### References

- Hargreaves KM, Berman LH, Rotstein I. *Cohen's Pathways of the Pulp*. Elsevier: St.Louis: The C.V.Mosby Co. 2015; Chap 24: 27-28.
- Frank AL. Therapy for the divergent pulpless tooth by continued apical formation. *J Am Dent Assoc* 1966 Jan;72(1):87-93.
- Andreasen JO, Farik B, Munksgaard EC. Long-term calcium hydroxide as a root canal dressing may increase risk of root fracture. *Dent Traumatol* 2002 Jun;18(3):134-7.
- Schumacher JW, Rutledge RE. An alternative to apexification. *J Endod*. 1993;19(10):529-31.
- Tittle KWF FJ, Linkhardt M, Torabinejad M. Apical closure induction using bone growth factors and mineral trioxide aggregate. *J Endod* 1996;22(4):198.
- Holden DT, Schwartz SA, Kirkpatrick TC, Schindler WG. Clinical outcomes of artificial root-end barriers with mineral trioxide aggregate in teeth with immature apices. *J Endod* 2008 Jul;34(7):812-7.
- Murray PE, Garcia-Godoy F, Hargreaves KM. Regenerative endodontics: a review of current status and a call for action. *J Endod* 2007 Apr;33(4):377-90.
- Alobaid AS, Cortes LM, Lo J, Nguyen TT, Albert J, Abu-Melha AS, et al. Radiographic and clinical outcomes of the treatment of immature permanent teeth by revascularization or apexification: a pilot retrospective cohort study. *J Endod* 2014 Aug;40(8):1063-70.
- Kahler B, Rossi-Fedele G, Chugal N, Lin LM. An Evidence-based Review of the Efficacy of Treatment Approaches for Immature Permanent Teeth with Pulp Necrosis. *J Endod* 2017 Jul;43(7):1052-7.
- Torabinejad M, Nosrat A, Verma P, Udochukwu O. Regenerative Endodontic Treatment or Mineral Trioxide Aggregate Apical Plug in Teeth with Necrotic Pulps and Open Apices: A Systematic Review and Meta-analysis. *J Endod* 2017 Nov;43(11):1806-20.
- Kling M, Cvek M, Mejare I. Rate and predictability of pulp revascularization in therapeutically reimplanted permanent incisors. *Endod Dent Traumatol* 1986 Jun;2(3):83-9.
- Cvek M, Cleaton-Jones P, Austin J, Lownie J, Kling M, Fatti P. Pulp revascularization in reimplanted immature monkey incisors-predictability and the effect of antibiotic systemic prophylaxis. *Endod Dent Traumatol* 1990 Aug;6(4):157-69.
- Myers WC, Fountain SB. Dental pulp regeneration aided by blood and blood substitutes after experimentally induced periapical infection. *Oral Surg Oral Med Oral Pathol* 1974 Mar;37(3):441-50.
- Cvek M, Cleaton-Jones P, Austin J, Lownie J, Kling M, Fatti P. Effect of topical application of doxycycline on pulp revascularization and periodontal healing in reimplanted monkey incisors. *Endod Dent Traumatol* 1990 Aug;6(4):170-6.
- Thibodeau B, Trope M. Pulp revascularization of a necrotic infected immature permanent tooth: case report and review of the literature. *Pediatr Dent* 2007 Jan-Feb;29(1):47-50.
- Petrino JA, Boda KK, Shambarger S, Bowles WR, McClanahan SB. Challenges in regenerative endodontics: a case series. *J Endod* 2010 Mar;36(3):536-41.
- Cotti E, Mereu M, Lusso D. Regenerative treatment of an immature, traumatized tooth with apical periodontitis: report of a case. *J Endod* 2008 May;34(5):611-6.
- Chueh LH, Ho YC, Kuo TC, Lai WH, Chen YH, Chiang CP. Regenerative endodontic treatment for necrotic immature permanent teeth. *J Endod* 2009 Feb;35(2):160-4.
- Banchs F, Trope M. Revascularization of immature permanent teeth with apical periodontitis: new treatment protocol? *J Endod* 2004 Apr;30(4):196-200.
- Nosrat A, Seifi A, Asgary S. Regenerative endodontic treatment (revascularization) for necrotic immature permanent molars: a review and report of two cases with a new biomaterial. *J Endod* 2011 Apr;37(4):562-7.
- Fouad AF. The microbial challenge to pulp regeneration. *Adv Dent Res* 2011 Jul;23(3):285-9.
- Lin LM, Kahler B. A review of regenerative endodontics: current protocols and future directions. *J Istanbul Univ Fac Dent* 2017 Dec 2;51(3 Suppl 1):S41-s51.
- Shuping GB, Orstavik D, Sigurdsson A, Trope M. Reduction of intracanal bacteria using nickel-titanium rotary instrumentation and various medications. *J Endod* 2000 Dec;26(12):751-5.
- Cohenca N, Heilborn C, Johnson JD, Flores DS, Ito IY, da Silva LA. Apical negative pressure irrigation versus conventional irrigation plus triantibiotic intracanal dressing on root canal disinfection in dog teeth. *Oral Surg Oral Med Oral Pathol Oral Radiol Endod* 2010 Jan;109(1):e42-6.
- Windley W3rd, Teixeira F, Levin L, Sigurdsson A, Trope M. Disinfection of immature teeth with a triple antibiotic paste. *J Endod* 2005 Jun;31(6):439-43.
- Miller EK, Lee JY, Tawil PZ, Teixeira FB, Vann WF Jr. Emerging therapies for the management of traumatized immature permanent incisors. *Pediatr Dent* 2012 Jan-Feb;34(1):66-9.
- Hoshino E, Kurihara-Ando N, Sato I, Uematsu H, Sato M, Kota K, et al. In-vitro antibacterial susceptibility of bacteria taken from infected root dentine to a mixture of ciprofloxacin, metronidazole and minocycline. *Int Endod J* 1996 Mar;29(2):125-30.
- Sato I, Ando-Kurihara N, Kota K, Iwaku M, Hoshino E. Sterilization of infected root-canal dentine by topical application of a mixture of ciprofloxacin, metronidazole and minocycline in situ. *Int Endod J* 1996 Mar;29(2):118-24.
- Wang Q, Lin XJ, Lin ZY, Liu GX, Shan XL. [Expression of vascular endothelial growth factor in dental pulp of immature and mature permanent teeth in human]. *Shanghai kou qiang yi xue = Shanghai Kou Qiang Yi Xue* 2007 Jun;16(3):285-9.
- Huang GT, Sonoyama W, Liu Y, Liu H, Wang S, Shi S. The hidden treasure in apical papilla: the potential role in pulp/dentin regeneration and bioroot engineering. *J Endod* 2008 Jun;34(6):645-51.
- Tselnik M, Baumgartner JC, Marshall JG. Bacterial leakage with mineral trioxide aggregate or a resin-modified glass ionomer used as a coronal barrier. *J Endod* 2004 Nov;30(11):782-4.
- Reynolds K, Johnson JD, Cohenca N. Pulp revascularization of necrotic bilateral bicuspid using a modified novel technique to eliminate potential coronal discoloration: a case report. *Int Endod J* 2009 Jan;42(1):84-92.
- Chen MY, Chen KL, Chen CA, Tayebaty F, Rosenberg PA, Lin LM. Responses of immature permanent teeth with infected necrotic pulp tissue and apical periodontitis/abscess to revascularization procedures. *Int Endod J* 2012 Mar;45(3):294-305.

34. Torabinejad M, Faras H. A clinical and histological report of a tooth with an open apex treated with regenerative endodontics using platelet-rich plasma. *J Endod* 2012 Jun;38(6):864-8.
35. Neha K, Kansal R, Garg P, Joshi R, Garg D, Grover HS. Management of immature teeth by dentin-pulp regeneration: a recent approach. *Med Oral Patol Oral Cir Bucal* 2011 Nov;16(7):e997-1004.
36. Iwaya SI, Ikawa M, Kubota M. Revascularization of an immature permanent tooth with apical periodontitis and sinus tract. *Dent Traumatol* 2001 Aug;17(4):185-7.
37. Huang GT. A paradigm shift in endodontic management of immature teeth: conservation of stem cells for regeneration. *J Dent* 2008 Jun;36(6):379-86.
38. Chueh LH, Huang GT. Immature teeth with periradicular periodontitis or abscess undergoing apexogenesis: a paradigm shift. *J Endod* 2006 Dec;32(12):1205-13.
39. Jung IY, Lee SJ, Hargreaves KM. Biologically based treatment of immature permanent teeth with pulpal necrosis: a case series. *J Endod* 2008 Jul;34(7):876-87.
40. Shah N, Logani A, Bhaskar U, Aggarwal V. Efficacy of revascularization to induce apexification/apexogenesis in infected, nonvital, immature teeth: a pilot clinical study. *J Endod*. 2008 Aug;34(8):919-25; Discussion 1157.

---

**How to cite:**

Behnam Rahbani Nobar, Nazila Akbarian Rad, Sajede Ghorbanzade, Fatemeh Ghorbanzadeh. Revascularization of an Immature Maxillary First Premolar with Necrotic Tissue: A Case Report. *J Dent Sch* 2018; 36(1):38-41.