

# Dental Management of a Patient with Amelogenesis Skeletal Class III Multidisciplinary Malocclusion & Anterior Open bite; A Case Report

Azita Tehrani<sup>a</sup>, Hossein Behnia<sup>b</sup>, Kaveh Seyedan<sup>c</sup>, Ramyar Rezvan<sup>d</sup>, Zahra Tehrani<sup>e</sup>

<sup>a</sup>Dept. of Orthodontics, Dentofacial Deformities Research Center, Dental Research Institute, Dental School, Shahid Beheshti University of Medical Sciences, Tehran, Iran.

<sup>b</sup>Dept. of Oral and Maxillofacial Surgery, Dentofacial Deformities Research Center, Dental Research Institute, Dental School, Shahid Beheshti University of Medical Sciences, Tehran, Iran.

<sup>c</sup>Dept. Of Prosthodontics, Dental School, Shahid Beheshti University of Medical Sciences, Tehran, Iran.

<sup>d</sup>Orthodontist, Tehran, Iran.

<sup>e</sup>Post-graduate Student, Dept. of Orthodontics, Dental School, Shahid Beheshti University of Medical Sciences, Tehran, Iran.

Correspondence to Zahra Tehrani (e-mail: dr.z.tehrani.sbmu@gmail.com).

(Submitted: 12 May 2018– Revised version received: 10 July 2018– Accepted: 11 July 2018– Published online: Spring 2018)

**Objectives** Amelogenesis imperfecta (AI) comprises a clinically and genetically heterogeneous group of conditions that affects the dental enamel, occasionally in conjunction with other dental, oral, and extra oral tissues. The purpose of this case report was to describe the necessity of the multidisciplinary approaches taken to treat a young patient diagnosed with hypocalcified-type of amelogenesis imperfecta along with skeletal class III jaws relationship and anterior open bite.

**Case** A 19 year-old female was presented to the department of orthodontics, School of Dentistry at Shahid Beheshti University of Medical Sciences (Tehran, IRAN) with the chief complaints of dental sensitivity to hot and cold, teeth discoloration leading to esthetic concerns. On examination the patient was confirmed as skeletal CL III with a long face syndrome and severe anterior open bite. The patient reported difficulty with mastication and poor self-image due to teeth appearance. Interdisciplinary team approach was proposed in a three phase treatment plan: pre-surgical treatment, surgical treatment, postsurgical treatment. This approach enabled the team to successfully improve the patient's facial profile, resolve malocclusion, and normalize the aesthetic.

**Conclusion** This case management revealed the importance of having a coordinated team approach consist of orthodontist, oral surgeon, and prosthodontist as a necessary key to a successful treatment. This approach is essential for successful management of structural, aesthetic, and functional issues as well as an achievement of high patient's satisfaction.

**Keywords** : Amelogenesis Imperfecta, Angle class III, Orthognathic surgery, Orthodontics, Prosthodontics

## Introduction

Amelogenesis Imperfecta (AI) is the expression of a heterogeneous inherited enamel disorder associated with mutations in many genes encoding enamel proteins such as amelogenin, enamelin, enamelysin, KLK4, WDR72, and FAM83H.<sup>1-2</sup> This genetic expression affects the quantity and quality of the enamel in both primary and permanent dentition, with a variable prevalence from 1/700 to 1/14,000.<sup>1-4</sup>

AI may be inherited in an X- linked manner or by autosomal dominant, autosomal recessive, or sporadic inheritance patterns. The most common type of AI occurs as a result of the autosomal dominant form of transmittance. This anomaly exists mostly independent of any related systemic diseases. There is various classification systems proposed for the different types of AI. On the basis of clinical and radiographic finding, AI is classified into three types: Hypoplastic, Hypomineralization, and Hypomaturation.<sup>5</sup>

In patients with AI, craniofacial features such as constricted maxillary arch, reversed mandibular curve of Spee, and anterior and posterior open bite occlusions may be presented. In addition, these patients may face feeding

problems due to dental sensitivity and loss of occlusal vertical dimension caused by severe and early widespread attrition.<sup>6, 7</sup> Management of complex AI cases with severe malocclusion is a major challenge for clinicians and usually requires an interdisciplinary approach.<sup>8, 9</sup>

The purpose of this case report is to explain the importance of a multidisciplinary approach taken to treat the patient diagnosed with hypo mineralized AI with skeletal CI III malocclusion and openbite.

## Case Report

A 19 year-old female case was presented to the department of orthodontics, School of dentistry at Shahid Beheshti University of Medical Sciences (Tehran, IRAN) with the chief complaints of dental sensitivity to hot and cold, discolored teeth, and facial esthetic concerns. Patient had a long face syndrome and suffered from a noticeable anterior open bite. She reported difficulty with mastication and poor self-image resulted from the teeth appearance. No remarkable findings were identified in her medical record. There was no evidence of systemic disease, nutritional deficiency, or drug treatments that could have affected dental structures during development. According to her

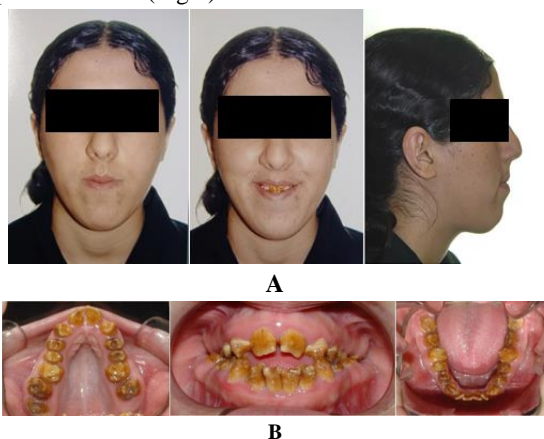
parents, none of her first-degree family members (mother, father, sister) had the same dental problems.

Clinical examination confirmed skeletal class III malocclusion with Para-nasal and maxillary deficiency, a 4 mm anterior open bite, and incompetent lips at rest (Fig 1).

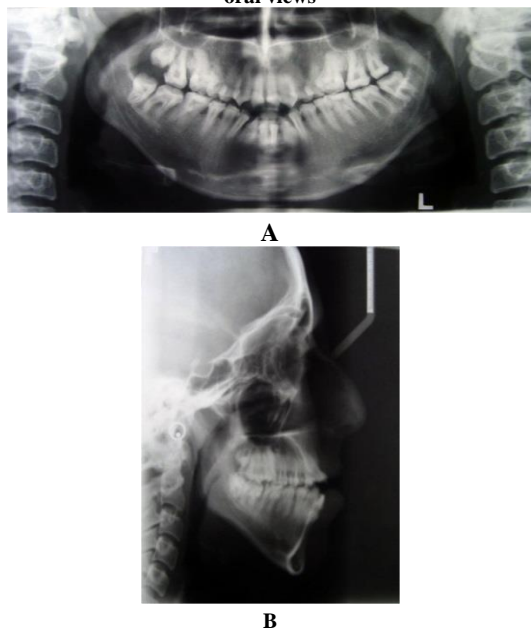
Followings are more clinical details of the case:

1. Increased Lower Anterior Face Height (LAFH)
2. Chin deficiency
3. Maxillary constriction
4. Anterior and posterior cross bite
5. Upper lateral incisors' missing
6. Dental wear and enamel dysplasia on all upper and lower teeth

Panoramic radiographic view revealed reduced enamel thickness, lack of distinction in density between enamel and dentin. Pulp chambers were noted within normal shape and no pathologic calcification. Careful clinical and radiographic evaluation of the case confirmed it as a case of hypocalcified AI (Fig 2).



**Figure 1- Pre-treatment appearance of the patient with hypocalcified-type amelogenesis imperfecta and Skeletal class III relationship with anterior open bite. A: Extra oral view B: Intra-oral views**



**Figure 2- Pretreatment panoramic A: Panoramic radiograph B: Lateral cephalogram view**

Detailed radiographic (lateral cephalogram) findings of the case are described below:

1. Maxillary deficiency
2. Increased mandibular plane angle
3. Mandibular prognathism

Based on the clinical and lateral cephalometric analysis findings, patient was classified as a typical class III skeletal Malocclusion (wits' appraisal=-3). These findings were further related to two main sources of cause for skeletal class III malocclusion: a- Maxillary deficiency and b- mandibular prognathism. Patient was also presented with a vertical growth pattern. Patient vertical measurement details are enumerated in Table 1.

**Table 1-** Cephalometric analysis of the patient before and after treatment

Measurement	Normal value	Value pretreatment	Value Post treatment
SNA	80-84	75	78
SNB	76-80	72	73
ANB	2-4	3	5
SN-POG	34±5.5	74	75
P-A Face height (S-GO/N-Me)	62-65%	55.8	60
Wits	-1	-3	-0.05
U-1 to SN	102±2	101	99.8
L1-MeGo	90±3	89	90
U1-L1	135	118	115
U1-Pal	110	115	115.2

Treatment objectives were aimed at reducing the tooth sensitivity, attaining ideal functional occlusion, and improving aesthetic with a well-planned orthogenetic surgery intervention.

An interdisciplinary team consisted of an oral and maxillofacial surgeon, an orthodontist, and a prosthodontist were asked to participate in this treatment approach in order to meet mentioned objectives. The team members jointly evaluated the case and a discussion panel was set for best treatment planning and ultimate restorative requirements.

The diagnostic procedure indicated an initial maxillary corrective skeletal maxillary expansion followed with full mouth orthodontic treatment in order to correct the skeletal imbalance. The proposed surgical-orthodontic management was then followed by complete dental rehabilitation using metal-ceramic crowns in order to achieve a stabilized result which included improve meat of tooth form, color and occlusion. The interdisciplinary team proposed a 3 phase treatment plan: Pre-surgical treatment, surgical treatment, postsurgical treatment. It was believed that this treatment plan would provide sufficient aesthetic changes desired for patient while it would improve the patient's convex facial profile and malocclusion. Patient was informed of the procedure details and the overall treatment plan, its objectives, and possible complications. The importance of oral hygiene, caries control was emphasized along with the need for full cooperation during and after the treatment. Patient was requested to sign an informed consent form prior to any attempt for treatment.

### Pre-surgical treatment

Azita Tehranchi, et al.

The initial dietary counseling and oral hygiene instructions were performed during the first dental session. At the first step, temporary metal crowns were cemented on premolars and molars of both jaws. The main purpose of using these crowns was to create the correct vertical height as a guide for planned surgery in addition to protection of dentin/pulp complex. The Hyrax appliance was directly placed on metal crowns of first premolars and first molars of the maxilla. Orthodontic brackets were also bonded on metal crowns using Z Prime plus bond (Bisco, USA). The screw was then activated twice daily for 12 days in order to expand maxilla for pre-surgical arch coordination. Although the patient was 19 years old, maxillary suture expanded skeletally confirmed by x-ray. This procedure provided enough space for replacement of missing upper lateral teeth in future prosthodontic repair stage. Pre-surgical orthodontic treatment was carried out to align and level the dentition in both arches and to achieve a better arch coordination prior to surgery within 15 months period (Fig 3 and 4).

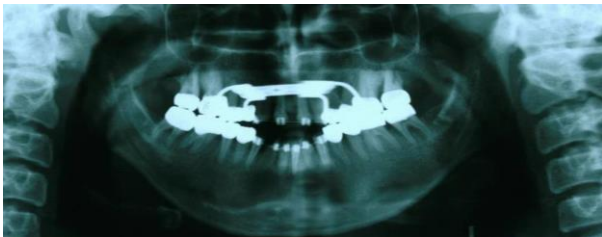


Figure 3- Panoramic view after the active period of hyrax appliance showing some degrees of expansion

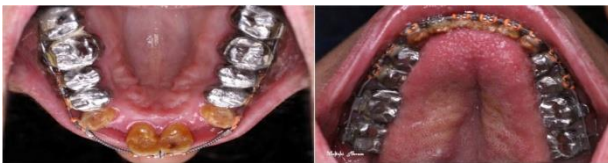

Figure 4- Orthodontic appliance over the metal crowns.

The Hyrax appliance remained passive for 6 months to prevent the potential relapse.

#### Surgical treatment

In order to correct maxillary deficiency and anterior open bite, maxillary advancement and posterior impaction was performed in surgical phase. Orthognathic surgical splints were constructed following the completion of pre-surgical orthodontic procedure. Dolphin software package was used for digital model simulation pre-operatively.

The patient received a Lefort I osteotomy in the upper jaw with impaction in posterior region.(Fig 5)

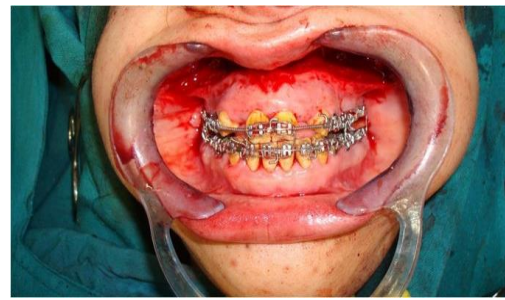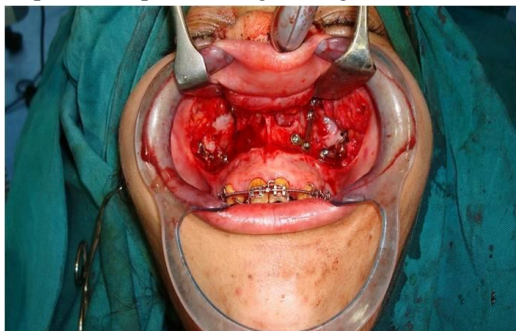


Figure 5-Surgical procedures completed and splints placed.

#### Post-surgical treatment

After the consolidation period, postsurgical orthodontic treatment was processed on old metal crowns for 3 months. During the retention phase of treatment, high pull headgear with maxillary splint was used as a retainer.

Following orthodontic treatment completion, the prosthodontic treatment was initiated. With regard to the final restorations, the metal crowns were replaced with appropriately prepared standard metal-ceramic crowns (Fig 6).

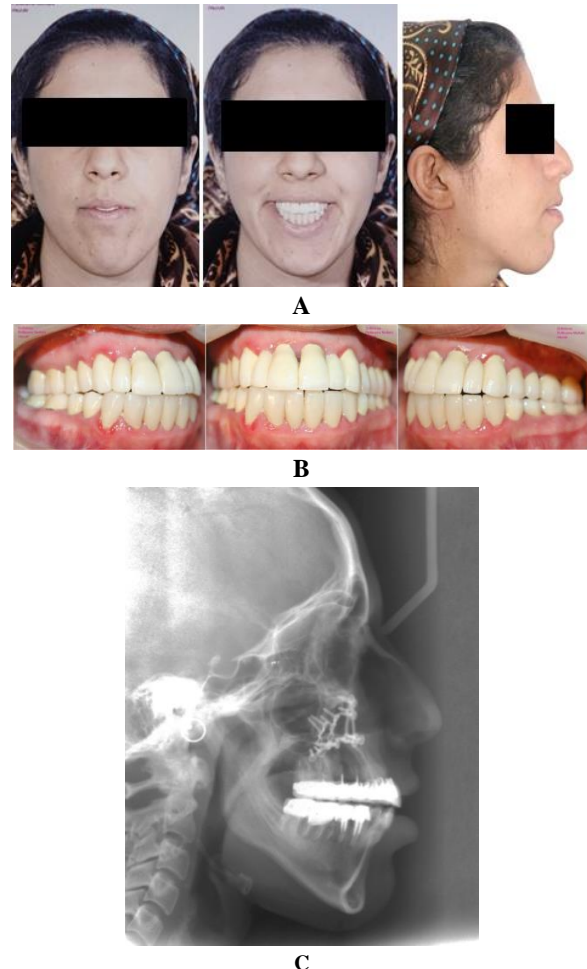


Figure 6- Post treatment appearance of the patient A: Extra oral view B: Intra-oral view C: Lateral cephalogram ic view

#### Discussion

A three phase treatment plan proposed and performed by the interdisciplinary team approach provided an aesthetic



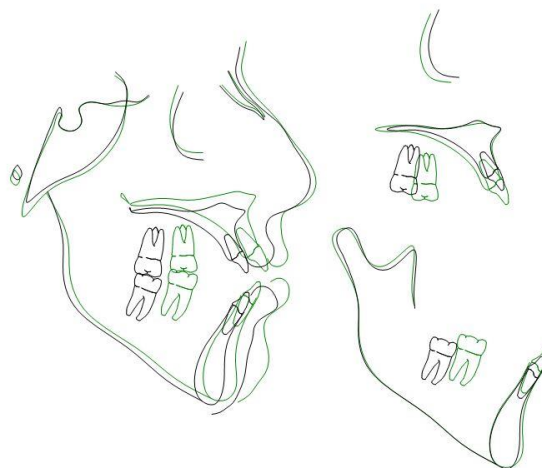
change, an improved patient's convex facial profile and corrected occlusion. Adequate treatment knowledge and expertise are required in order to be able to properly manage patients with AI including the team approach strategy<sup>10</sup>. The interdisciplinary approach is essential for successful management of structure, aesthetic, and functional issues.

The pre surgical Phase involves placement of constructed metal crowns as temporary prostheses to create the immediate correct vertical dimension as a guide to surgical intervention while protecting the dentin/pulp complex. This step was also used for orthodontic brace placement prior to surgery.

In complicated occlusion, a wax-up step may be performed prior to orthognathic surgery in order to help estimating the desired changes. This enables the placement of interim prostheses prior to and during the surgery for proper intra-operative jaw positioning.<sup>11</sup>

In surgical phase of this case, the team was able to correct maxillary deficiency as well as anterior open bite following the use of the computerized digital model simulation provided. The differential posterior impaction was performed using the Le Fort I osteotomized maxilla for rotation of the maxillary occlusal plane around the transverse axis with differential posterior impaction that permits forward auto rotation of the mandible to close the anterior open bite of the patient. Orthodontic intervention required an element of proclination of the maxillary incisors which were retroclined as the effect of surgical posterior impaction.<sup>12</sup> Pre and post treatment superimposition view has been shown in figure 7.

Postsurgical orthodontic treatment and prosthodontic treatment were responsible for most corrective changes visible in line with the esthetic and facial attractiveness. Complete crown coverage is commonly recommended for the definitive restorative procedure in most severe hypocalcified AI cases.<sup>1</sup> Even though significant reduction of tooth structure is required, such restorations protect the remaining dental tissues from further destruction of brittle enamel structure. Adequate tooth preparation and appropriate choice of restorative materials are essential to limit biological complications including the loss of pulp vitality and long-term crown restoration problems.



**Figure 7- Pre & post treatment superimposition view**

Although resin composite veneer is considered as one of the best ways to preserve tooth structure since it requires minimal preparation but evidence suggest that bonding between a resin composite and enamel is not reliably efficient, AI patients with poorly mineralized and friable enamel.<sup>5</sup>

## Conclusion

A team approach was adopted to treat a patient with Amelogenesis Imperfecta who had severe skeletal CI III and open bite discrepancies. A fully coordinated team work provides the necessary treatment steps including ortho-surgical intervention with maximum efficiency. Final prosthodontic rehabilitation fulfilled the successful management of structural, aesthetic, and functional issues of this complicated AI patient.

## Conflict of Interests

None Declared ■

## References

1. Millet C, Duprez JP, Khoury C, Morgon L, Richard B. Interdisciplinary Care for a Patient with Amelogenesis Imperfecta: A Clinical Report. *J Prosthodont* 2015 Jul;24(5):424-31.
2. Chan HC, Estrella NM, Milkovich RN, Kim JW, Simmer JP, Hu JC. Target gene analyses of 39 amelogenesisimperfectakindreds. *Eur J Oral Sci* 2011 Dec;119 Suppl 1:311-323.
3. Wright JT, Torain M, Long K, Seow K, Crawford P, Aldred MJ, et al. Amelogenesis imperfecta: genotype-phenotype studies in 71 families. *Cells Tissues Organs* 2011;194(2-4):279-283.
4. Sundell S: Hereditary amelogenesis imperfecta: an epidemiological, genetic and clinical study in a Swedish child population. *Swed Dent J Suppl* 1986;31:1-38.
5. Leevailoj C, Lawanrattanakul S, Mahatumarat K. Amelogenesis Imperfecta: Case Study. *Oper Dent* 2017 Sep-Oct;42(5):457-469.
6. Hoppenreijts TJ, Freihofer HP, Stoeltinga PJ, Tuinzing DB, van't Hof MA, van der Linden FP, et al. Skeletal and dento-alveolar stability of Le Fort I intrusion osteotomies and bimaxillary osteotomies in anterior open bite deformities. A retrospective three-centre study. *Int J Oral Maxillofac Surg* 1997 Jun;26(3):161-175.

Azita Tehranchi, et al.

7. Persson M, Sundell S. Facial morphology and open bite deformity in amelogenesis imperfecta. A roentgenocephalometric study. *Acta Odontol Scand* 1982;40(3):135-144.
8. Gisler V, Enkling N, Zix J, Kim K, Kellerhoff NM, Mericske-Stern R. A multidisciplinary approach to the functional and esthetic rehabilitation of amelogenesis imperfecta and open bite deformity: a case report. *J Esthet Restor Dent* 2010 Oct;22(5):282-293.
9. Wright J, Waite P, Mueninghoff L, Sarver DM. The multidisciplinary approach managing enamel defects. *J Am Dent Assoc* 1991 Feb;122(2):62-65.
10. Markovic D, Petrovic B, Peric T. Case series: clinical findings and oral rehabilitation of patients with amelogenesis imperfecta. *Eur Arch Paediatr Dent* 2010 Aug;11(4):201-8.
11. Kinzer GA. COMMENTARY. A multidisciplinary approach to the functional and esthetic rehabilitation of amelogenesis imperfect and open bite deformity: a case report. *J Esthet Restor Dent* 2010 Oct;22(5):294-296.
12. Pousette Lundgren G, Morling Vestlund GI, Trulsson M, Dahllöf G. A Randomized controlled trial of crown therapy in young individuals with amelogenesis imperfecta. *J Dent Res* 2015 Aug;94(8):1041-7.

---

**How to cite:**

Azita Tehranchi, Hossein Behnia, Kaveh Seyedan, Ramyar Rezvan, Zahra Tehrani The power of Interdisciplinary Approach: A Case Study of a Patient with Amelogenesis Imperfecta Skeletal Class III malocclusion & Anterior Open bite. *J Dent Sch* 2018;36(2): 76-80.