

A Rare Case Report of Duodenal Adenocarcinoma Accompanied by Cerebellar Medulloblastoma

Siamak Afagh¹, Nashtaran Khoshpour², Amirhossein Hosseini³, Farzad Esmaeili Tarki¹, Fatemeh Sadat Rahimi¹, Yalda Nilipour⁴, Mohsen Roozrokh⁵, Naghi Dara³, Negar Imanzadeh⁶, Ali Akbar Sayyari^{7*}

1- Pediatric Gastroenterology, Hepatology and Nutrition Center, Research Institute for Children's Health, Shahid Beheshti University of Medical Sciences, Tehran, Iran.

2- Department of pediatrics, Shahid Beheshti University of Medical Sciences, Tehran, Iran

3- Assistant Professor of Pediatric Gastroenterohepatology, Pediatric Gastroenterology, Hepatology and Nutrition Research Center, Research Institute for Children's Health, Shahid Beheshti University of Medical Sciences, Tehran, Iran.

4- Associated professor of pathology, Pediatric Pathology Research center, research institute for children's health, Shahid Beheshti University of Medical Sciences, Tehran, Iran.

5- Professor of Pediatric Surgery, Pediatric Surgery Research Center, Research Institute for Children Health, Shahid Beheshti University of Medical Sciences, Tehran, Iran.

6- School of Pharmacy, Shahid Beheshti University of Medical Sciences, Tehran, Iran.

7- Professor of Pediatric Gastroenterohepatology, Pediatric Gastroenterology, Hepatology and Nutrition Research Center, Research Institute for Children's Health, Shahid Beheshti University of Medical Sciences, Tehran, Iran.

ARTICLE INFO

Available Online: 16 June, 2020

KEYWORDS

Adenocarcinoma, Duodenal Neoplasm, Radiotherapy

CORRESPONDING AUTHOR

Dr.Amirhossein Hosseini

Assistant professor of Pediatric Gastroenterology, Hepatology and Nutrition, Pediatric Gastroenterology, Hepatology and Nutrition Research Center, Research Institute for Children's Health, Mofid Children Hospital, Mirdamad Avenue, Tehran, Iran. Email: Amir1981hosseini@gmail.com Tel: +989128887347

* Second Correspondin Author, Email: drsayyari@hotmail.com

ABSTRACT

Here is a case of a 6-year-old female with a diagnosis of Duodenal Adenocarcinoma presented by the authors, in which 24 months subsequent to radiation therapy for a Cerebellar Medulloblastomas the mentioned diagnosis has been confirmed. Although the chance of a secondary malignancy has been confirmed to become elevated in children formerly undergone radiation therapy, the incidence of duodenal adenocarcinoma is a highly infrequent condition. As a consideration, observing manifestations like weight loss, vomiting, and icterus in a pediatric patient, who has been administered earlier on with radiation therapy, must alert physicians that the risk of a gastrointestinal malignancy exists.

INTRODUCTION

Medulloblastoma, forming about one fifth of all childhood brain tumors, is considered as the most prevalent brain malignancy in pediatric patients [1]. Medulloblastomas in terms of cell origin are histologically high-grade embryonal tumors, which have been now categorized alongside other embryonal tumors under the classification of primitive neuro-ectodermal tumors (PNET) [2]. Surgical resection preceded and/or followed by radiation and chemotherapy is the mainstay of therapy with a five-year survival rate of 75% [3]. Even though the small intestine is the longest section of Gastrointestinal (GI) tract forming the vastest surface of it, small bowel adenocarcinoma (SBA) is quite infrequent [4] which has an incidence of fifty times smaller than that of colorectal carcinoma [5]. It should be noted that the diagnosis is oftentimes confirmed at an advanced stage because of being poorly noticed by radiologic imaging, since it is hardly accessible endoscopically, it has low suspicion index and late atypic manifestations [6]. These

factors all usually result in a flawed outcome. On account of being a unique GI malignancy, as rare as it is, evidence associated with its optimal management are quite low. The fact that two distinct cancers occur simultaneously in an individual has been formerly reported in the texts, but this unique infrequent phenomenon mostly regards patients in whom two coinciding neoplasms occur simultaneously in the same organ while being histologically distinguished. Here is a report of a 6-year-old case with duodenal adenocarcinoma accompanied by Cerebellar Medulloblastoma.

CASE REPORT

Our patient, a 6-year-old female, has right cerebellar hemisphere Medulloblastomas who has been diagnosed at the age of four. She has undergone cerebellar radiotherapy, chemotherapy and neurosurgery. Soon afterwards, certain sequencing workups were done for the patient to classify the risk of Medulloblastoma, analyzing immunohistochemical markers of



CITE THIS PAPER AS

S.Afagh, N.Khoshpour, Amirhossein Hosseini, Farzad Esmaeili Tarki, Fatemeh Sadat Rahimi, Yalda Nilipour et al. A Rare Case Report of Duodenal Adenocarcinoma Accompanied by Cerebellar Medulloblastoma. *Sch Med Stud J*.2020;2(2):23-26

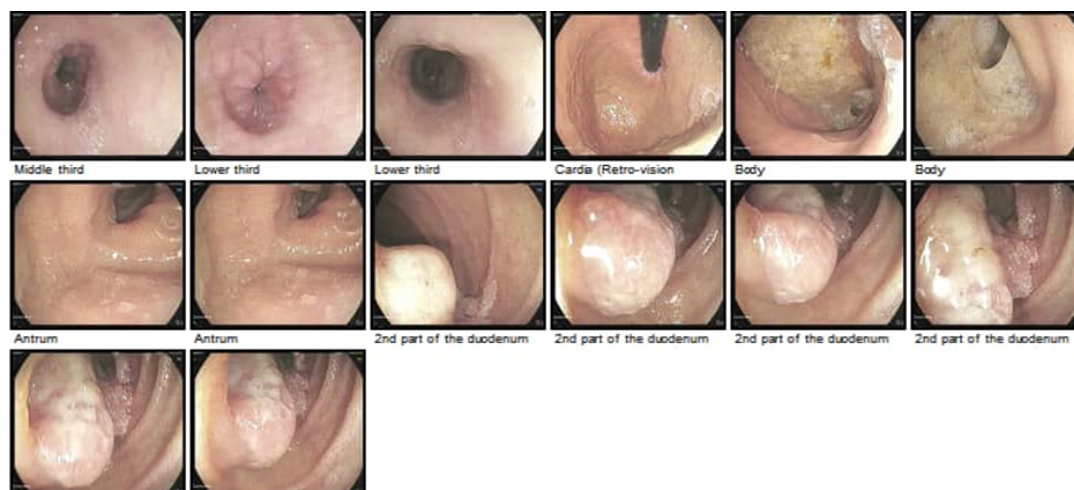


Figure 1. An upper endoscopy of the patient reported the white spotted involvement of esophagus suggesting candidiasis infection. Significant erythematous and erosive parts in the body section of stomach was diagnostic of gastritis. A 1.5 cm non-bleeding polypoid mass existed in the location of sphincter of Oddi. The bile fluid was yet to flow due to previous placement of T-tube.

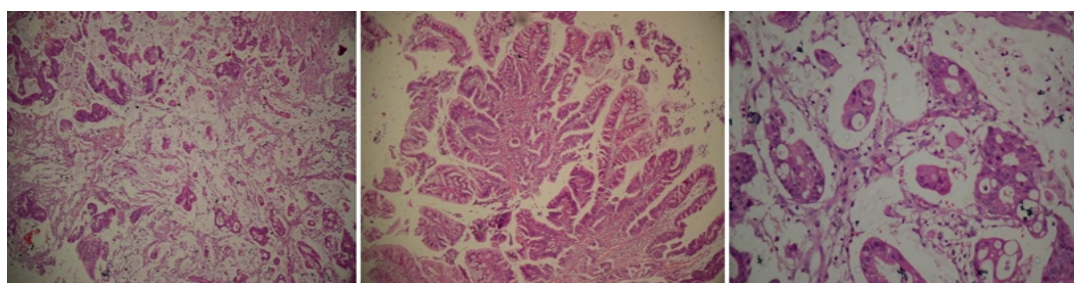


Figure 2. The tissue samples of duodenal adenocarcinoma, undergone hematoxylin and eosin staining, demonstrate poorly-differentiated portions of papillary component arising from covering intestinal mucosa of papilla.

YAP1, GAP1, and P53, which came out with negative results. Approximately nine months after the diagnosis of Medulloblastoma, the patient was referred to the hospital complaining of bone pain in her left arm. With a suspicion to extra neural metastasis of Medulloblastomas, the patient was administered with a bone scan diagnostic procedure, which then the primary diagnosis was confirmed, and chemotherapy, which had been already started before the suspected metastasis, was indeed continued. After two years, the patient referred to the emergency department having complaints of fever, anorexia, nausea, with pale, icteroid resemblance, her physical examination revealed the abdominal pain with the mild localized tenderness in epigastric area. The ultrasonography finding was suggestive of the common bile duct (CBD) obstruction. As a temporary measure, she underwent the surgery of common bile duct dilatation and T-tube insertion. Shortly thereafter, she was admitted again with icterus, dark urine, nausea, vomiting and diarrhea. She was examined with cholangiography, which indicated CBD obstruction and dilatation of intrahepatic and extrahepatic bile ducts (figure.1). In an evaluation by esophagogastroduodenoscopy, a large polyp mass with a size of 1.5 cm was spotted in the sphincter of Oddi. moreover, erythematous areas and erosive lesions were appeared to be present in the stomach suggesting a possible gastritis. A laparotomy surgery was performed on the patient, comprising total resection of distracting hepatopancre-

atic duct mass and the duodenectomy. Numerous biopsies were obtained from the omentum, the mass, and peripheral lymph nodes. The report of pathology indicates mucinous adenocarcinoma arising on villous adenomatous polyp (Figure 2).

DISCUSSION

Being exposed to great dosages of radiation in childhood might elevate the chance of second primary tumors progressing afterwards in life [7], although the survival rate of pediatric patients with primary childhood tumors rise after treatment with radiation therapy, but the possibility to develop secondary malignancies might increase during childhood. Chiefly, respiratory system malignancies and hematologic cancers of leukemia's are among these secondary pediatric cancers [8, 9]. Notably, Small intestinal adenocarcinoma occurs in highly rare situations. In pediatric patients, duodenal cancers represent an even more unusual entity [10] despite the fact that the relative risk of developing intestinal cancer is demonstrated to be notably increased following chemotherapy for non-Hodgkin's lymphoma. The relative risk has been larger in cases who have been younger at the initial therapy [11]. In one case-series study of 429 cases undergone treatment with radiation therapy for pediatric solid tumors, 13 (3%) presented a second malignant neoplasm, of whom only 1 had developed colon malignancy. Furthermore, to the best of our knowledge, there was not any patient reported to

have duodenal adenocarcinoma [12]. Six patients afflicted with intestinal adenocarcinoma were found to be reviewed in the texts as secondary cancerous neoplasms following the therapy for primary tumors. Among these six cases, there was 1 case of Wilms' tumor [13], 2 cases of acute lymphoblastic leukemia [14, 15] and 3 cases of rhabdomyosarcoma [13, 16, 17]. Notwithstanding, none of the mentioned adenocarcinomatous lesions involved the small duodenum. notably, Turcot's syndrome has been also taken into account in this case which is clinically defined when brain cancers and colon malignancies occur in one patient [18]. There are two subtypes to this condition, both involving germ-line inactivating mutations where for type 1 and type 2 the mutations take place in mismatch repair gene and APC gene, respectively. Both types show an autosomal dominant inheritance pattern, whereas type 1 manifests itself mostly in early adulthood [19]. With all mentioned above, it could be understood that our case did not meet either of those two categories requirements for multiple reasons. To list some, the patient was presented at a very young age, she lacked other related characteristics like a positive family history and multiple polyposis, and also other arcane presentations like lupus and skin symptoms were present. Weight loss, vomiting, and indistinct abdominal pain are among the most common clinical manifestations of childhood gastrointestinal carcinoma. These malignancies show particularly poor prognostic features because the onset of their presentation is quite late in life [20]. Keeping that in mind, childhood GI malignancies must be considered in cases with suspicious abdominal complaints who have formerly undergone chemotherapy or radiation therapy for prior pediatric cancers. The crux of a proper management in these cases is to try to recognize the distinguishing clinical and physical features exhibited, even prior to the cancer presenting itself. Therefore, the in-time screening can be noteworthy.

CONCLUSION

In summary, irrespective of the different clarifications, which could be mentioned, we described the bizarre simultaneous occurrence of both a duodenal adenocarcinoma and a cerebellar medulloblastoma. The former malignancy most likely developed while undergoing previous radiotherapy for the medulloblastoma, for the previous 24 months. The main rationale behind which we think of radiation as the most probable causal element for the progression of the brand-new malignancy, is the fact that radiation therapy can explain the development of a secondary cancer in multiple other examples. Additionally, we better bear in mind, that thus far there has not been any evidence of clinical or histological connection between medulloblastoma and adenocarcinoma. Notwithstanding the evidence, the chance of a distinct but unexplained genetic imbalance being responsible for the concomitant development of these two tumors cannot be ignored. Further research especially molecular research is needed to shed light on the matter.

CONSENT

The author in order to publish the present case-report and associated images, written informed consent has been acquired from the parents of affected individual, when being first diagnosed

and also before surgery.

Acknowledgments

None. No funding to declare.

CONFLICT OF INTEREST

The authors declare of no conflict of interest.

REFERENCES

- Rossi A, Caracciolo V, Russo G, Reiss K, Giordano A. Medulloblastoma: from molecular pathology to therapy. *Clin Cancer Res.* 2008;14(4):971-6.
- Vermeulen JF, van Hecke W, Spliet WG, Villacorta Hidalgo J, Fisch P, Broekhuizen R, et al. Pediatric Primitive Neuroectodermal Tumors of the Central Nervous System Differentially Express Granzyme Inhibitors. *PLoS One.* 2016;11(3):e0151465.
- Thomas A, Noël G. Medulloblastoma: optimizing care with a multidisciplinary approach. *J Multidiscip Healthc.* 2019;12:335-47.
- Aparicio T, Zaanan A, Svrcek M, Laurent-Puig P, Carre N, Manfredi S, et al. Small bowel adenocarcinoma: epidemiology, risk factors, diagnosis and treatment. *Dig Liver Dis.* 2014;46(2):97-104.
- Chen EY, Vaccaro GM. Small Bowel Adenocarcinoma. *Clin Colon Rectal Surg.* 2018;31(5):267-77.
- Tian J, Liu J, Guo C, Yang X, Yang Y, Gou H, et al. Prognostic factors and treatment outcomes in patients with non-ampullary small bowel adenocarcinoma: Long-term analysis. *Medicine (Baltimore).* 2019;98(17):e15381.
- Dracham CB, Shankar A, Madan R. Radiation induced secondary malignancies: a review article. *Radiat Oncol J.* 2018;36(2):85-94.
- Ng AK, Kenney LB, Gilbert ES, Travis LB. Secondary malignancies across the age spectrum. *Semin Radiat Oncol.* 2010;20(1):67-78.
- Gibbs IC, Tuamokumo N, Yock TI. Role of radiation therapy in pediatric cancer. *Hematol Oncol Clin North Am.* 2006;20(2):455-70.
- Zhuge Y, Cheung MC, Yang R, Eldick D, Koniaris LG, Sola JE. Pediatric intestinal foregut and small bowel solid tumors: a review of 105 cases. *J Surg Res.* 2009;156(1):95-102.
- Mudie NY, Swerdlow AJ, Higgins CD, Smith P, Qiao Z, Hancock BW, et al. Risk of second malignancy after non-Hodgkin's lymphoma: a British Cohort Study. *J Clin Oncol.* 2006;24(10):1568-74.
- Paulino AC, Fowler BZ. Secondary neoplasms after radiotherapy for a childhood solid tumor. *Pediatr Hematol Oncol.* 2005;22(2):89-101.
- Densmore TL, Langer JC, Molleston JP, Dehner LP, Coffin CM. Colorectal adenocarcinoma as a second malignant neoplasm following Wilms' tumor and rhabdomyosarcoma. *Med Pediatr Oncol.* 1996;27(6):556-60.
- Kimball Dalton VM, Gelber RD, Li F, Donnelly MJ, Tarbell NJ, Sallan SE. Second malignancies in patients treated

for childhood acute lymphoblastic leukemia. *J Clin Oncol.* 1998;16(8):2848-53.

15. Prabakaran S, Senthilnathan SV, Venkatesikal M, Prasad N, Sridharan S. Adenocarcinoma of the colon as a second malignancy in a child. *Pediatric Surgery International.* 2001;17(5):475-7.

16. Park SS, Kim BK, Kim CJ, Kim WS, Kim IO, Park KW, et al. Colorectal adenocarcinoma as a second malignant neoplasm following rhabdomyosarcoma of the urinary bladder: a case report. *J Korean Med Sci.* 2000;15(4):475-7.

17. Kalteis T, Heers G, Elsner R. Adenocarcinoma of the rectum in childhood following chemotherapy and radiotherapy for a rhabdomyosarcoma--a case report. *Eur J Pediatr Surg.* 2005;15(3):210-2.

18. Turcot J, Despres JP, St Pierre F. Malignant tumors of the central nervous system associated with familial polyposis of the colon: report of two cases. *Dis Colon Rectum.* 1959;2:465-8.

19. Hamilton SR, Liu B, Parsons RE, Papadopoulos N, Jen J, Powell SM, et al. The molecular basis of Turcot's syndrome. *N Engl J Med.* 1995;332(13):839-47.

20. Ladd AP, Grosfeld JL. Gastrointestinal tumors in children and adolescents. *Semin Pediatr Surg.* 2006;15(1):37-47.