

Case report

Sudden Cardiac Arrest in COVID-19 Young Patient: a Case ReportNilofar Massoudi¹ , Mahshid Soleimanzadeh^{2*} **Abstract**

Following the outbreak of COVID-19 since December 2019 many reports have been published to conclude different presentations of this new infection. This report contains a summary of a young patient with a history of methadone intake, which experienced a cardiopulmonary arrest while he was preparing to take a lung Computerized Tomography (CT) scan in an outpatient setting. After a successful Cardio-Pulmonary Recovery in the CT scan room he was admitted in Intensive Care Unit. He had a prolonged QTc interval in Electrocardiograph and bilateral pulmonary involvement in Chest X-Ray.

Keywords: COVID-19, Coronavirus, Cardiopulmonary arrest, High QTc interval, Methadone

Please cite this article as: Massoudi N, Soleimanzadeh M. Sudden Cardiac Arrest in COVID-19 Young Patient: a Case Report. J Cell Mol Anesth.2020;5(2):122-4.

1. Clinical Research Development Center, Shahid Modarres Hospital, Department of Anesthesiology, Shahid Beheshti University of Medical Sciences, Tehran, Iran
2. Anesthesiology Research Center, Shahid Beheshti University of Medical Sciences, Tehran, Iran

Corresponding Author:

Mahshid Soleimanzadeh, MD, Resident of Anesthesia, Anesthesiology Research Center, Shahid Beheshti University of Medical Sciences, Tehran, Iran; Tel/Fax: (+98) 21-22360635. Email: mahshid.s1987@gmail.com

Introduction

Coronavirus is a family of viruses that cause illness in a widely variable severity; from the common cold in some patients to a severe pneumonia as in SARS2 and Middle East Respiratory Syndrome (MERS) (1). Since December 2019, an outbreak was reported in China which was caused by a novel coronavirus, later named COVID-19. WHO declared a pandemic by 11 March 2020 (2). After virus documentation and separation, the pathogen intended for this pneumonia was initially named 2019 novel coronavirus (2019-nCoV) (3), nevertheless has consequently been legitimately called severe acute respiratory syndrome coronavirus 2 (SARS-CoV-2) via WHO (4). The problem has many unique and even unknown features that human being has never been faced with (5). COVID-19 mortality rate (MR) and case fatality rate (CFR) depend on some factors; such

as gender, age and underlying disease, etc. According to recent studies, COVID19 associated mortality is significantly higher in males compared to females (6). Here, we report the case of a young man who was awake and conscious but needed CPR a few minutes later; basic and advanced CPR were performed while the patient was on the floor of the CT unit.

Case Report

The current case report was approved by the IRB ethics committee, Research Deputy, SBMU, Tehran, Iran. A 37-year-old man with no significant past medical history with Dry cough, fatigue, myalgia and without fever and coryza, was referred to a medical center, while being recommended to stay home and rest. The patient had no past medical or smoking history, but the history of methadone abuse according to his companion; while denying any recent methadone

intake.

Due to his symptoms, a chest Computerized Tomographic (CT) scanning was ordered. When entering the CT unit in the radiology department, he suddenly fell down on the ground, mandating prompt call for Cardio-Pulmonary Resuscitation (CPR) which was started immediately with chest compression, while he had fallen on the ground, had no breathing, no distal or carotid pulses and also was unconscious and pale. Using direct laryngoscopy, he was intubated by No. 8 cuffed endotracheal tube. Rescue breaths were given using bag mask ventilation with a frequency of 10/minute. Then, the first doses of epinephrine were injected into the endotracheal tube; while chest compression was continued. Intravenous access was taken meanwhile without any pause in chest compression; every 3-5 min 1 mg of intravenous epinephrine was repeated. The latter steps were done while the patient was on the ground; since there was no opportunity to move him off the ground and the health care personnel had their standard personal protection equipments.

After 25 minutes of CPR, weak central pulses were detected, with a sinus bradycardia rhythm. When the patient's condition became a bit more stable, he was moved to the intensive care unit (ICU); where, clinical signs including fever (38 degrees centigrade), tachycardia and consciousness were still persistent. In electrocardiogram, prolonged QT interval had been found (Figure 1).

Both lungs in auscultation had diffused rales; compatible with CT scan imaging; revealing moderate

global cardiomegaly, associated with mild to moderate

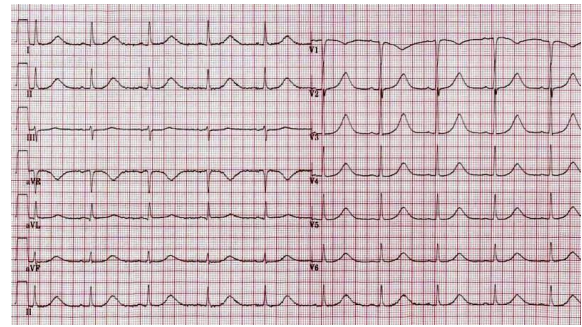


Figure 1. Long QT Pattern in EKG.

pleural effusion, more prominent on the right side as well as mild diffused ground glass opacities prominently in the Right Lower Lobe (RLL). In addition, patchy air space and ground glass opacities were found throughout both lung fields, most prominently in the central regions of RLL (Figure 2).

Discussion

Sudden cardiopulmonary arrest of this patient, who was managed in situations much different from standard care could be linked to COVID-19 induced myocardial damage. Studies have demonstrated that the Middle East respiratory syndrome-related coronavirus (MERS-CoV) can be the etiology of acute myocarditis and heart failure (7). SARS-CoV-2 and MERS-CoV have many pathologic and clinical features in common, and the myocardial injury

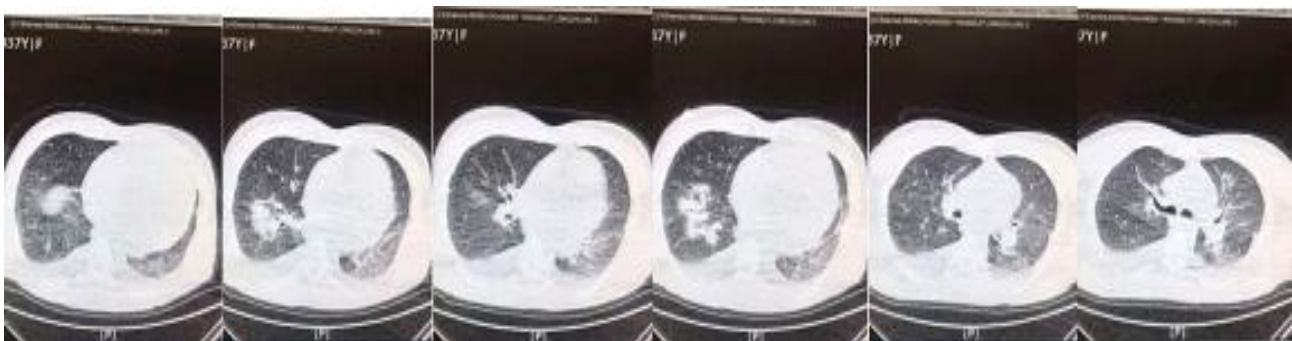


Figure 2. CT scan mild diffused ground glass opacities more prominently in RLL. Patchy air space and ground glass opacities both lung fields.

triggered by both of these infections would undoubtedly surge the strain and intricacy of patient management. Myocardial damage as a concomitant finding in SARS-CoV-2 infection has been reported in 5 of the first 41 patients identified with COVID-19 in Wuhan, China; which was associated with a significant rise in cardiac troponin I (hs-cTnI) levels (>28 pg./ml) (7).

Arrhythmias have been reported as COVID-19 cardiovascular manifestations (8, 9); although a specific arrhythmia has not been described as the hallmark of COVID-19 yet (8). Prolonged QTc interval-induced arrhythmia is a potential etiology for cardiopulmonary arrest in patients like this case. However, it is a challenge in differential diagnosis of this patient whether or not methadone intake induced prolonged QT interval; however, in COVID-19 patients, methadone-induced prolonged QTc interval should be placed somewhere in the differential diagnosis list, especially in those with a suspicious history (10). In addition animal studies have demonstrated COVID-19 might prolong QTc interval per se (11).

Conclusion

According to this report, sudden cardiopulmonary arrest can be one of the consequences of COVID-19, especially in patients with sudden cardiac arrest. This presentation, though rare, is an important issue since it could potentially lead to sudden unexplained death. Drugs like methadone, which are known to prolong QTc interval, may make patients more susceptible to cardiac complications.

Acknowledgment

The authors would like to acknowledge the kind efforts of the personnel, Anesthesiology Research

Center, SBMU, Tehran, Iran for their kind help and support.

Conflicts of Interest

The authors declare that there are no conflicts of interest.

References

1. Jin JM, Bai P, He W, Wu F, Liu XF, Han DM, et al. Gender Differences in Patients with COVID-19: Focus on Severity and Mortality. *Front Public Health*. 2020;8:152.
2. Tabashi S, Mirkheshti A, Dahi M, Abtahi D, Vosoughian M, Sayyadi S, et al. Supplemental oxygen therapy and non-invasive ventilation in Corona Virus Disease 2019 (COVID-19). *J Cell Mol Anesth*. 2020;5(1):27-31.
3. Lillie PJ, Samson A, Li A, Adams K, Capstick R, Barlow GD, et al. Novel coronavirus disease (Covid-19): The first two patients in the UK with person to person transmission. *J Infect*. 2020;80(5):578-606.
4. Zheng YY, Ma YT, Zhang JY, Xie X. COVID-19 and the cardiovascular system. *Nat Rev Cardiol*. 2020;17(5):259-60.
5. Rahmatizadeh S, Valizadeh-Haghi S, Dabbagh A. The Role of Artificial Intelligence in Management of Critical COVID-19 Patients. *J Cell Mol Anesth*. 2020;5(1):16-22.
6. Lamy PJ, Rébillard X, Vacherot F, de la Taille A. Androgenic hormones and the excess male mortality observed in COVID-19 patients: new convergent data. *World J Urol*. 2020:1-3.
7. Tavazzi G, Pellegrini C, Maurelli M, Belliato M, Sciutti F, Bottazzi A, et al. Myocardial localization of coronavirus in COVID-19 cardiogenic shock. *Eur J Heart Fail*. 2020;22(5):911-5.
8. Wang D, Hu B, Hu C, Zhu F, Liu X, Zhang J, et al. Clinical characteristics of 138 hospitalized patients with 2019 novel coronavirus-infected pneumonia in Wuhan, China. *JAMA*. 2020;323(11):1061-9.
9. Xiong TY, Redwood S, Prendergast B, Chen M. Coronaviruses and the cardiovascular system: acute and long-term implications. *Eur Heart J*. 2020;41(19):1798-1800.
10. Krantz MJ, Martin J, Stimmel B, Mehta D, Haigney MC. QTc interval screening in methadone treatment. *Ann Intern Med*. 2009;150(6):387-95.
11. Alexander LK, Keene BW, Yount BL, Geratz JD, Small JD, Baric RS. ECG changes after rabbit coronavirus infection. *J Electrocardiol*. 1999;32(1):21-32.