

## Evaluation of Omphalocele Treatment Using New Surgical Technique

Shahnam Askarpour<sup>1\*</sup>, Mehran Peyvasteh<sup>1</sup>, Alireza Sadeghi<sup>1</sup>, Hazhir Javaherizadeh<sup>2</sup>

<sup>1</sup> Department of Pediatric Surgery, Ahvaz Jundishapur University of Medical Sciences, Ahvaz, Iran

<sup>2</sup> Alimentary Tract Research Center, Ahvaz Jundishapur University of Medical Sciences, Ahvaz, Iran

\*Address for Corresponder: Dr. Shahnam Askarpour, Department of Pediatric Surgery, Ahvaz Jundishapur University of Medical Sciences, Ahvaz, Iran (email: shahnam\_askarpour@yahoo.com)

### How to cite this article:

Askarpour Sh, Peyvasteh M, Sadeghi A, Javaherizadeh H. Evaluation of Omphalocele Treatment Using New Surgical Technique. Iranian Journal of Pediatric Surgery 2021; 7 (1): 9-14.

DOI: <https://doi.org/10.22037/irjps.v7i1.33347>

### Abstract

**Introduction:** The aim of this study was to evaluate a new technique for treatment of omphalocele using mesh fixation to skin with preserved omphalocele sac.

**Materials and Methods:** Chart of patients who treated with mesh fixation were reviewed. Demographic features, mortality and morbidity following treatment were recorded.

**Results:** in the current study 68 patients (f=32, m=36) were included. Of 68 cases, 44(64.7%) had giant omphalocele. Among all cases, 20(29.4%) had isolated omphalocele. Mortality was 26.5%(18 of 68). Of survived cases, 21(42%) had detached mesh. Adhesion band was seen in 4(8.2%) of cases. Sepsis was seen in 11.8% of the cases.

**Conclusion:** According to the result of the study, suggested technique is promising and had several benefits. Duration of hospital staying, duration of intubation was less than previous techniques.

### Keywords

- Mesh
- Omphalocele

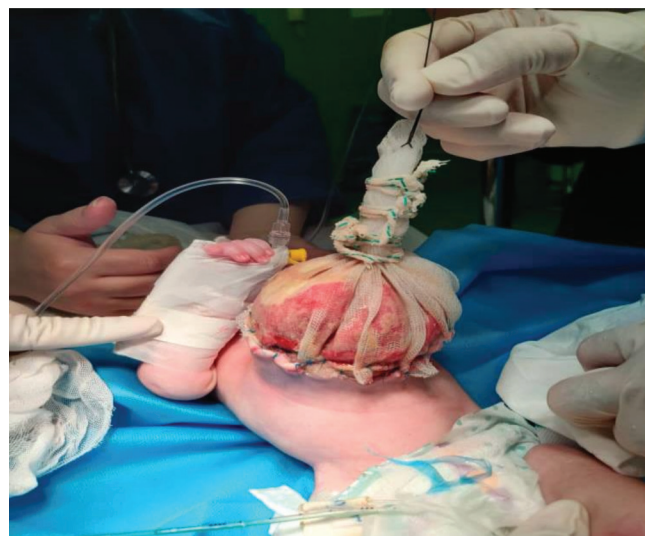## Introduction

Congenital defects of the abdominal wall are considered as one of the most common surgical diseases in neonates and infants, of these, omphalocele and gastroschisis are the most common.<sup>1</sup> The incidence is estimated one in 6000 live births.<sup>2</sup> The prevalence of omphalocele was reported 2.63 per 10,000 live birth in Singapore.<sup>3</sup> Early at the first trimester, physiologic herniation of intestine into the umbilical cord occurs. Failure of the herniated intestine to return into the abdominal cavity between 6 to 10 weeks of gestation results in omphalocele formation.<sup>4, 5</sup> Some authors considered giant omphalocele when diameter of the defect was larger than 5 to 6 cm and the sac contains whole or most of the liver.<sup>6</sup> Between 37 to 67% of giant omphalocele are seen with Beckwith-Widemann syndrome or pentalogy of Cantrel.<sup>7</sup> Different methods for treatment of omphalocele were described.<sup>8,9</sup> In the current study we described the results of mesh fixation over the skin for a ten-year period. In this method, a synthetic mesh was fixed to the skin and the omphalocele sac was preserved.

## Materials and Methods

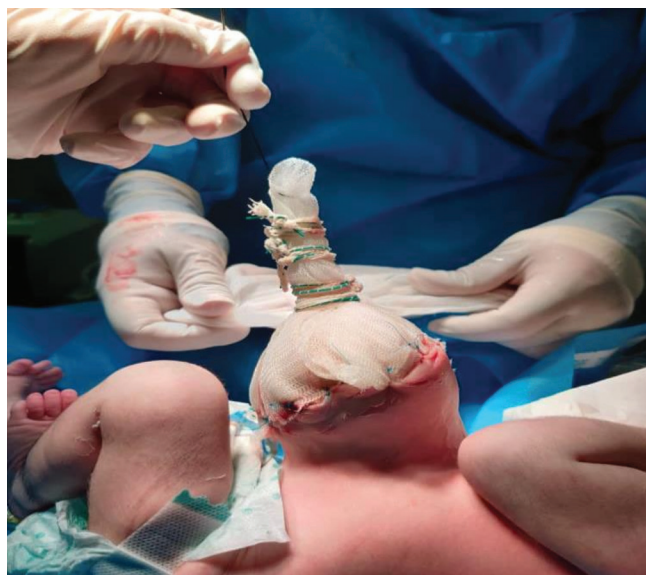In this retrospective study, which lasted over a 10-year period, mesh was placed on superficial layer of the skin. Mesh was fixed on the edges of the skin instead of fascia **Figure 1**. In this method, omphalocele sac was preserved. This study was approved by ethical committee of the university. In the new technique performed in this study, without the sac excision and without the need to expose the fascia around the sac, a Dual mesh is placed on the

sac and a silo is created and the edges of the mesh are sutured to the skin around the omphalocele. This method reduces the chance of infection and diffuse peritonitis, as well as the possibility of damage to the viscera and bleeding during removal of the sac and the duration of the operation.

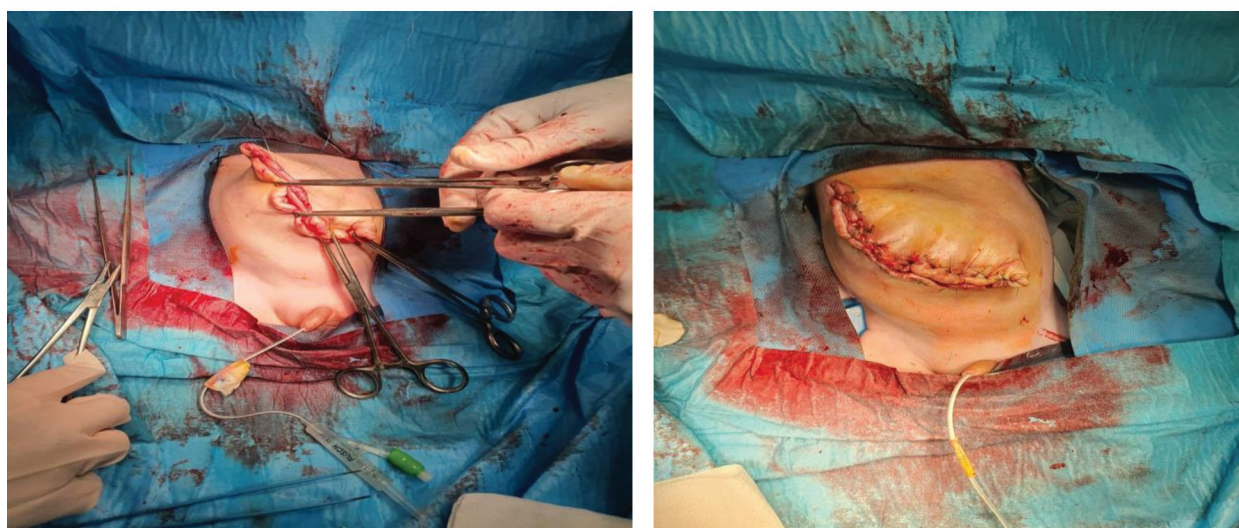


**Figure 1:** Day 1 Dual mesh sutured to skin

The silo is then held vertically and serially tied from above, and the viscera are pushed into the abdomen and the knots are brought down so that the entire viscera are gradually inserted into the abdomen **Figure 2**. By returning of all the viscera into the abdomen, either the skin closes and in the future becomes a ventral hernia; which is operated on at the right time, or as the defect shrinks, the skin closes on its own and becomes granulation tissue **Figure 3**.



**Figure 2:** Day 3 gradual reduction of viscera



**Figure 3:** Skin closure after full reduction of viscera

In the current technique, sac of omphalocele and abdominal muscle remain intact. Demographic features of the patients was recorded. P value < 0.05 was considered significant.

### Results

Mean of gestational age was  $37.662 \pm 2.4226$

(31.5-40.5 weeks). Mean of birth weight was  $2914.85 \pm 547.30$  ranged 2105-4000 gram. Mean age of the mothers was  $31.18 \pm 6.67$  ranged 18-45 years old. Of 68 patients, 32(47.1%) were female and 36(52.9%) were male. Of 68 cases, 47(69.1%) had associated diseases. Twenty-one cases had isolated omphalocele. Of 68 cases, 8(11.8%) had

sepsis like illness. Giant omphalocele was seen in 44(64.7%) of cases. Giant omphalocele was seen in 62.5% of girls and 66.7% of boys ( $p=0.8$ ). Of 68 neonates, 21(30.9%) were IUGR. Of all caes, 20(29.4%) had separated omphalocele. Prematurity was seen in 24(35.3%) of cases.

Among patients, 18 cases (26.5%) died after surgery. Finally, 50 cases survived at the end of follow up.

Of patients, 18 patients died. Of survived caes, 4(8.2%) adhesion band was seen. Of survived cases, 40(80%) of cases showed sac epithelialization at the end of first month following surgery. Duration of surgery was  $44.71\pm 4.80$  minutes ranged 30-60 minutes. Duration of hospital admission was  $22.90\pm 4.51$  days ranged 15-36 days. Oral feeding was initiated  $4.46\pm 0.91$  days ranged 3-7 days after surgery. Post operative mortality was seen in 28.1% of girls and 25% of boys ( $p=0.49$ ). Associated abnormalities were seen in 65.6% of girls and 72.2% of boys ( $p=0.6$ )

Frequency of sepsis was 15.6% among girls and 8.3% among boys without statistical significance ( $p=0.46\%$ ). Frequency of giant omphalocele was 62.5% among girls and 66.7% among boys ( $p=0.8$ ). Frequency of IUGR was 31.3% among girls and 30.6% among boys without statistical significance ( $p=0.57$ ). Frequency of prematurity was 37.5% among girls and 33.3% among boys without statistical difference ( $p=0.8$ ). Adhesion band was reported 9.1% among girls and 7.4% among boys ( $p=0.61$ ). Epithelialization of sac was seen in 82.6% of girls and 77.8% of boys ( $p=0.73$ )

## Discussion

The incidence of omphalocele was reported 27.41 per 10,000 live birth in previous studies.<sup>10</sup> In the study by Calzolari et al, the prevalence of omphalocele was 2.52 per 10,000.<sup>11</sup> In the recent multi country study, the prevalence of omphalocele was 2.6 per 10,000 live birth.<sup>12</sup>

The mortality of omphalocele in the current study was 26.5%. In the study by Hwang and Kousseff<sup>13</sup>, mortality rate was 22% which is slightly lower than our study. The overall mortality rate in a multi country study was 32.1%.<sup>12</sup> The differences in mortality rates may be related to type of procedure, weight of neonates, or associated anomalies.

Among our cases, 47.1% were female and 52.9% were male. In the study by Yazbeck et al, male: female ratio was 3.2.<sup>14</sup>

Associated anomaly and disease were seen in 69.1% of the patients. In the study by Yazbeck et al., associated anomaly apart from malrotation, was present in 45% of the patients.<sup>14</sup> Associated anomalies was higher in our study compared to Yazbeck et al.<sup>14</sup>

Sepsis was seen in 11.8% of the patients. IUGR was seen in 30.9% of the neonates. Giant omphalocele was seen in 64.7% of the patients. Prenatal diagnosis of omphalocele was done 33.8% of the neonates. Ultrasound analysis in the first trimester is the valuable for diagnosis of omphalocele.<sup>15</sup> Prematurity was seen 35.3% of the neonates. In the study by Mayer et al, omphalocele was associated by 23% of prematurity.<sup>16</sup> Adhesion band was seen in 8% of cases. Of these cases, 5%

led to reoperation. In the study by van eijck et al, 18% of children had post operative adhesion band which was higher than our study.

Sepsis was reported in 12% among our cases. In another study, frequency of sepsis was 35%. According to Saxena and Raicevic study, sepsis was the independent iatrogenic factor in the mortality.<sup>17</sup> As mentioned above, mortality of omphalocele in our study was similar to other studies. In the current technique, sac of omphalocele and abdominal muscle remain intact.

### Conclusion

According to the result of the study, suggested technique is promising and had several benefits. Duration of hospital staying, duration of intubation was less than previous techniques.

### References

1. Islam S: Advances in Surgery for Abdominal Wall Defects: Gastroschisis and Omphalocele. Clin Perinatol 2012; 39: 375-86.
2. Danzer E, Gerdes M, D'Agostino JA, et al: Prospective, interdisciplinary follow-up of children with prenatally diagnosed giant omphalocele: short-term neurodevelopmental outcome. J Pediatr Surg 2010; 45: 718-23.
3. Tan K, Tan K, Chew S, et al: Gastroschisis and omphalocele in Singapore: a ten-year series from 1993 to 2002. Singapore Med J 2008; 49: 31-6.
4. Davis NM, Kurpios NA, Sun X, et al: The chirality of gut rotation derives from left-right asymmetric changes in the architecture of the dorsal mesentery. Dev Cell 2008; 15: 134-45.
5. Thieme GA: Developmental malformations of the fetal ventral body wall. Ultrasound Q 1992; 10: 225-66.
6. Pacilli M, Spitz L, Kiely EM, et al: Staged repair of giant omphalocele in the neonatal period. J Pediatr Surg 2005; 40: 785-8.

### Limitation

Retrospective study was the main limitation

### Ethical Consideration

This study was approved by Ahvaz Jundishapur University of Medical Sciences with code number IR.AJUMS.REC.1398.087

### Acknowledgements

Not applicable

### Funding/Support

Not applicable

### Conflict of interests

There is no conflict of interest

7. Bauman B, Stephens D, Gershon H, et al: Management of giant omphaloceles: A systematic review of methods of staged surgical vs. nonoperative delayed closure. *J Pediatr Surg* 2016; 51: 1725-30.
8. Foroutan H, Jenabali Jahromi B, Dastgheyb N, et al: A New Method of Repairing Giant Omphaloceles with Bilateral Mesh Grafts Lateral to the Rectus Abdominis Muscles. *Ann Colorectal Res* 2013; 1: 0-.
9. Binet A, Scalabre A, Amar S, et al: Operative versus conservative treatment for giant omphalocele: Study of French and Ivorian management. *Ann Chir Plast Esthet* 2020; 65: 147-53.
10. Askarpour S, Ostadian N, Javaherizadeh H, et al: Omphalocele, gastroschisis: epidemiology, survival, and mortality in Imam Khomeini hospital, Ahvaz-Iran. *Pol Przegl Chir* 2012; 84: 82-5.
11. Calzolari E, Bianchi F, Dolk H, et al: Omphalocele and gastroschisis in Europe: A survey of 3 million births 1980–1990. *Am J Med Genet* 1995; 58: 187-94.
12. Nembhard WN, Bergman JEH, Politis MD, et al: A multi-country study of prevalence and early childhood mortality among children with omphalocele. *Birth Defects Res* 2020;112:1787-180.
13. Hwang P-J, Kousseff BG: Omphalocele and gastroschisis: an 18-year review study. *Genet Med* 2004; 6: 232-6.
14. Yazbeck S, Ndoeye M, Khan AH: Omphalocele: A 25-year experience. *J Pediatr Surg* 1986; 21: 761-3.
15. Roux N, Grangé G, Salomon LJ, et al: [Early diagnosis of omphalocele: Prognostic value of the herniated viscera for associated anomalies]. *Gynecol Obstet Fertil Senol* 2019; 47: 637-42.
16. Mayer T, Black R, Matlak ME, et al: Gastroschisis and omphalocele. An eight-year review. *Ann Surg* 1980; 192: 783.
17. Saxena AK, Raicevic M: Predictors of mortality in neonates with giant omphaloceles. *Minerva Pediatr* 2018; 70: 289-95.