


A Case of Giant Gastric Trichobezoar

Saeed Aslanabadi¹, Davoud Badebarin¹, Sina Parsay^{1*}, Masoud Jamshidi¹, Ebrahim Farhadi¹, Amirhossein Ladan¹

¹ Tabriz University of Medical Science, Tabriz, Iran

*Address for Corresponder: Dr. Sina Parsay, Tabriz University of Medical Science, Tabriz, Iran (email: sinaparsa91@gmail.com)

How to cite this article:

Aslanabadi S, Badebarin D, Parsay S, Jamshidi M, Farhadi E, Ladan A. A Case of Giant Gastric Trichobezoar. *Iranian Journal of Pediatric Surgery* 2019; 5 (2):98 -101

DOI: <https://doi.org/10.22037/irjps.v5i2.23729>

Abstract

Trichobezoar is an unusual form of bezoar found in the digestive tract, mostly in the stomach. The patient is often a female in her adolescence who pulls out and swallows her hair. This habit could stem from anxiety and the trichotillomania disorder. These hairs accumulate in the stomach and cause gastrointestinal symptoms. Our patient is a 14-year-old girl who came to us complaining of abdominal pain. Upon further evaluation by ultrasonography and endoscopy, trichobezoar was diagnosed. Laparotomy and gastrotomy were performed, and a large bezoar was removed. Although the occurrence of trichobezoar is rare, surgeons should always consider the situation in patients with vague gastrointestinal symptoms and psychological problems, especially in young female individuals.

Keywords

- Trichobezoar
- Trichotillomania
- Trichophagia
- Gastrotomy
- Rapunzel Syndrome

Introduction

The etymology of the term “bezoar” indicates that its origin is Persian. The synonym of the word antidote “padzahr” modified as “badzehr” in Arabic, and then took the form of “bezoar.” In ancient times, materials from the stomach and intestine of animals were extracted and ingested as remedies for various maladies and as antidotes to poisons.

Trichobezoar is a rare condition in which a patient tends to pull out and eat his or her hair. An

important underlying cause for such a situation is a psychiatric disorder, called trichotillomania followed by trichophagia.^{1,2}

Because of their slippery surface swallowed hairs can escape from peristalsis, retain within the gastric folds, undergo denaturation by gastric acid, become compacted by food and form a dense mass which is trapped in the stomach and causes underlying signs and symptoms.^{3,4}

Patient’s symptoms include: early satiety, nausea and vomiting, abdominal pain and weight loss.

received: 15 December 2018

accepted: 06 April 2019

online submission: 01 November 2019

This open-access article is distributed under the terms of the Creative Commons Attribution Non Commercial 3.0 License (CC BY-NC 3.0).

Downloaded from: <http://journals.sbmu.ac.ir/irjps>

Symptoms vary based on the size of the mass and its extensions. In some cases, bezoar extends into the jejunum and ileum, which is called the Rapunzel Syndrome.^{5,6}

Early diagnosis and immediate management are crucial to avoid possible medical and surgical emergencies.⁷

Although ultrasonography (US) and computerized tomography (CT) could be helpful in diagnosis, the final diagnosis can be only confirmed by endoscopy.⁸

The treatment is based on surgical removal of the bezoar as well as management of the underlying psychiatric condition in order to prevent reoccurrence.

Case presentation

The patient was a 14-year-old girl who was referred to the emergency department with a complaint of abdominal pain in the epigastric region. The pain had begun in the past two weeks, was progressive, not spreading and was aggravated by eating. Except for nausea, there was no other sign. The patient did not have a history of previous illness and did not use a particular medicine.

Her vital signs were normal. She was also conscious, a little dehydrated, and there was no evidence of jaundice. On physical examination, there was an

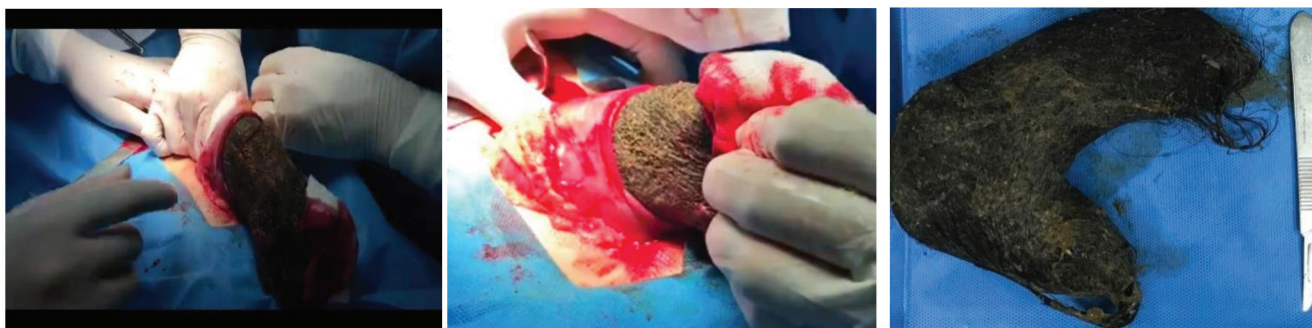
asymmetrical distension in the upper and middle abdomen. There was a palpable mass in the upper abdomen that was not tender, non compressible and also was not mobile.

The ultrasonographic study revealed an echogenic mass in the upper abdomen most compatible with a gastric bezoar. The liver and spleen were normal. The subsequent endoscopic survey demonstrated a normal oesophageal mucosa with a large trichobezoar that filled the entire gastric cavity.

The patient got prepared for surgery. The procedure was performed by upper midline laparotomy and anterior gastrotomy to access the gastric lumen. A giant trichobezoar, which filled the entire gastric cavity and took the shape of the stomach, was removed.

The day after the operation, the patient was visited by a pediatric psychiatrist, she stated that she tended to pull out and ear her hair, which gradually became a habit and worsened during anxiety periods. She also added that it had intensified since her grandmother passed away. She had generally had a good spirit and did not have any particular problems in her daily life. The psychiatrist suggested a long-term periodic visit and prescribed Fluoxetine and Risperidone.

The patient recovered well and was discharged five days after surgery.



Discussion

A bezoar is a dense mass consisting of indigestible ingested materials found within the gastrointestinal tract, most commonly in the stomach. Based on the core component of bezoars, they are categorized into four subtypes: phytobezoar (comprised of cellulose-rich vegetable materials), trichobezoar (hair), pharmacobezoar (medications), and lactobezoars (dairy products).⁹

Trichobezoars were first described in the mid-nineteenth century. It is often seen in young girls who have a type of psychiatric disorder known as trichotillomania (10). Bezoars can cause various gastrointestinal symptoms based on their space occupying nature within the gastric lumen.

The patients and their family are often unaware of such a condition. Furthermore, the rarity of the disease and its nonspecific symptoms makes its diagnosis difficult and usually delayed.

Although an X-ray study is not thoroughly diagnostic, it can sometimes show gastric and antral distension. Also in rare cases of gastric perforation, the free air below the diaphragm can be seen in the

plain radiograph. Ultrasound and CT scan play a significant role in diagnosis. Upper GI Endoscopy is the definitive and selective diagnostic method for gastric bezoars; it also has therapeutic value in case of small lumps.^{3,4,11}

For the treatment of the bezoar, there are several therapeutic modalities available, such as open surgery, laparoscopic or endoscopic removal by mechanical fragmentation or using chemicals. Among them, conventional laparotomy is the method of choice for the removal of a trichobezoar (2, 6). Laparoscopy techniques have also been described in the recent literature as a novel method for removing small to moderate sized bezoars.^{4,12} In cases with large trichobezoars, laparoscopic management is difficult due to the fact that the longer duration of laparoscopic surgery will result in a higher risk of migration of the hairball toward ileum and specifically the risk of spilling contaminated hair fragments into the abdominal cavity.^{1,2,6}

Also, psychiatric consultation with long-term treatment is essential to prevent relapse and improve the patient's quality of life.

Acknowledgements

Not applicable

Conflict of interests

The authors declare that they have no conflict of interests.

Funding/Support

Not applicable. No financial support is required for the current study.

References

1. Jha AK, Mishra MK, Kumar R, et al: Giant gastroduodenal trichobezoar: An endoscopic surprise. *Journal of Digestive Endoscopy* 2018;9(3):131.
2. Gorter R, Kneepkens C, Mattens E, et al: Management of trichobezoar: case report and literature review. *Pediatric surgery international* 2010;26(5):457-63.
3. Lamanna A, Sidhu A, Foo J, et al: A Case of Large Gastric Trichobezoar: Case Report and Review of Literature. *Archives of Clinical and Medical Case Reports* 2018;2(3):101-5.
4. Couceiro A, Viveiro C, Capelão G, et al: Trichobezoar—A rare cause of abdominal mass and gastric outlet obstruction. *GE Portuguese journal of gastroenterology* 2016;23(1):50-3.
5. Ramlingam P, Kartheek G, Rao KS, et al: Rapunzel Syndrome—Gossypol Trichobezoar Case Report and Review of Literature. *Indian Journal of Surgery* 2018:1-3.
6. Gonuguntla V, Joshi D-D: Rapunzel syndrome: a comprehensive review of an unusual case of trichobezoar. *Clinical medicine & research* 2009;7(3):99-102.
7. Carr JR, Sholevar EH, Baron DA: Trichotillomania and trichobezoar: a clinical practice insight with report of illustrative case. *JOURNAL-AMERICAN OSTEOPATHIC ASSOCIATION* 2006;106(11):647.
8. Sehgal V, Srivastava G: Trichotillomania±trichobezoar: revisited. *Journal of the European Academy of Dermatology and Venereology* 2006;20(8):911-5.
9. Ugenti I, Travaglio E, Lagouvardou E, et al: Successful endoscopic treatment of gastric phytobezoar: A case report. *International journal of surgery case reports* 2017;37:45-7.
10. Western C, Bokhari S, Gould S: Rapunzel syndrome: a case report and review. *Journal of Gastrointestinal Surgery* 2008;12(9):1612-4.
11. Ersoy Y, Ayan F, Ayan F, et al: Gastro-intestinal bezoars: thirty-five years experience. *Acta Chirurgica Belgica* 2009;109(2):198-203.
12. Tudor E, Clark M: Laparoscopic-assisted removal of gastric trichobezoar; a novel technique to reduce operative complications and time. *Journal of pediatric Surgery* 2013;48(3):e13-e5.