

Management and outcomes of hidden penis in children

Alireza Mirshemirani^{1*}
Javad Ghoroubi¹

Ahmad Khaleghnejad Tabari¹
Leily Mohajerzadeh¹

Mohsen Rozroukh¹
Saran Lotfollahzadeh¹

¹Pediatric Surgery Research Center, Research Institute for Children Health, Shahid Beheshti University of Medical Sciences, Tehran, Iran

***Address for Corresponder:** Dr Alireza Mirshemirani, Pediatric Surgery Research Center, Research Institute for Children Health, Shahid Beheshti University of Medical Sciences, Tehran, Iran (email: almirshemirani@gmail.com)

How to cite this article:

Mirshemirani A, Khaleghnejad Tabari A, Rozroukh M, Ghoroubi J, Mohajerzadeh L. Management and outcomes of hidden penis in children. Iranian Journal of Pediatric Surgery 2017; 3(2): 94-99. DOI: <http://dx.doi.org/10.22037/irjps.v3i2.17570>

Abstract

Introduction: Hidden penis may have different categories: Concealed, trapped, and buried types. The aim of this study was to evaluate the results and outcomes of repaired cases.

Material and Methods: A total of 40 patients (5 months -12 years old) underwent surgical repair for different types of hidden penis from April 2010 to December 2015 in our hospital. Multiple surgical procedures were performed for each type. Data were collected and evaluated for number of patients, type of anomalies, surgical techniques, outcome and follow-up.

Results: All forty cases underwent surgical repair. In all cases of concealed and buried penis penile degloving and penile fixation was used. In all of our cases improved function and good outcome was reported.

Conclusions: Patients with hidden penis are in great psychological risks. The aim of hidden penis repair is to restore an aesthetic and functional penis which we are happy that we provided for our patients.

Keywords

- Hidden penis
- Surgical repair
- Buried

Introduction

The term hidden penis is used when the penis cannot be seen or is too small. Hidden penis have different categories: Concealed (before circumcision), trapped (after circumcision due to scar or cicatrices), and buried (in adolescence & obesity)^{1,2}. Buried penis is one of the most difficult types of hidden penis which needs surgical management either in children or in adults. This type was first described in 1919 by Keyes. Crawford in 1977 also described it and categorized it to be complete or partial³. Maizels et al⁴ in 1986 described a new classification: Buried penis (redundant suprapubic fat/lack of penile skin), Webbed penis (scrotal skin webs) Trapped penis (shaft is entrapped in the scarred post trauma or circumcision)⁵. Surgical treatment depends on the type of anomalies.

Materials and Methods

Totally 40 patients (5 months to 12 years old) with different types of hidden penis were surgically repaired from April 2010 to December 2015 in our hospital. All patients were evaluated clinically to emphasis on: presence/absence of the prepuce, length of the penis, length of the penile skin, and present of scar/inflammations following circumcision. Multiple surgical procedures were performed for each type: Degloving penis and fixation of the skin shaft and base of the penis to the buck's fascia in buried penis cases. Penoscrotal junction transverse incision and circumferential dissection along the buck's fascia then fixation of the dartos fascia dermis of penile skin to buck's fascia in webbed penis. Excising the cicatricial scar, penile degloving and reconstruction of penoscrotal and penopubic angles in cases of trapped penis. Data were collected and evaluated regarding type

of anomalies, surgical techniques, outcome and follow-up.

Results

From April 2010 to December 2015 a total of 40 patients were treated for hidden penis. Cases were between 5 months to 12 years old. Sixteen (40%) of patients had trapped penis, and 10 cases had a previous history of circumcision. Twelve (30%) of cases were concealed penis of which 4 cases had undergone circumcision. Eight (20%) were buried penis, mostly were fat and older and 4 (10%) had webbed penis which all were repaired with surgical procedures described above. All patients reported much improvement following surgery and had normal sensation/urination, and all were satisfied of their condition in follow-up visits **Figures 1, 2, and 3** shows the cases, and the **Figures 4 and 5** shows the procedure of repair.

Discussion

A hidden penis may be categorized as webbed, concealed, buried, trapped or inconspicuous. Schloss in 1959 was the first who performed surgical correction of these anomalies, and Glanz in 1968 performed successful corrections in an adult^{1,7-11}. There are two classifications for buried penis: 1-Crawford: which includes (concealed, buried and penoscrotal webs penis)³ and 2-Maizels: which consists of (webbed, buried trapped and micropenis)⁴.

Crawford reported his successful surgical experience in six cases, and recommended treatment in the early ages¹⁰. Horton et al suggested surgical removal of suprapubic adipose tissue¹¹. Donahoe et al reported their procedure of preputial unfurling in four buried penis cases¹². Mohamed

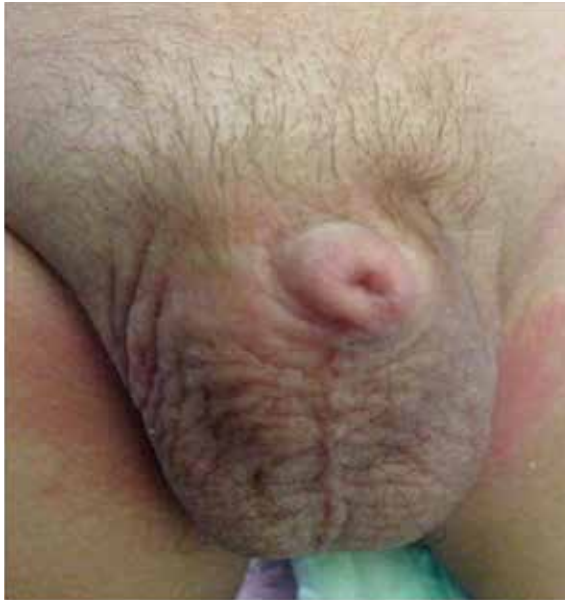

Figure 1: A case of concealed penis that was referred after hormone therapy.



Figure 2: A case of trapped penis after circumcision that has scar / cicatrices (left).

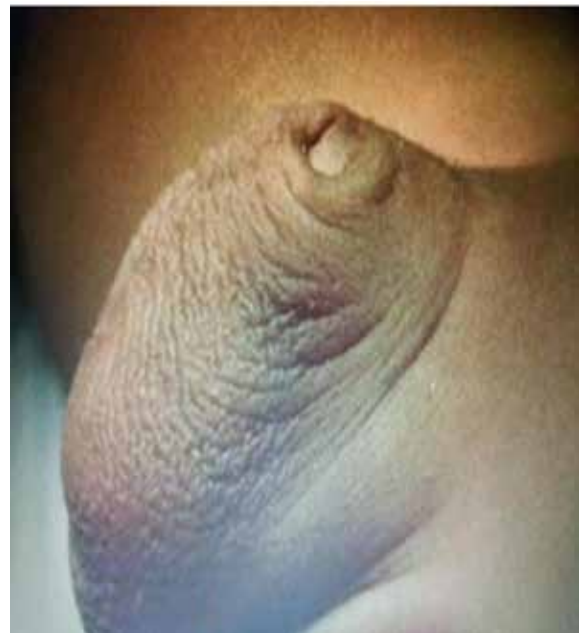


Figure 3: One of our cases with concealed penis before operation.




Figure 4: Concealed penis and a procedure of repair.



Figure 5: A webbed penis and repair procedure.

A. et al¹³ in 2005 reported their 5 years experiences with 80 patients of concealed penis, with cosmetic improvement, in which only one complication occurred which needed reoperation.

Boonjindasup A, et al¹⁴ believes that meshed split-thickness skin graft (StSG) is a practical choice for coverage of wounds during surgical management of patients with concealed penis,

and offers excellent cosmetic results. Chan IHY, et al¹⁵ reported their experience about buried penis and other penile anomalies. Igbokwe MC et al¹⁶ presented their case report about relation of circumcision and concealed penis, and concluded that poor circumcision procedure may cause a wide spectrum of complication¹⁷.

We studied a total of 40 cases, of which: 40%

were trapped, 30% were concealed, 20% were buried, and 10% were webbed. All were corrected surgically, and were happy /satisfied in follow-up visits.

Conclusion

The aim of surgical management in hidden penis is to achieve marked functional and aesthetic improvement, and it needs excellent expertise and procedure's selection.

References

1. Keyes EL: Phimosis, paraphimosis, tumors of the penis. *Urology* 1919;67:649.
2. Bilommi R: Hidden penis in children: Evaluation of outcomes and review of literature. *Med Surg Urol* 2015;4:4.
3. Crawford BS: Buried penis. *Br J Plast Surg* 1977; 30:96-9.
4. Maizels M, Zaontz M, Donovan J, et al: surgical correction of the buried penis: description of a classification system and a technique to correct the disorders. *J Urol* 1986;136:268-71.
5. Chan LH, Wong KK: Common urological problems in children: prepuce, phymosis, and buried penis. *Hong Kong Med J* 2016; 22(3).
6. Jung EH, Son JH, LEE JW: Simple anchoring of the penopubic skin to the prepubic deep fascia in surgical correction of buried penis. *Korean Journal of Urology* 2011;52:787-791.
7. Kojovic V, Bizic M, Majstorovic M, et al: Genital skin flaps for reconstruction of iatrogenic trapped penis. *Eur Urol Meetings* 2008;3: 80.
8. Provic S, Djordjevic M, Kekic Z, et al: Penile surgery and reconstruction. *Curr Opin Urol* 2002;12:191-194.
9. Rivas S, Romero R, Parente A, et al: Simplification of the surgical treatment of a hidden penis. *Actas Urologicas Espanolas* 2011;35:310-314.
10. Maizels M, Zaontz M, Donovan J, et al: Surgical correction of the buried penis: description of a classification system and a technique to correct the disorder. *J Urol* 1986;136:268.
11. Horton CE, Verstman B, Teasley D: Hidden penis release: adjunctive suprapubic lipectomy. *Ann Plast Surg* 2001;19:131.
12. Donahoe PK, Keating MA: Preputial unfurling to correct the buried pens' *Ped Surg* 1986;21:1055.

13. Aziz MA, Gouda SH, Abdalla SH, et al: Management of concealed penis in children. AAMJ 2008;6(2).
14. Boonjindasup A, Pinsky M, Smith W, et al: Management of concealed penis using meshed split-thickness skin grafting in an adult population. The Journal of Urology 2013;189(4):e504.
15. Chan IH, Wong KK: Common urological problems in children: prepuce, phimosis, and buried penis. Hong Kong Med J 2016;22(3):263-9.
16. Igbokwe M, Faye S, Ndoye M, et al: Concealed Penis and Urinary Retention in a Child with Severe Phimosis: A Case Report. Uro Andro 2016;1(6).
17. Thorup j, thorup SC, Ifaoui IB: Complication rate after circumcision in a paediatric surgical setting should not be neglected. Danish Medical Journal 2013;60 (8): A 4681.