

## The Outcomes of Dome Cut in Rhinoplasty versus Alternative Methods in Patients with Various Nasal Tip Deformities

Shahrokh Khoshsiraf<sup>1</sup>, Sepideh Shiravand<sup>1</sup>, Zahra Soroureddin<sup>1\*</sup>

1. Hearing Disorders Research Center, Loghman Hakim Hospital, Shahid Beheshti University of Medical Sciences, Tehran, Iran.

### Article Info

#### Article Note:

Received: July, 2020

Accepted: August, 2020

Publish Online: September, 2020

#### Corresponding Author:

Dr. Zahra Soroureddin

#### Email:

drsorour@sbmu.ac.ir

#### Keywords:

Dome cut;

Rhinoplasty;

Nasal tip deformities.

### Abstract

**Background:** There were several techniques for reconstruction of nasal tip cartilage. Dome cut is a technique that has recently proposed for nasal tip projection, this method is recently concern regarding its efficacy.

**Aim:** This study was performed to determine the outcomes of rhinoplasty with dome cut vs. alternative methods in patients with various nasal tip deformities.

**Methods:** A retrospective review from 36 cases was conducted. Patients were selected from a computerized rhinoplasty database of operative cases. The database was used to extract a subset population that had received the dome cut procedure and had follow-up data for 6 months or more after surgery. Patient satisfaction, physician evaluation, physical examination, blinded comparison of preoperative and postoperative photographs, and revision surgery necessitation were also analyzed in this review of results and complications.

**Results:** Initially 41.7 percent had saddle nose deformity, 41.7% had nasal tip deformity, and 16.7% had other types of deformity. 94.4% had successful outcomes whether the technique and type of deformity had no effect on success of results ( $p > 0.05$ ).

**Conclusion:** According to the obtained results and comparison with other studies, it may be concluded that rhinoplasty with dome cut is a successful method and various methods and deformities have no effect on the outcomes.

**Conflicts of Interest:** The Authors declare no conflicts of interest.

**Please cite this article as:** Khoshsiraf S, Soroureddin Z, Shiravand S. The Outcomes of Dome Cut in Rhinoplasty versus Alternative Methods in Patients with Various Nasal Tip Deformities. J Otorhinolaryngol Facial Plast Surg. 2020;6(1):1-8.

<https://doi.org/10.22037/orlfps.v6i1.32223>

### Introduction

Rhinoplasty is a procedure in plastic surgery for reconstructing the shape or appearance of the nose, in which the most difficult feature of rhinoplasty is tip plasty (1). Traditional methods to remove unwanted bulbosity or convexity have been associated with complications such as rim collapse alar retraction, most notably inspiratory breathing problems, and, Polly beak and supra-tip deformities. A model has been developed to facilitate sculpting, after a conventional tip plasty to constitute a good approximation of what the tip cartilage framework should look

like. Sheen and Sheen (2) described the ideal tip shape as two equilateral geodesic triangles with a common base formed by a line connecting the two domes. They mentioned that the highest projecting point of the tip should lie along the apogee of the curved line that connects both domes. They described the intercrural distance as the interval between the domes, which also illustrates the common base of the 2 geodesic triangles. Daniel defined an angle of dome definition at the domal junction line, with the most aesthetically pleasing tips having a convex domal segment and concave

lateral crus (3). The nasal tip should show “double light reflections” when photographed with a standard 2-flash methods on frontal view. These reflections create a “diamond”-shaped highlight through combination of the dome triangles, the interdomal triangle, and the infralobular polygon. Characteristic of an aesthetic result following tip surgery is appropriate creation of this “diamond shape” light reflection. The extension of the nose from the facial surface by comprehending the distance from the alar groove to the tip of the nose determined as a good technique, and then relating that measurement (of nasal-tip projection) to the length of the nasal dorsum. The nasal projection measurement is obtained by delineating a right triangle with lines parting from the nasion (nasofrontal junction) to the alar–facial–groove. Then, a second, perpendicular delineation, that traverses the tip-defining point, establishes the ratio of projection of the nasal tip. According to Goode (4) definition, a line to the nasal tip drawn perpendicular to a line from the nasion through the alar-facial junction should be 55% to 60% of the dorsal nasal length from the nasion to the tip. The ideal nose regarding to Crumley and Lanser (5) description, is the one, which the length of a line from the nasion to the vermilion cutaneous junction of the upper lip compares with the length of a perpendicular from this line to the tip-defining point with a ratio of 0.2833. In a simplification of these mathematical techniques, Simons relates the length of the upper lip (from the subnasale to the labrale superius) as ideally equivalent to the length from the subnasale to the tip. The lateral crus are flat and 6 mm wide to minimize chances of inspiratory collapse. The dome is about 6 to 8 mm above the dorsum to compensate for the thick supra-tip skin. The angle of domal divergence, defined as the angle made by the medial crura as they splay apart (as seen on basal view), is apparent (6). A separation of about 3 mm between the cephalic ends of the domes is evident, which

should serve as a reminder that the domes are not to be squeezed together. The width of the human nasal-tip ranges 20 to 30 mm; the average width of the nasal tip, measured between the two alar lobules, is approximately 25 mm. Analysis of surface aesthetics allows the surgeon to define the deformities, establish goals, and then determine how to modify the underlying structures. Nasal tip repositioning methods are used to adjust the existing alar cartilages and to augment the nasal lobule with grafts or implants (7). Vertical dome division of the alar cartilage is mostly used for modification of the nasal tip projection in cosmetic and reconstructive rhinoplasty. It is a valuable adjunctive technique for nasal tip refinement (8). The Goldman first described vertical dome, which gives rise to tip irregularities such as lower nasal third pinching and alar notching (8). It might give rise to tip irregularities including lower nasal third pinching, alar notching, and a characteristically-pointed, or "tent pole" nasal tip, particularly in patients who are thin-skinned. The classic Goldman technique, which is also called vertical dome, or tip defining, involves incising the lateral crura and vestibular skin at or lateral to the dome or tip defining point. This incision divides the lower lateral cartilage into medial and lateral segments. The medial segments are then advanced anteriorly and sutured together to increase tip projection. The technique was initially greeted with great enthusiasm followed by numerous criticisms and bitter controversy. Since, it developed with various modifications over the years. The crucial point of discussion is essentially the long-term emergence of unforeseeable consequences as a result of the considerable structural weakening of the alar cartilage (9). The healing process leads in many cases to disruption of the alar cartilages, no longer joined in a single continuous arch capable of withstand the deforming pressures active during cicatrization. The resulting collapse of the

cartilaginous support generates typical irregularities of the nasal tip, which are particularly evident in patients with thin skin (9). These include pinching of the lower third, alar notching, and a characteristically pointed or “tent pole” nasal tip (10). As it did not prove definitively the efficacy of dome cut method for reconstruction nasal tip deformities we aimed to compare dome cut vs. alternative rhinoplasty methods utilizing for various nasal tip deformities.

### Methods

This is a retrospective study, 36 patients were enrolled, which were operated between 2008 and 2009 in Loghman-e- Hakim Hospital, Tehran, Iran.

The database contains information regarding, patients demographic, preoperative analysis, operative techniques, postoperative results and complications. The medical records of all the patients had been entered in to the questionnaire with-out previous consideration given to this study. Medical records and also photographs were also analyzed in the review of results and complications. The local ethics committee approved the study and informed consent was obtained from all patients enrolled into the study.

All patients were operated by one senior surgeon, only patients with tip problems were included and the patients were excluded if they had a septal deviation. That enables tip rotation or dorsum problems that caused tip asymmetry. Outcomes were assessed by comparing the preoperative photograph with the most recent follow-up (6 months).

The photograph were all taken using the same imaging setting and while keeping subject distance and angulation consisted and were analyzed subsequently by an unbiased facial surgeon who was not otherwise involve in the study.

The informations analyzed by SPSS 13, and also we used chi-square test for qualitative

variables and t-test to evaluated quantitative variables.

### Surgical technique

All patients underwent the operation under general anesthesia. To reduce intraoperative hemorrhage, lidocaine (2%) with epinephrine (1:200,000) was infiltrated locally. An open-technique rhinoplasty was performed using stepwise dissection and appropriate detection of cartilage.

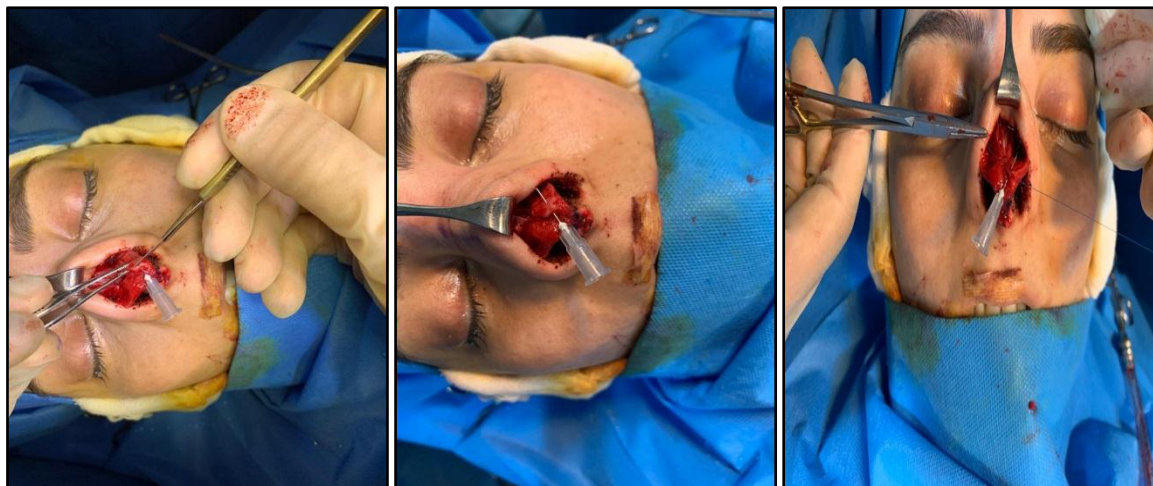The procedure of dome division first involves detachment of the vestibular skin from the surface of the alar cartilages above in correspondence of the domal arch for an area of approximately 7 to 10 mm. The next step is a mattress suture of 5.0 nylon through the lateral and medial crura or their residual stumps so as to ensure temporary solidarity and passing an insulin syringe needle through for more stability of the new dome region. The medial crura are positioned symmetrically before resecting portions of the tip complex to reduce or even eliminate domal asymmetry in cases of lower lateral cartilage (LLC) malpositioning. A scalpel with a number 11 blade is utilized to detach all of the part above the suture and leave a perfectly symmetrical flat surface. It may prove to be useful at this point to reposition the cutaneous flap before proceeding with the following steps, to have some idea of the relations among tip, supra-tip, and dorsum. The next stage involves restoring the continuity of the domal arch by first removing the suture in 5-0 nylon and performing a “figure-of-8” suture of 6-0 nylon through the center of both the lateral and medial crura. This suture, which constitutes an improvement on the simple realignment of the cartilaginous stumps, makes it possible to avoid any undesired overlapping of the edges in the postoperative period. Two more sutures of 6-0 nylon are made on either side caudally and cephalically with respect to the previous “figure-of-8” suture, to obtain complete and

<https://doi.org/10.22037/orlfps.v6i1.32223>

stable continuity with perfect realignment of the medial and lateral crura.

A final check, with the cutaneous flap again lowered, proves extremely useful to decide whether it is necessary to attach a graft of crushed cartilage or auricular perichondrium

(in cases where material is harvested from the concha). This additional procedure helps where necessary to smooth out any residual underlying irregularities and/or increase the projection of the nasal tip (Figure 1).



**Figure 1.** A) First, the area of the dome is marked with a needle, B) Then the cutting is done in the dome area, C) In the next step, the Transdomal Suture is performed.

## Results

In this retrospective study 36 patients enrolled with mean age of 24.8 (SD  $\pm$  3.7) 80.6% of them were female and 19.4% were male.

7 patients (19.4%) had prior rhinoplasty. In this study 41.7% cases had saddle nose, 41.7% had nasal tip deformity and 16.1% had other deformities.

91.7% of patients were satisfactory from their results. Also total score for Successful outcomes are shown in (Figure 2).

41.7% cases had undergone dome cut surgery with utilizing graft and the other cases without graft.

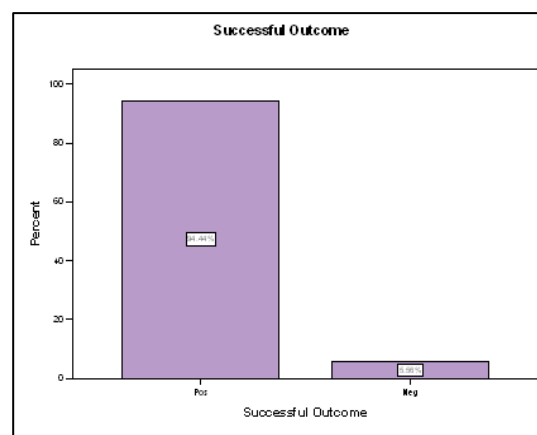
According to results from Table 3, there was no different in type of deformities on satisfactory consequences. (p-value  $>$  0.05)

Also there was no different in type of deformities on patient satisfactions (Table 1).

Moreover, using graft on surgery didn't have any effect on satisfactory consequence of surgery (Table 2).

41.7% cases had undergone dome cut surgery with utilizing graft and the other cases without

graft. According to results from Table 3, there was no different in type of deformities on satisfactory consequences. (p-value  $>$  0.05) Also there was no different in type of deformities on patient satisfactions (Table 1). Moreover, using graft on surgery didn't have any effect on satisfactory consequence of surgery (Table 2).



**Figure 2.** Total score of successful result of dome cut technique in patient with nasal tip projection.



**Table 1.** Total satisfactory score utilizing dome cut technique based on underlying nasal deformities

	Patients' Satisfaction		Total	
	Positive (%)	Negative (%)		
Deformity	Saddle Nose	14 (93.3)	1 (6.7)	15 (100)
	Nasal Tip Def	14 (93.3)	1 (6.7)	15 (100)
	Others	5 (83.3)	1 (16.7)	6 (100)
<b>Total</b>		33 (91.7)	3 (8.3)	36 (100)

**Table 2.** Total satisfactory score based on utilizing dome cut technique with/without cartilage

	Successful Outcome		Total	
	Positive (%)	Negative (%)		
Technique	With Graft	13 (86.7)	2 (13.3)	15 (100)
	Without Graft	21 (100)	0 (0)	21 (100)
<b>Total</b>		34 (94.4)	2 (5.6)	36 (100)

## Discussion

Many researches were done on dome cut accuracy, since it was introduced of the dome division. Surgical changes created in the nasal tip represent an integral part of every aesthetic rhinoplasty accomplished surgeons worldwide differ significantly in their personal preferences for tip refinement approaches and techniques (10).

One conclusion of brief examination of the literature as regard to modify the Goldman's original technique that essential factor in reducing the incidence of postoperative complications is reconstruction of the normal alar cartilaginous anatomy (9).

With this in mind, various authors have put forward various techniques designed to restore a certain degree of continuity to the domal structure. Examples include the modifications introduced over the years by Ponti and Simons and Greene (10), leave the vestibular skin beneath the cartilaginous arch intact, and Adamson (9) seek to restore the continuity of the arch. In revision rhinoplasty where a greater or lesser degree of structural disruption is often already present, it is still more necessary to preserve or reconstruct anatomical continuity of the domal complex so as to ensure a more stable result over time The overdeveloped LLCs (lower lateral cartilage) can be surgically altered in the over projected

nose to improve nasal balance and to deproject the nose. The various surgical maneuvers to modify the LLCs can be categorized into techniques that alter the lateral or medial crura or that involve dome division or truncation. Shortening of the lateral crus can deproject the nose and induce tip rotation to effect controlled retrodisplacement of the tip. Webster (11) advocated a lateral crural flap technique. Instead of completely removing the cephalic aspect of the lateral crus, delineated by a rim strip incision. Webster preserved a portion of the cartilage as a lateral crural flap to provide better stability to the rim strip. Retrodisplacement could be affected by telescoping the rim strip with the flap or by excising a small portion of the flap to create a void, into which the LLC would telescope. Later Kridel and Konior (7) described a lateral crural overlay technique that involved vertically cutting of the lateral crus at its middle aspect, then overlapping and suturing the cut ends to shorten the total length of the lateral crus. Medial crura shortening techniques have also been advocated for deprojection. Lipsett (12) advocated splitting the LLC medial to the dome, resecting a length of the cartilage just lateral to the incision, and reshaping the lateral crus remnant using multiple scoring incisions on the cartilage to recreate a new dome.

Joseph (13) and Safian (14) described achieving deprojection by excising lateral and medial crura elements. This would be later modified to accommodate an external rhinoplasty technique. Close et al., (15) removed a calculated length of the medial and lateral crura. The remnants would be sutured together end to end. Later, Foda (16) and Soliemanzadeh (17) and Kridel (7) combined medial and lateral crura overlay and suturing techniques to effect deprojection. (10) Guyuron (14) and Spina et al. (18) suggested the excision of medial crura foot pods to deproject the nasal tip. Vertical dome division has long been recognized as a useful adjunctive technique in nasal tip surgery. It can be used to effect changes in projection, rotation, and the width of the domain arch because of its versatility, as well as to correct lobule asymmetries and elongation or hanging of the infra-tip lobule. Unfortunately, some surgeons have been reluctant to utilize this technique because of the tip abnormalities that have been reported postoperatively.

In a study on comparison of suture and vertical dome division, techniques of bulbous nose refinement (19) was reported among the 35 patients with transdomal and interdomal technique. Two patients (7.5%) had a previous bulbous nose deformity remained stable of that one patient resulted in revision surgery. The overall satisfaction rate in these patients was approximately 92%. Also, in 35 patients who underwent surgery using vertical dome division method. In 3 patients (6.8%) complication as over narrowing nasal tip was observed which in one case this led to revision surgery and in one case (2.8%) collapse of lower lateral cartilage occurred. It is unquestionably a powerful and versatile tool for modifying the configuration of the nasal tip (9). The result is aesthetically pleasing and lasting when the tip complex heals symmetrically. However, in thin-skinned patients, even slight asymmetries in the final medial cartilage unit can lead to visible bossa

when the overlying soft tissue thins and contracts. Notching and alar retraction may result if the lateral cartilage segments rotate cephalically (7, 20). It is currently regarded as particularly suitable in cases of revision rhinoplasty with extensive structural disruption caused by scarring and the presence of asymmetry and overprojection of the nasal tip. Paradoxically, it is also indicated in correction of the results of previous operations of dome division where the discontinuity of the unsutured domal arch has led to evident deformities over time. A major step forward in the techniques involving resection of the alar cartilage is in fact the combination of this with the overlapping.

In a study by YU et al., (21) in South Korea, published in 2010 found that the vertical dome deviation is an effective method in nasal tip surgeries and had satisfaction of the patients in 95.6% of cases, which matches the finding of our study.

Constantin (22) in 2004 published a study of nasal tip augmentation with different techniques, which only 33% of patients had complete patients satisfaction. However, in our study has a higher index.

VDD (vertical dome deviation) can be used for various nasal deformities, including overprojection or underprojection, suboptimal rotation, disproportionate lobule ratios, and broad or asymmetric tips. Although VDD can dramatically change tip definition, concern exists about the risks of weakening the intrinsic tip support mechanism that can result in tip pinching, alar notching, and tentpole nasal tip (9). Vertical dome technique modified to create an approach with minimal tissue excision that is focused on the incision and mobilization of the lower lateral cartilages. Although vertical dome division can be considered a conservative, cartilage sparing approach to nasal tip surgery, concerns about postoperative asymmetry and cartilage visibility remain, especially in thin-skinned patients (23).

**Limitation:** This study includes some limitations. First, small sample size indicate larger study in future and second short follow-up period, which necessitate longer follow-up studies to better determine possibility of long term complications to the limitations such as tend-pole and bossae deformity to further assess the use of dome cut technique in nasal tip deformities.

### Conclusion

Vertical dome technique is an effective method for nasal tip deprojection and narrowing via an open approach and various deformities have no effect on the outcomes.

### Ethics:

IR.SBMU.RETECH.REC.1398.461

### Acknowledgments

Not declared.

### Conflicts of Interest

The authors declare no conflicts of interest.

### Financial Support

Not declared.

### Authors' ORCIDs

#### Shahrokh Khoshsirat:

<https://orcid.org/0000-0002-8568-627X>

#### Zahra Soroureddin:

<https://orcid.org/0000-0003-2629-3641>

#### Sepideh Shiravand:

<https://orcid.org/0000-0002-7207-7539>

### References

- Gunter JP RR, Adams WP. Dallas rhinoplasty: nasal surgery by the masters 2007.
- Sheen JH SA. Aesthetic Rhinoplasty. 2nd ed: St Louis, MO: CV Mosby; 1987. 1992;89:216-224.
- Daniel RK. The Nasal Tip: Anatomy and Aesthetics. Plastic and Reconstructive Surgery. 1992;89(2):216-24.
- RL G. A method of tip projection measurement. In: Powell N, Humphreys B, eds. Proportions of the Aesthetic Face. New York, NY: Thieme-Stratton;1984.
- Crumley RL, Lanser M. Quantitative analysis of nasal tip projection. The Laryngoscope. 1988;98(2):202-8.
- O'Neal RM IP, Schlesinger J. Surgical anatomy of the nose. Boston: Little Brown;1993.
- Kridel RW, Konior RJ. Dome truncation for management of the overprojected nasal tip. Annals of plastic surgery. 1990;24(5):385-96.
- Chang CW, Simons RL. Hockey-stick vertical dome division technique for overprojected and broad nasal tips. Archives of facial plastic surgery. 2008;10(2):88-92.
- Adamson PA, McGraw-Wall BL, Morrow TA, Constantinides MS. Vertical dome division in open rhinoplasty. An update on indications, techniques, and results. Archives of otolaryngology--head & neck surgery. 1994;120(4):373-80.
- Simons RL FI, editor Evaluation of the Goldman tip in rhinoplasty. In: Plastic and Reconstructive Surgery of the Face and Neck. Proceedings of the Second International Symposium;1977; New York, NY.
- Webster RC. Advances in surgery of the tip: intact rim cartilage techniques and the tip-columella-lip esthetic complex. Otolaryngologic clinics of North America. 1975;8(3):615-44.
- Lipsett EM. A new approach surgery of the lower cartilaginous vault. AMA archives of otolaryngology. 1959;70(1):42-7.
- Kabitzsch JJC. Nasenplastik und Sonstige Geischtsplastik Nebst Mammoplastik. Leipzig, Germany: Curt Kabitzsch;1931.
- S. Corrective Rhinoplastic Surgery. New York, NY: P Hoeber;1935.
- Close LG, Schaefer SD, Schultz BA. The over-projecting nasal tip: precise reduction without rotation. The Laryngoscope. 1987;97(8 Pt 1):931-6.
- Foda HM. Alar setback technique: a controlled method of nasal tip deprojection. Archives of otolaryngology--head & neck surgery. 2001;127(11):1341-6.
- Solimanzadeh P, Kridel RW. Nasal tip overprojection: algorithm of surgical deprojection techniques and introduction of medial crural overlay. Archives of facial plastic surgery. 2005;7(6):374-80.
- Spina V, Kamakura L, Psillakis J. A new method for correction of the prominent nasal tip. Plast Reconstr Surg. 1973;51(4):416-20.

<https://doi.org/10.22037/orlfps.v6i1.32223>

19. Ali Ghazipour NS, Fereydon Eslamijoo. Comparison of suture and vertical dome division techniques of bulbous nose refinement Apadana Journal of Clinical Research. 2012;1:26-32.
20. Funk E, Chauhan N, Adamson P. Refining Vertical Lobule Division in Open Septorhinoplasty. Archives of facial plastic surgery. 2009;11:120-5.
21. Yu MS, Jang YJ. Modified vertical dome division technique for rhinoplasty in Asian patients. The Laryngoscope. 2010;120(4):668-72.
22. Constantian MB. The two essential elements for planning tip surgery in primary and secondary rhinoplasty: observations based on review of 100 consecutive patients. Plastic and reconstructive surgery. 2004 Nov 1;114(6):1571-81.
23. Lavinsky-Wolff M, Dolci JEL, Camargo HL, Manzini M, Petersen S, Romanczuk S, et al. Vertical dome division: a quality-of-life outcome study. Otolaryngology--head and neck surgery: official journal of American Academy of Otolaryngology-Head and Neck Surgery. 2013;148(5):758-63.