

# Changes in the Quality of Life of Our Neonatal Patients Born with Severe Laryngomalacia and Treated with Endoscopic UDP Laser Supraglottoplasty

Gholam Hossein Alim Marvasti<sup>1\*</sup>, Balazs Sztano<sup>1</sup>, Adam Bach<sup>1</sup>, Zoltan Tobias<sup>1</sup>, Laszlo Rovo<sup>1</sup>

1. Department of Oto-Rhino-Laryngology and Head and Neck Surgery, University of Szeged, Hungary.

## Article Info

### Article Note:

Received: August, 2019

Accepted: September, 2019

Publish Online: September,

2019

### Corresponding Author:

Dr. Gholam Hossein Alim Marvasti

### Email:

[alimmarvasti@gmail.com](mailto:alimmarvasti@gmail.com)

### Keywords:

Laryngomalacia;

Ultra-dream pulse laser

(UDP) supraglottoplasty;

Neonatal dyspnea and

inspiratory stridor.

## Abstract

**Background:** Laryngomalacia is one of the most common causes of neonatal dyspnea and inspiratory stridor. In 20% of the cases laryngomalacia in newborns may lead to respiratory failure, feeding difficulties and failure to thrive. The aim of this study was to assess the changes in the quality of life of the patients with laryngomalacia in the first year following ultra-dream pulse laser supraglottoplasty.

**Case presentation:** the assessment relevant parameters of 6 newborn patients with laryngomalacia (4:2 male:female, average age at the time of operation 12,5 days) who underwent ultra-pulse laser supraglottoplasty.

**Conclusion:** Ultra-dream pulse laser supraglottoplasty for laryngomalacia is a safe and effective surgical modality, even if it is performed in the neonatal age.

**Conflicts of Interest:** The Authors declare no conflicts of interest.

**Please cite this article as:** Alim Marvasti GH, Sztano B, Bach A, Tobias Z, Rovo L. Changes in the Quality of Life of Our Neonatal Patients Born with Severe Laryngomalacia and Treated with Endoscopic UDP Laser Supraglottoplasty. J Otorhinolaryngol Facial Plast Surg 2019;5(3):1-4.

<https://doi.org/10.22037/orlfps.v5i3.29826>

## Introduction

Laryngomalacia is one of the most frequent causes of neonatal dyspnea and inspiratory stridor (1,2,3,5).

Laryngomalacia is a functional and structural abnormality of the larynx leading to passive and dynamic collapse of the supraglottic structures (Figures 1. and 2.).

We have been performing UDP laser supraglottoplasty in our patients with laryngomalacia since 2015.

Our aims are to monitor the changes in the development and the quality of life of the patients in the first year following supraglottoplasty (1,4,6,7, 8).

## Cases presentation

We assessed the relevant parameters of 6 newborn patients (4:2 male:female, average age at the time of operation 12,5 days) who underwent UDP laser supraglottoplasty (Figures 3-6) at our clinic between 2015 and 2016 (8).

Follow-up examinations were carried out 3, 6, 9, 12 months after the date of operation and we also reviewed the findings of the pediatric examinations performed in the meantime.

For subjective assessment of the stenosis of the upper respiratory tract we applied the Quality of Life Questionnaire designed for parents. The answers could be placed on a 1 to

<https://doi.org/10.22037/orlfps.v5i3.29826>

4 scale based on the frequency or severity of each symptom (Table 1.).

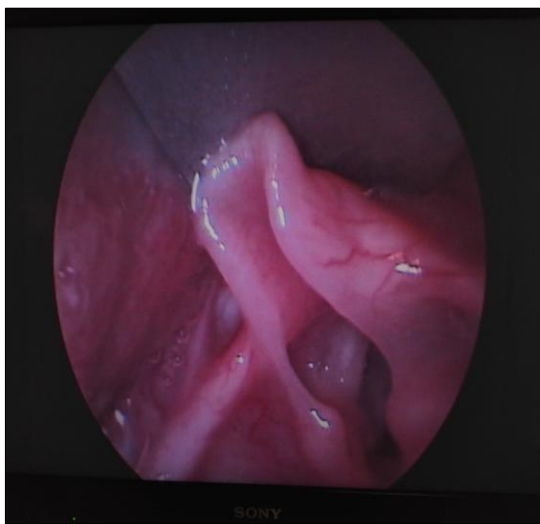In view of the invasiveness of the procedure endoscopic follow-up examinations were not included.

All surgical procedures made under the consultation with pediatric and parents of patients.

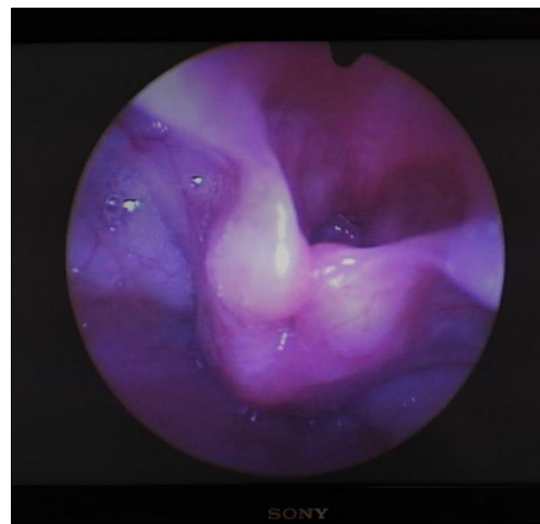
Based on the Quality of Life Questionnaire there was a significant improvement in breathing and feeding difficulty of the patients in the first 3 months after the

operation. In every case, however, comorbidity has been confirmed (e.g. Gastroesophageal reflux disease (GERD), cardiopulmonary failure, Crouzon disease, Axenfeld/Riegler syndrome).

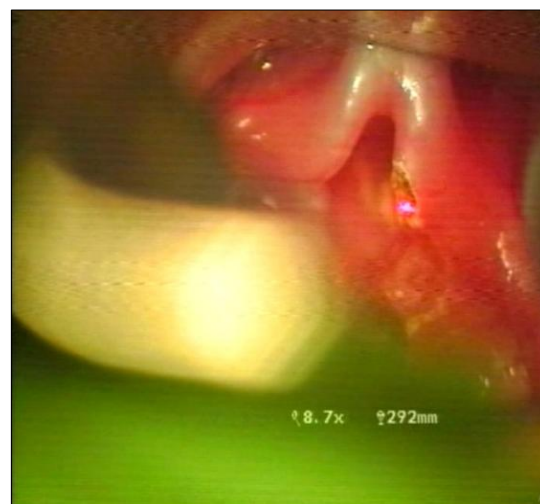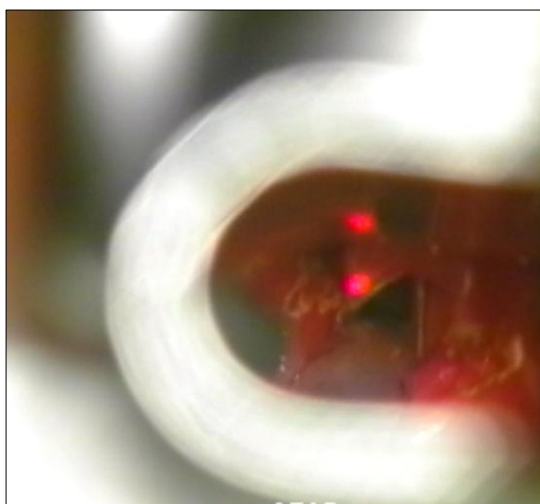
Due to the comorbidities, the development of these infants was retarded compared to healthy infants, even though they had a good laryngeal status. After a one-year follow-up there was no recurrence of the condition and there were no patients requiring repeated operations.



**Figure 1.** Type I. laryngomalacia with inverted corniculate cartilages



**Figure 2.** Type II. laryngomalacia with shortened aryepiglottic fold



**Figure 3.** UDP laser aryepiglottoplasty (intraoperative pictures), wedge resection of the shortened aryepiglottic fold (left) and resection of the edges of the epiglottis (right).

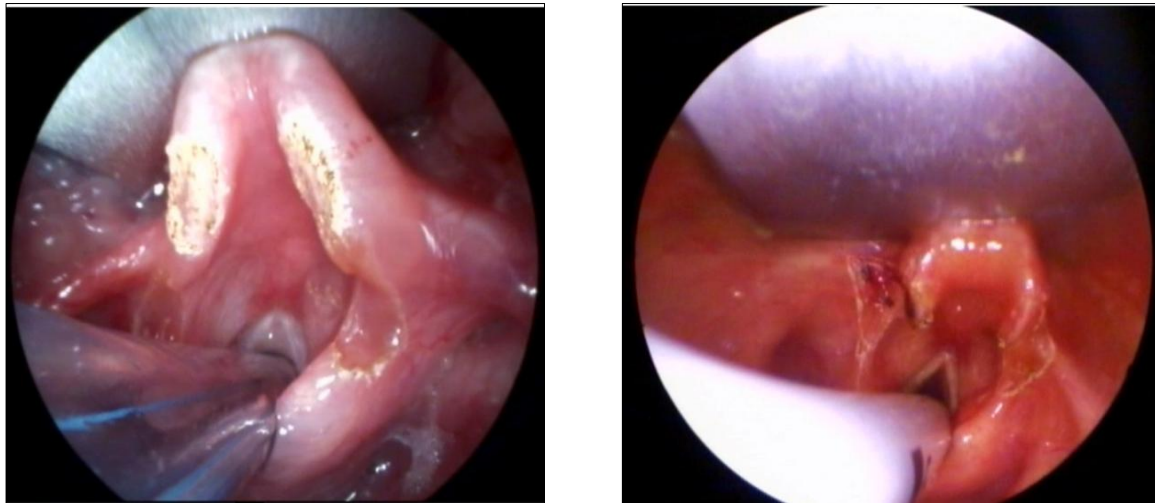
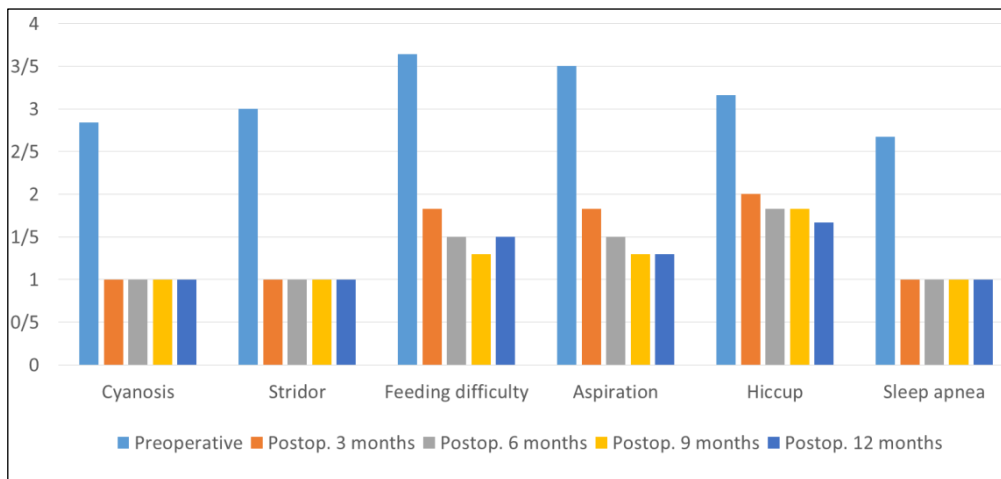


Figure 4. Postoperative pictures after ultra-dream pulse laser surgery.

Table 1. The result of quality of life questionnaire based on parents' response



**Discussion**

Laryngomalacia is manifested as part of a complex syndrome. The defense of the airways is of great importance, which is why ultra-dream pulse laser intervention is indicated in an early age (even in a few days old neonate). Ultra-dream pulse laser supraglottoplasty performed in newborns significantly improves the quality of life. Regarding their laryngeal status, the patients spend their first postoperative year symptom free. The functional results of the operations in early childhood may be evaluated hardly. Endoscopic examinations can be performed only in general anesthesia, which limits its

availability. Functional spirometric tests cannot be done, so this simple subjective self-evaluation test may have a really important role in describing the functional outcomes.

**Conclusion**

Laryngomalacia is manifested as part of a complex syndrome. The defense of the airways is of great importance that is why UDP laser intervention is indicated at an early age (even in a few days old neonate). UDP laser supraglottoplasty performed in newborns improves their quality of life. Regarding their laryngeal status, the patients spend their first postoperative year symptom free. This

<https://doi.org/10.22037/orlfps.v5i3.29826>

situation considerably improves the treatment of other accompanying diseases, as well.

### **Acknowledgments**

This research was supported by Department of Oto-Rhino-Laryngology and Head-Neck Surgery, University of Szeged. We thank our colleagues and also from our patients who provided insight and expertise that greatly assisted the research.

### **Conflicts of Interest**

The authors declare no conflicts of interest.

### **Financial Support**

Not declared.

### **References**

1. Albright JT, Kearns DB, Gray SD. Professional diversity and personal commitment of pediatric otolaryngologists. *Arch Otolaryngol Head and Neck surg* 2003;129:1073-6.
2. Ruben RJ. Development of otorhinological care of the child. *Acta Otolaryngol* 2004;124:536-9.
3. Cook SP. Candidate's thesis: laryngotracheal separation in neurologically impaired children: long term result. *Laryngoscope* 2009;119(2):390-95.
4. Kay DJ, Goldsmith AJ. Laryngomalacia: a classification system and surgical treatment strategy. *Ear Nose Throat J* 2013;85(5):328-331,6.
5. Fearon B, Cotton R. Subglottic stenosis in infant and children: the clinical problem and experimental surgical correction. *Can J Otolaryngol* 1972;89:86.
6. Cotton RT, Evans JNG. Laryngotracheal reconstruction in children: five-year follow up. *Ann Otol Rhinol Laryngol* 1981;90:516-20.
7. Wallander A. The mechanism of origin of congenital malformation of larynx. *Ann Otolaryngol* 1955;45:426.
8. Endoscopic ultra dream pulse laser surgery of laryngomalacia. Our experiences gained during the introduction of the method in Hungary. Tóbiás Z, Pálkó D, Sztanó B, Csanády M, Gál P, Rovó L. *Orvosi Hetilap*, 158 (33). pp. 1288-92.