

# Clear Lens Extraction for Correction of High Myopia

Abbas Abolhasani<sup>1</sup>, MD; Mostafa Heidari<sup>\*2</sup>, MS; Ahmad Shojaei<sup>1</sup>, MD; Seyed Hashem Khoee<sup>1</sup>, MD; Mahmoud Rafati<sup>1</sup>, MD; Ali Moradi<sup>1</sup>, MS

1. Basir Eye Health Research Center, Tehran, Iran.

2. School of medical science. Tehran university of Medical Sciences. Tehran, Iran.

\*Corresponding Author: Mostafa Heidari

E-mail: mostafahaidari70@yahoo.com

## Article Notes:

Received: Oct. 3, 2016

Received in revised form:

Nov. 5, 2016

Accepted: Nov. 29, 2016

Available Online: Jan. 17, 2017

## Keywords:

Intraocular lens

Extraction

Posterior chamber

Myopia

Iran

## Abstract

**Purpose:** To study clear lens extraction and posterior chamber intraocular lens implantation outcomes and safety in correction of high myopia.

**Patients and Methods:** Medical records of 29 patients (40 eyes) who underwent clear lens extraction with posterior chamber IOL implantation to treat high myopia (Axial length > 26.6) were retrospectively reviewed. Visual acuity and refractive error were assessed before and after surgery, and preoperative, intraoperative, and postoperative complications were also recorded.

**Results:** The mean postoperative follow-up period was 10.9 ± 4.63 months (Range, 6 - 19 months). The mean final best corrected visual acuity of 6/10 ± 2/10, was better than preoperative best corrected visual acuity (Mean: 2/10 ± 1/10). Final spherical equivalent (SE), (Mean = - 0.95 ± 0.45 diopters, Range - 0.25 to - 2 D) was better than preoperative SE (Mean = 19.41 D ± 5.31, Range 9 to 31 diopters). No cases of intraoperative complications occurred. The only postoperative complication was posterior capsule opacification in one eye 18 months after surgery and biometric error of (2 D) occurred in one eye.

**Conclusion:** Clear lens extraction with posterior chamber IOL implantation in high myopic eyes has good outcomes with acceptable predictability, improvement in best corrected visual acuity and low rate of complications.

**How to cite this article:** Abolhasani A, Heidari M, Shojaei A, Khoee SH, Rafati M, Moradi A. Clear Lens Extraction for Correction of High Myopia. Journal of Ophthalmic and Optometric Sciences. 2017;1(2):9-14.

## Introduction

Various surgical options for treatment of high myopia have been evaluated. Clear Lens Extraction (CLE) is one of the procedures that have been used to treat high myopia for a long time<sup>1,2</sup>. The technique is associated with high risk of postoperative complications, with the most serious ones mainly related to the posterior segment in association with retinal detachment (RD)<sup>3,4</sup>.

There have been several improvements in cataract surgery. Phacoemulsification in the capsular bag, the use of viscoelastic substances, sutureless scleral tunneling, and better equipments have improved refractive outcomes after lens surgery and caused a new interest in clear lens extraction as a treatment method; therefore some authorities have proposed that phacoemulsification and low-power IOL implantation can provide comparable results to those of other techniques in correction of myopia<sup>5-10</sup>.

Although this method of treatment is rarely used nowadays, the present study was performed to evaluate the effectiveness and safety of this procedure among patient who went under this procedure previously. We retrospectively reviewed visual acuity outcome and intraoperative and postoperative complications in highly myopic eyes treated with this method.

## Patients and Methods

The medical records of 40 patients who underwent CLE and posterior chamber IOL implantations were reviewed retrospectively. Criteria for offering surgery were severe preoperative myopia (axial length > 26.6 mm) as determined by A - Scan, a best spectacle-corrected distance visual acuity (BSCVA) of 1 meter counting finger or better, intolerance to contact lens use, and age between 23 and 48 years.

All surgeries were performed by one surgeon at Basir Eye Clinic, Tehran, Iran. In 1 eye with a retinal hole, we performed argon laser photocoagulation before the surgery. Intraocular lens power calculations were performed using the Sanders-Retzlaff-Kraff (SRK) II, and Sanders-Retzlaff-Kraff T formulas.

General anesthesia was used in all patients. A clear corneal incision with a 3.2 mm bevel up was made in the superior, temporal, or superotemporal site according to patient's corneal steepening axis. An anterior capsulorhexis about 5.5 mm to 6 mm wide was made under viscoelastic material injection. Careful hydrodissection with a blunt needle and hydrodelineation of the lens nucleus was performed. Phacoemulsification was done using low-power ultrasound (40 %) and 80 mmHg vacuum or phaco aspiration because of the soft clear lens. The cortical and nuclear fragments were removed and aspirated with an irrigation/aspiration hand piece or bicanula and then posterior capsule cleaning was performed. At the end a posterior chamber one-piece acrylic Intra Ocular Lens (IOL) was implanted in the bag. After the viscoelastic material was removed, incision was checked for any leakage.

Data recorded for this study included patient demographic findings and each eye's axial length, preoperative and final BSCVA, preoperative and postoperative spherical equivalent (SE), previous argon laser treatment, use of Neodymium: Yttrium-Aluminum-Garnet (Nd: YAG) laser capsulotomy, complications such as retinal detachment, posterior capsule opacification, cystoid macular edema, persistent macular edema, endothelial cell loss, open angle glaucoma, endophthalmitis and follow-up time.

All statistical analysis was performed using SPSS software version 17 (SPSS Co, Chicago, IL). The

study was approved by the local ethics committee and informed consent for the CLE and IOL implantation was obtained from all patients before the surgery.

## Results

During the study period, CLE and posterior chamber IOL implantation was performed on 40 eyes from 29 patients. Patients' demographic data are shown in table 1, and their clinical data are presented in table 2. All participants had high myopia documented by an axial length of at least 26.10 mm (Figure 1) and by SE (Figure 2).

**Table 1: Demographic data of patients entering the study.**

No of patients	29
Bilateral cases	11
Unilateral cases	18
Sex	
Female	19
Male	10
Mean age (yrs)	6.14 ± 33.43 (range 48 - 23)

**Table 2: Clinical Findings related to patients entering the study.**

Variable	Mean ± SD	Range
Axial length (mm)		
OD	30.01 ± 2.14	26.10 to 33.50
OS	30.01 ± 1.65	27.21 to 33.46
Preoperative Spherical equivalent		
OD	- 18.73 ± 4.93	- 9 to - 28.5
OS	- 20.36 ± 5.73	- 11.5 to - 31
Preoperative BSCVA		
OD	0.18 ± 0.15	0.008 to 0.5
OS	0.24 ± 0.12	0.003 to 0.5
Power of IOL used		
OD	4.54 ± 2.80	1 to 11
OS	4.39 ± 3.13	0.5 to 12.5
Follow-up	0.21 ± 4.6	2 to 19
Preoperative argon laser therapy	1 eye (2.5 %)	

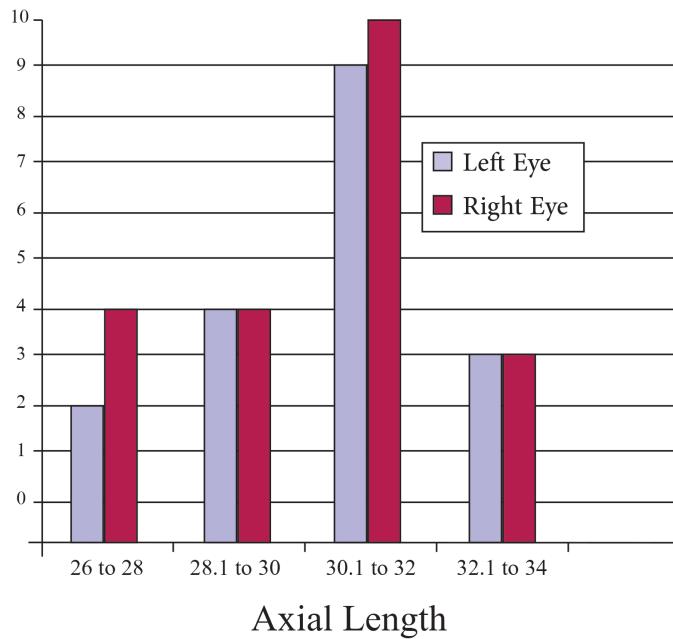
The mean preoperative SE was  $- 19.5 \pm 5.32$  (range - 9 to - 31) and the mean keratometry was  $44.026 \pm 1.839$  D (range 40 D to 46.5 D). The mean A-Scan axial length was  $30.109 \pm 1.903$  mm (Range 26.10 mm to 33.50 mm). The mean IOL power was  $4.465 \pm 2.928$  D (range 0.5 D to 12.5 D).

No serious intraoperative complications such as posterior capsule tear occurred and all IOLs were placed in the bag. The mean follow-up time was  $10.2 \pm 4.6$  months (range 2 to 19).

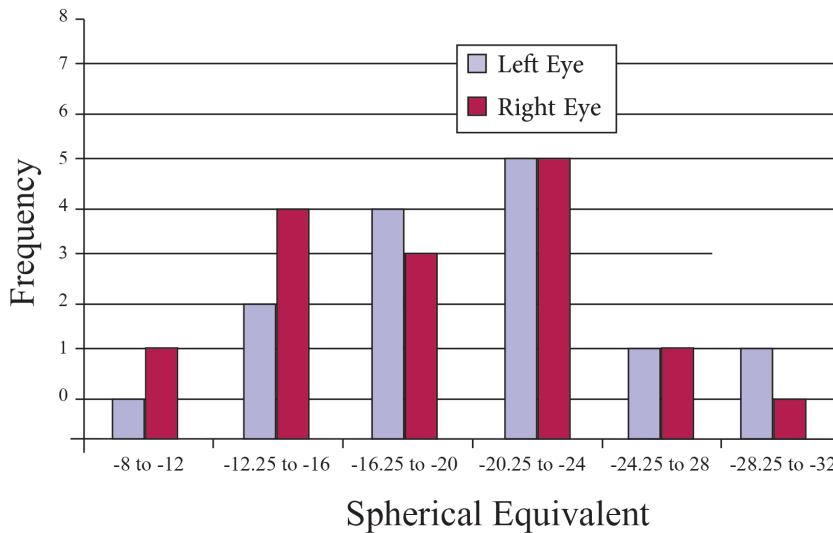
During the follow-up, one case (2.5 %) of posterior capsule opacification occurred at 18 months follow-up. This patient had a Neodymium: YAG (Nd: YAG) laser capsulotomy. The outcome visual acuity in this patient was 10/10 at the last follow-up examination. Preoperatively, the mean BCVA was  $0.217 + 0.138$  (range 0.003 to 0.5). In 3 cases, (7.5 %) the BCVA was 0.2 because of the preexisting myopic maculopathy. To verify the accuracy of biometric measurement, the final refraction deviation was calculated in relation to the targeted refraction. The mean postoperative SE was  $0.633 \pm 0.205$  (range 0.2 to 1) and the mean uncorrected visual acuity was  $0.541 \pm 0.238$  (range 0.1 to 1), improving in all eyes because of the myopia reduction. The mean refraction deviation from the targeted values was  $0.575 \pm 0.492$  (range 0 to 2) with a deviation of 3.00 D in 0 eyes, of 2.00 D in 1 eye (2.5 %), and of 1.50 D in 1 eye (2.5 %).

## Discussion

The correction of high myopia has attracted great interest for many years. At present, LASIK, LASEK, and PRK are the most frequently used techniques because of their good predictability and efficacy. However, the possibility of complications remains; for example, undercorrection, regression, and corneal haze can occur after PRK<sup>11</sup>, while complications of



**Figure 1: Distribution of axial length (mm); Mean: OD = 31.01, OS = 30.21; Standard deviation: OD = 2.14, OS = 1.65; N: OD = 21, OS = 19.**



**Figure 2: Preoperative spherical equivalent distribution: Mean OD = - 18.73, OS = - 20.36; Standard Deviation: OD: 4.93, OS = 5.73; N: OD = 21, OS = 19.**

the cut, corneal flap displacement, and intraepithelial cysts are sometimes encountered with-LASIK<sup>12,13</sup>. Complications increase in frequency with an increase in the severity of myopia to be corrected. These 3 surgical techniques appear to be unsuitable for the correction of high myopia especially over - 13.00 D.

Another option is phakic anterior chamber angle-supported or iris claw lens or phakic posterior chamber implantations, which offer well - defined advantages because of the simplicity, potential reversibility, precision, and stability of the refractive correction achieved<sup>14,15,16</sup>. The advantages of the phakic IOLs are more evident

in high myopia corrections in which excimer laser corrections are limited and hampered by problems with night vision regression, and poor optical quality of the reshaped cornea. However, the significant concern regarding this technique has been its potential for damage to the anterior chamber structures, especially corneal endothelial loss, pupil ovalization, chronic intraocular pressure elevation, and cataract formation.

Despite good refractive results and advances in surgical technique, retinal detachment remains a major concern after CLE for high myopia<sup>17,18</sup>. Barraquer et al.,<sup>3</sup> retrospectively analyzed the results of clear lens extraction performed with various surgical techniques (intra-capsular extraction and extra-capsular extraction without and with posterior chamber IOL implantation) in eyes with high myopia. During their follow-up, the RD rate was 7.5 %. Other authors have not observed RDs in eyes that had phacoemulsification with posterior chamber IOL implantation<sup>9</sup>. Similarly, we did not observe RDs in eyes that had phacoemulsification with posterior chamber IOL implantation. The difference in the RD incidence among various authors who used the same surgical technique of lens removal in highly myopic eyes could be caused by the small number of cases studied. It could also be due to the fact that in younger patients the vitreous is sometimes detached from the retina resulting in less stress on the retina from the vitreous after lens removal.

In this series, we report the outcomes of patients previously undergoing clear lens extraction in our center. Among our cases, where possible, we used Morcher IOLs which are easy to insert through the capsulorhexis. At the time of surgery these lenses were probably one of the best options in the low-power dioptric range suitable for myopic eyes.

In our study, the mean biometric error was 0.575

$\pm 0.492$  (range 0 to 2). This error represents the difference between the obtained refractive result and the targeted refraction. The refractive results were encouraging and compared favorably with those of corneal reshaping techniques in both predictability and stability. In our series, one eye (2.5 %) developed a refractive error greater than 1.5 D probably because of biometric error and the inadequate formula (SRK II) used, as other authors have suggested<sup>19</sup>. Finally no eye had a decrease in BCVA; and many eyes showed some improvement.

### Conclusion

Previous use of clear lens extraction with posterior chamber IOL implantation for treatment of high myopic eyes, in our setting, showed good outcomes with acceptable predictability, improvement in best corrected visual acuity and low rate of complications.

## References

1. Goldberg MF. Clear lens extraction for axial myopia. An appraisal. *Ophthalmology*. 1987;94(5):571-82.
2. Colin J, Robinet A. Clear lensectomy and implantation of low-power posterior chamber intraocular lens for the correction of high myopia. *Ophthalmology*. 1994;101(1):107-12.
3. Barraquer C, Cavellier C, Mejía LF. Incidence of retinal detachment following clear-lens extraction in myopic patients. Retrospective analysis. *Arch Ophthalmol*. 1994;112(3):336-9.
4. Fan DS, Lam DS, Li KK. Retinal complications after cataract extraction in patients with high myopia. *Ophthalmology*. 1999;106(4):688-91.
5. Jiménez-Alfaro I, Miguélez S, Bueno JL, Puy P. Clear lens extraction and implantation of negative-power posterior chamber intraocular lenses to correct extreme myopia. *J Cataract Refract Surg*. 1998;24(10):1310-6.
6. Batman C, Cekiç O. Clear lensectomy and implantation of IOL for high myopia. *Ophthalmology*. 1998;105(6):944-5.
7. Chastang P, Ruellan YM, Rozenbaum JP, Besson D, Hamard H. Phacoemulsification for visual refraction on the clear lens. Apropos of 33 severely myopic eyes. *J Fr Ophtalmol*. 1998;21(8):560-6. (Article in French)
8. Gris O, Güell JL, Manero F, Müller A. Clear lens extraction to correct high myopia. *J Cataract Refract Surg*. 1996;22(6):686-9.
9. Lyle WA, Jin GJ. Phacoemulsification with intraocular lens implantation in high myopia. *J Cataract Refract Surg*. 1996;22(2):238-42.
10. Colin J, Robinet A. Clear lensectomy and implantation of low-power posterior chamber intraocular lens for the correction of high myopia. *Ophthalmology*. 1994;101(1):107-12.
11. Seiler T, Derse M, Pham T. Repeated excimer laser treatment after photorefractive keratectomy. *Arch Ophthalmol*. 1992;110(9):1230-3.
12. Güell JL, Muller A. Laser in situ keratomileusis (LASIK) for myopia from -7 to -18 diopters. *J Refract Surg*. 1996;12(2):222-8.
13. Stulting RD, Carr JD, Thompson KP, Waring GO 3rd, Wiley WM, Walker JG. Complications of laser in situ keratomileusis for the correction of myopia. *Ophthalmology*. 1999;106(1):13-20.
14. Fechner PU, Haubitz I, Wichmann W, Wulff K. Worst-Fechner biconcave minus power phakic iris-claw lens. *J Refract Surg*. 1999;15(2):93-105.
15. Alió JL, de la Hoz F, Pérez-Santonja JJ, Ruiz-Moreno JM, Quesada JA. Phakic anterior chamber lenses for the correction of myopia: a 7-year cumulative analysis of complications in 263 cases. *Ophthalmology*. 1999;106(3):458-66.
16. Arne JL, Lesueur LC. Phakic posterior chamber lenses for high myopia: functional and anatomical outcomes. *J Cataract Refract Surg*. 2000;26(3):369-74.
17. Colin J, Robinet A, Cochener B. Retinal detachment after clear lens extraction for high myopia: seven-year follow-up. *Ophthalmology*. 1999;106(12):2281-4.
18. Arne JL. Phakic intraocular lens implantation versus clear lens extraction in highly myopic eyes of 30- to 50-year-old patients. *J Cataract Refract Surg*. 2004;30(10):2092-6.
19. Yalvaç IS, Nurözler A, Unlü N, Cetinkaya F, Kasim R, Duman S. Calculation of intraocular lens power with the SRK II formula for axial high myopia. *Eur J Ophthalmol*. 1996;6(4):375-8.

## Footnotes and Financial Disclosures

### Conflict of Interest:

The authors declare no conflict of interest with the subject matter of the present manuscript.