

## Case Report

# Epibulbar Dermoid Cyst in a Patient with VACTERL Association

Nader Nassiri <sup>1</sup>, MD; Mohammad Hasan Seifi <sup>1</sup>, MD; Mahsan Assadi <sup>\*1</sup>, MD; Hossein Mohammad Rabei <sup>1</sup>, MD; Kourosh Sheibani <sup>2</sup>, MD, MS

1. Ophthalmic Research Center, Shahid Beheshti University of Medical Science, Tehran, Iran.

2. Basir Eye Health Research Center, Basir Eye Clinic, Tehran, Iran.

**\*Corresponding Author:** Mahsan Assadi

**E-mail:** msassadi16@yahoo.com

### Article Notes:

Received: May. 9, 2016

Received in revised form: Jun. 3, 2016

Accepted: Jun. 23, 2016

Available Online: Sept. 24, 2016

### Keywords:

VACTERL association

Dermoid cyst

Goldenhar syndrome

### Abstract

The VACTERL association is an association of multiple congenital malformations such as vertebral defects, anal atresia, cardiac defects, tracheo-esophageal fistula, renal anomalies, and limb abnormalities, in which the rate and number of the characteristic anomalies varies according to the population. We present a case of VACTERL association who was referred with a nodular dermoid cyst in her left eye since birth.

Dermoid cysts as a part of Goldenhar's syndrome and the VACTERL association have been reported very rarely; however there have been a few reports of children having the VACTERL association and orbital dermoid. This shows the possibility of finding orbital dermoid cysts in the context of VACTERL association and demonstrates that such cysts could be a surrogate for feasible diagnosis of VACTERL association. Nonetheless, additional findings of an ipsilateral orbital dermoid cyst should stimulate serious discussion concerning the pathophysiology and etiology of this complex disorder.

**How to cite this article:** Nassiri N, Seifi MH, Assadi M, Mohammad Rabei H, Sheibani K. Epibulbar Dermoid Cyst in a Patient with VACTERL Association. *Journal of Ophthalmic and Optometric Sciences*. 2016;1(1):27-31.

## Introduction

The VACTERL or VATER association is characteristically described by the presence of at least three of the following congenital malformations: vertebral anomalies, anal atresia, cardiovascular anomalies, tracheoesophageal fistula, renal and/or radial anomalies and limb abnormalities<sup>(1)</sup>. There are a wide range of manifestations for VACTERL association so that the exact incidence within the population is not known<sup>(2)</sup>.

The difference between the acronyms VACTERL and VATER is due to the variation in defects determined at or prior to birth. VACTERL contains vertebral, anal, cardiac, tracheoesophageal, renal, and limb defects, where as VATER only has vertebral, anal, tracheoesophageal, and renal defects<sup>(3)</sup>. In addition, these patients may have other congenital disorders, such as genital anomalies, a single umbilical artery and thumb defects<sup>(4)</sup>. The incidence is approximately 1 in 10,000 to 1 in 40,000 live births<sup>(2,4)</sup>.

VACTERL association can be linked to other similar conditions such as Klippel Feil and Goldenhar syndrome including crossover of conditions. Even though a child may have some of these conditions they must have all of the letters that form the acronym to be diagnosed with the full phenotype<sup>(5)</sup>. Most cases of VACTERL association are sporadic, but the disease may occur with some chromosome defects such as Trisomy 18 (Edwards syndrome), or in children of mothers with diabetes, but its exact cause is not known<sup>(3,6)</sup>.

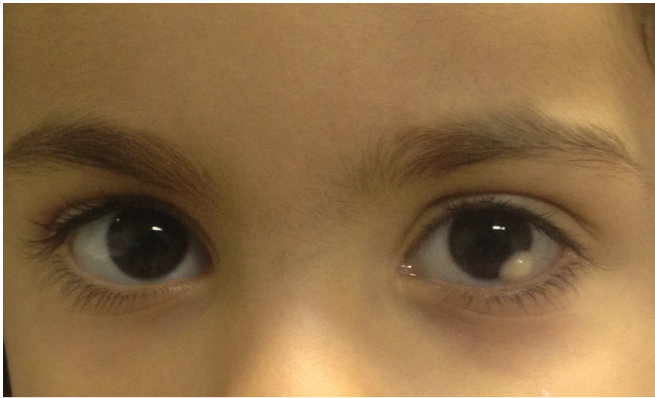In this report, we present a 4-year-old girl with an epibulbar dermoid cyst, which was in association with the VACTERL syndrome. To our knowledge there has been no report in the literature of a child having VACTERL association and orbital dermoids in English literature.

## Case Report

A 4-year-old female child with a white, soft and non tender mass in the inferotemporal region of the left eye since birth was referred for ophthalmologic examination. She had no history of orbital trauma. There was a history of cardiac and genitourinary surgery in early life.

She was the first child and there was no family history of congenital anomalies. She was born at term with normal delivery following an uneventful pregnancy. After birth she was noted to have an imperforate anus, with a rectovaginal fistula. She had heart murmur, and a subsequent echocardiography confirmed perimembranous atrial septal defect (ASD). An X-ray of her spine revealed vertebral scoliosis; also in urinary system evaluation she had horseshoe kidneys. She was diagnosed with VACTERL syndrome and had surgical correction of her imperforate anus and rectovaginal fistula and cardiac anomaly within the first few days of life.

At presentation the patient was healthy and alert. On ocular examination, the visual acuity with full cycloplegia was 9/10 in the right eye with a correction of + 0.75 - 0.25 × 180 and 7/10 in the left eye with a correction of + 1- 0.75 × 180. In external examination she was orthophoric and ocular movements were normal in all gazes. In slit lamp examination the anterior segment of the right eye and dilated posterior fundus examination of both eyes were completely normal. Anterior segment examination of the left eye revealed a solid circumscribed mass, porcelain white, non mobile and nodular which was located in inferotemporal area of the limbus (Figure 1).



**Figure 1:** An image of the epibulbar dermoid cyst in inferotemporal area of the left eye limbus in a 4-year-old girl with VACTERL association.

The mass was  $6 \times 4 \times 18$  mm in diameter. The examination of the anterior chamber, lens and iris of the left eye was unremarkable. The patient underwent surgical excision of the lesion and the pathological findings were consistent with epibulbar dermoid cyst (Figure 2).

### Discussion

Orbital dermoid cysts are developmental choristomas (an abnormal arrangement of tissues not normally present at the site), and are often obvious soon after birth, due to parental concern about a periocular lump, or an asymmetry of the eyelids or brows<sup>(1)</sup>.

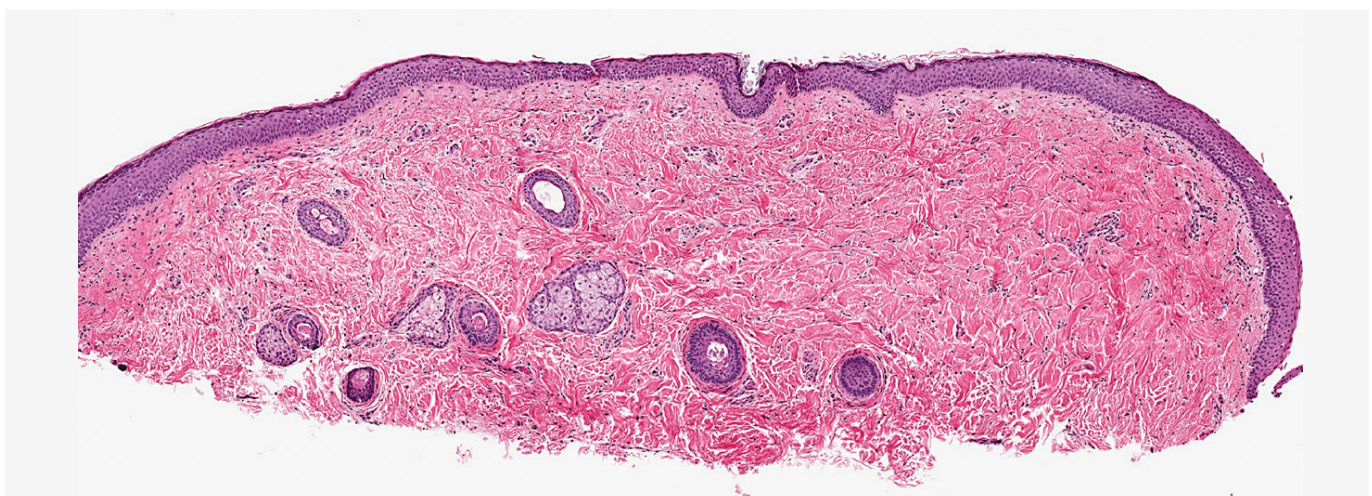
In rare situations, the cyst may be asymptomatic until it presents with obvious enlargement or with

inflammatory symptoms, such as pain, redness, and eyelid swelling<sup>(7-9)</sup>. They are common in children, developing next to the suture lines, most commonly located at the anterolateral frontozygomatic suture, and are rarely progressive<sup>(10)</sup>. In a strict sense, epibulbar dermoids are delineated as congenital alterations of mesodermal and ectodermal origin<sup>(10)</sup>.

They are typically located at the limbus of the cornea in the inferotemporal quadrant; and are only rarely seen in the more central regions of the cornea<sup>(10)</sup>. The intraocular structures are seldom involved<sup>(11)</sup>. Characteristically, solid limbal dermoids are excised at pre-school ages, unless a high irregular astigmatism and its risk for amblyopia lead to an earlier intervention<sup>(12)</sup>.

The communication of these lesions with the central nervous system is less common and is observed in the nasal region.

There are few clinical reports of temporal dermoid cysts presenting with intracranial extensions<sup>(13)</sup>. A 15-year-old girl with a fronto-orbital dermoid cyst with intracranial extension and bone erosion has previously been reported. Her presenting symptom was decreased lacrimation in the left eye<sup>(13)</sup>.



**Figure 2:** The pathology of the excised epibulbar lesion, which was consistent with limbal dermoid.

In general, the features observed with the VACTERL association include: vertebral anomalies (about 80 %), anal atresia (about 55 %), cardiovascular anomalies (up to 75 %), tracheoesophageal fistula (33 %), renal and/or radial anomalies (about 50 %), and limb defects (70 %). Other findings include genital anomalies, a single umbilical artery, and thumb defects <sup>(4, 14, 15)</sup>. It is not completely agreed upon whether VACTERL should be defined by at least two or three component defects, and it is classically defined by the existence of at least three of the above congenital malformations <sup>(6, 16)</sup>. Furthermore, an overlap between the VACTERL association and Goldenhar's syndrome, accompanied with other conditions, has previously been described as the axial mesodermal dysplasia spectrum. The oculo-auriculo-vertebral spectrum (OAVS) or Goldenhar's syndrome is a spectrum of congenital anomalies that involves structures arising from the first and second branchial arches <sup>(17)</sup>. It is defined by a wide spectrum of symptoms and signs. These abnormalities mostly involve the cheekbones, jaws, mouth, ears, eyes, or vertebrae <sup>(16, 17)</sup>. Other conditions with ear and/or radial involvement, such as Nager syndrome, Holt-Oram syndrome, radial-renal syndrome, facio-auriculo-radial dysplasia, and Fanconi anemia, should be considered for differential diagnosis <sup>(17, 18)</sup>. Dermoid cysts and ipsilateral defects in the VACTERL association have also been reported <sup>(1)</sup>. However, there are limited reports in English literature of children having the VATER association and orbital dermoids. A 10 month -old black female with dermoid cysts and VACTERL association has been previously reported. She had VACTERL symptoms including scoliosis, left renal disorder,

imperforated anus, rectovaginal fistula, and absence of the left umbilical artery. The patient in addition to VACTERL syndrome had dermoid cyst located on the temporal aspect of the left orbit in the area overlying the zygomaticofrontal suture <sup>(1)</sup>.

Our case had heart symptoms in addition to other symptom of VACTERL syndrome but dermoid cyst in our case was located in inferotemporal area of the limbus. Nonetheless, additional findings of an ipsilateral orbital dermoid cyst should stimulate serious discussion concerning the pathophysiology and etiology of this complex disorder.

### Conclusion

To our knowledge there have been very few reports of children having the VACTERL association and orbital dermoids in English literature. Nonetheless, additional findings of ipsilateral orbital dermoid cysts should stimulate serious discussion concerning the pathophysiology and etiology of this complex disorder.

## References

1. DeRespinis PA, Napolitano JD. Dermoid Cyst and Ipsilateral Defects in VATER Association. *Clin Pediatr (Phila)*. 1992;31(3):184-6.
2. Solomon BD. VACTERL/VATER Association. *Orphanet J Rare Dis*. 2011;16;6:56.
3. Botto LD, Khoury MJ, Mastroiacovo P, CastillaEE, Moore CA, Skjaerven R, et al. The spectrum of congenital anomalies of the VATER association: an international study. *1997;71(1):8-15*.
4. Weaver DD, Mapstone CL, Yu PL. The VATER association. Analysis of 46 patients. *Am J Dis Child*. 1986;140(3):225-9.
5. Reece EA, Hobbins JC. Fetal skeletal anomalies ;*Clinical Obstetrics: The Fetus and Mother*, Chapter 26;2008:446.
6. Aynaci FM, Celep F, Karaguzel A, Baki A, Yildiran A. A case of VATER association associated with 9qh+. *Genet Couns* 1996; 7(4):321-2.
7. Pollard ZF, Harley RD, Calhoun J. Dermoid cysts in children. *Pediatrics*. 1976;57(3):379-82.
8. Shields JA, Bakewell B, Augsburger JJ, Donoso LA, Bernardino V. Space-occupying orbital masses in children. A review of 250 consecutive biopsies. *Ophthalmology*. 1986;93(3):379-84.
9. Sherman RP, Rootman J, Lapointe JS. Orbital dermoids: clinical presentation and management. *Br J Ophthalmol*. 1984;68(9):642-52.
10. Ahuja R, Azar NF. Orbital dermoids in children. *Semin Ophthalmol*. 2006;21(3):207-11.
11. Sommer F, Pillunat LE. Epibulbar dermoids--clinical features and therapeutic method. *Klin Monbl Augenheilkd*. 2004;221(10):872-7. (Article in German)
12. Lang PJ, Seitz B, Naumann GO. Solid limbal dermoid in an 80-year-old patient. *Klin Monbl Augenheilkd*. 2004;221(9):776-80. (Article in German)
13. Rinna C, Reale G, Calafati V, Calvani F, Ungari C. Dermoid cyst: unusual localization. *J Craniofac Surg* 2012;23(5):e392-4.
14. Gigante J. *First Exposure to Pediatrics*. New York: McGraw-Hill, Medical Pub. Division. 2006: p. 351.
15. Shaw-Smith C. Oesophageal atresia, tracheo-oesophageal fistula, and the VACTERL association: review of genetics and epidemiology. *J Med Genet*. 2006;43(7):545-54.
16. Rittler M, Paz JE, Castilla EE. VACTERL association, epidemiologic definition and delineation. *Am J Med Genet* 1996;63(4):529-36.
17. Vendramini S, Richieri-Costa A, Guion-Almeida ML. Oculoauriculovertebral spectrum with radial defects: A new syndrome or an extension of the oculoauriculovertebral spectrum? Report of fourteen Brazilian cases and review of the literature. *Eur J Hum Genet*. 2007;15(4):411-21.
18. Taksande A, Vilhekar K. Oculoauriculovertebral Spectrum with Radial Anomaly in Child. *J Family Med Prim Care*. 2013;2(1):92-4.

## Footnotes and Financial Disclosures

### Conflict of Interest:

The authors declare no conflict of interest with the subject matter of the present manuscript.