

Extradural Thoracic Arachnoid Cyst En-Bloc Resection and Follow-Up: A Case Report

Afsoun Seddighi, Amir Nikouei, Amir Saied Seddighi, Mohammad Asadpour, Noushin Masoudian, Afshin Samaei

Shohada Tajrish Comprehensive Neurosurgical Center of Excellence, Shahid Beheshti University of Medical Sciences, Tehran, Iran

ABSTRACT

Background: Arachnoid cysts are cerebrospinal fluid (CSF) fluid-filled sacs that are located between the brain and spinal cord. Spinal column arachnoid cysts are rare and mostly asymptomatic, being mostly located in intradural regions. We reported a patient who presented with neurological deficits and mid-thoracic extradural arachnoid cyst treated with en-bloc resection.

Case Presentation: Patient was a 34-year-old female who presented with progressive back pain, lower extremity weakness and paresthesia in her lower limbs. Magnetic resonance imaging (MRI) study revealed an extradural hyperintense signal lesion in T2-weighted, extending from T7 to T9, which did not enhance on T1-weighted post-contrast MRI. Patient underwent T6-T10 laminectomy and en-bloc resection of the lesion which was compatible with arachnoid cyst after histopathological examination. Patient did not experience worsening of neurological symptoms and lesion recurrence in clinical and imaging evaluation during 2-year follow-up.

Conclusion: Clinical and neuroimaging evaluation of every patient with progressive neurological deficits should be carried out in detail. This report suggests that rare spinal lesion, as extradural spinal arachnoid cyst in this case, may cause neurologic deficits and en-bloc resection of the lesion is feasible and may prevent local recurrence.

Keywords: Spinal Arachnoid Cyst; Extradural; Laminectomy; En-bloc Resection

ICNSJ 2017; 4 (1) :33-36

www.journals.sbmu.ac.ir/neuroscience

Correspondence to: Amir Saied Seddighi, MD, Functional Neurosurgery Research Center, Shohada Tajrish Hospital, Shahid Beheshti University of Medical Sciences, Tehran, Iran; Mobile: +98(912)21551591; E-mail: a_seddighi@sbmu.ac.ir

Received: January 3, 2017

Accepted: February 12, 2017

INTRODUCTION

Arachnoid cysts are cerebrospinal fluid (CSF) fluid-filled sacs that are located between the brain or spinal cord and the arachnoid membrane and are a common incidental finding on routine brain imaging¹. Congenital arachnoid cysts are associated with several neural tube defects such as spina bifida occulta and diastematomyelia². The cells in the cyst wall are composed primarily of simple connective tissue and many completely lack an inner arachnoid lining. These cysts act as a unidirectional valve that let fluid in but not out. Distribution of arachnoid trabeculae leads to fluid shifts within the cyst, thereby causing an increase in size³. Clinical manifestations of

arachnoid cysts are mainly depended on their location, ranging from simple headache to severe ataxia when located in intracranial fossa, and variable degrees of hyposthesia and radicular pain to neurological deficits and paresis⁴. However, arachnoid cysts in spinal column are still rare and asymptomatic and may be detected in incidental neuroimaging. Authors report a patient with a large extradural arachnoid cyst in mid-thoracic spinal column causing neurological deficits.

CASE PRESENTATION

The patient was a 34-year-old female who presented with progressive back pain, weakness of lower extremities

and paresthesia in lower limbs which has been initiated from 6 months ago. Patient did not mention any associated neurological symptoms or definite neurological diseases in her siblings or first degree family members. Also, patient has not been exposed to regional radiotherapy or neurosurgical procedures, trauma, lumbar puncture and localized infection in her spinal column. Physical examination revealed a symmetric sensory level at T6 territory, paraparesis, lower extremity hyperreflexia

(3+) and bilateral extensor plantar reflex. Plain anterior-posterior and lateral radiography of thoraco-lumbar spine was taken from the patient (Figure 1).

Also, patient underwent brain and whole spine magnetic resonance imaging (MRI) and a large extradural lesion was noted. The lesion was a cystic lesion extending from T7 to T9 with hyper intense signal on T2-weighted MRI accompanied by a central area with hypo intense signal on same imaging modality (Figure 1-A). Furthermore,

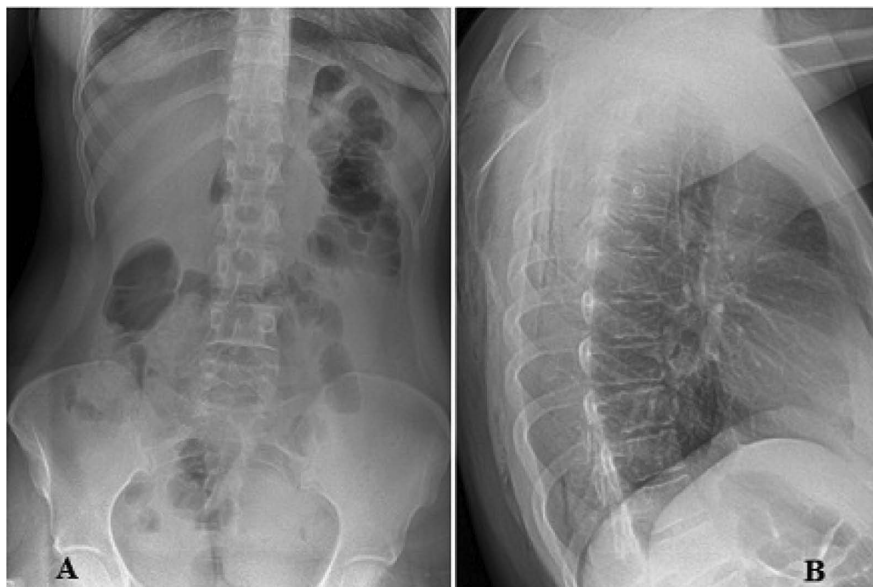


Figure 1. Plain radiography of thoraco-lumbar spine from anterior-posterior (A) and lateral view (B).

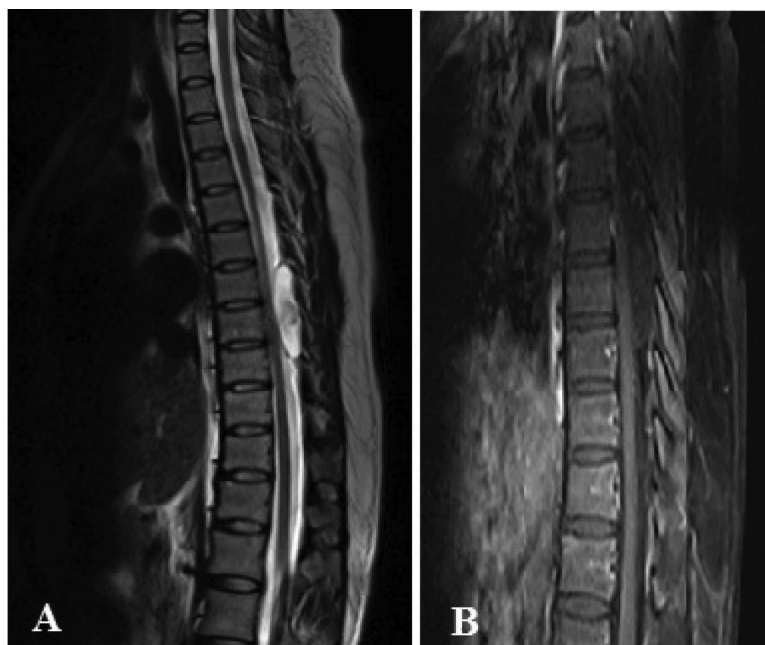


Figure 2. Pre-operative spinal MRI shows a cystic lesion extending from T7 to T9 with hyper intense signal on T2-weighted MRI accompanied by a central hypo intense signal (A). Pre-operative contrast enhanced T1-weighted MRI shows non-enhancing hypo intense lesion extending from T7 to T9, with signal intensity similar to cerebrospinal fluid (B).

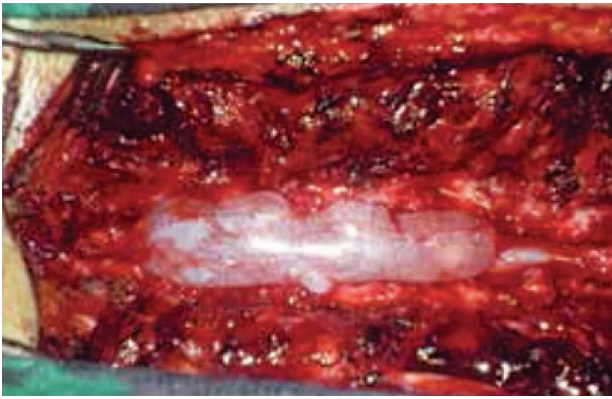


Figure 3. Intra-operative view of the lesion following laminectomy. Note the bright fluid filled sac.

MRI with contrast enhancement was performed, which showed non-enhancing hypo intense lesion in T1-weighted imaging (Figure 1-B).

Brain MRI study did not reveal any signs of hydrocephalus or lesions. Based on patient's clinical manifestation and its progressive nature, neurosurgeons plan to perform T6 to T10 laminectomy and en-bloc resection of the lesion.

After successful en-bloc resection, lesion was sent for histopathological study. Histopathological examination revealed collagen and meningothelial cells in lining epithelium, splitting of arachnoid cyst in its margin and forms a cyst which contains colorless fluid resembling CSF. Based on clinical presentation, neuroimaging and post-operative histopathological examination, diagnosis of an extradural arachnoid cyst in thoracic spine has been confirmed. Authors set a regular clinical and neuroimaging assessment in post-operative period with 3 to 6-month interval. No local lesion recurrence or enlargement of possible residue or worsening of neurological deficits was observed in neuroimaging and clinical assessment during 2-year post-operative follow up.

DISCUSSION

Spinal arachnoid cysts are CSF filled cavities within protrusions of arachnoid membrane that may involve extraural, intradural and mixed extra-intraural locations and have been found in all age groups and have a slight female preponderance⁵. These cysts mostly found in intracranial fossa and represent about 1% of all non-traumatic intracranial masses. More than 50% of intracranial arachnoid cysts are found in middle cranial fossa and are supratentorial. Mentioned lesions may less frequently affect suprasellar and quadrigeminal cisterns, followed by cerebellopontine angle and cisterna magna⁶. Less frequently, spinal arachnoid cysts are mainly found

posterior to the spinal cord, in mid and lower thoracic levels followed by thoracolumbar and lumbosacral regions⁷.

The vast majority of these lesions are asymptomatic, but they may complicate with post-traumatic or spontaneous hemorrhage within the cyst and may cause neurological deficit in severe conditions which results in cord compression. In addition to the congenital, traumatic and inflammatory origins which have been hypothesized, pulsatile CSF dynamics and osmotic gradient between subarachnoid space and cyst may have role in cyst formation⁸. In addition, familial basis has been identified, as these cysts were present in 2nd and 3rd siblings in few reports. Moreover, mutation in *FOXC2* has been identified as a cause of this disorder⁹.

Differential diagnosis of arachnoid cyst includes dermoid and epidermoid cysts, cystic neoplasms, parasitic cysts, cysticercosis, hydatid cysts and tarlov cyst. Arachnoid cysts are classified into extradural and intradural based on their location to the dura matter. Extradural cysts are out pouchings of arachnoid that are contiguous with subarachnoid space via a small dural defect that may be visible and accounts for about 1% of primary tumors of the spinal cord and have slight male predominance and mostly affect patients in their second decade. These cysts are uncommon and rarely become symptomatic. However, intradural arachnoid cysts are more common than previous described lesions and mostly found in thoracic region and may be associated with vertebral anomalies, neural tube defects, syringomyelia and post-traumatic accidents¹⁰.

MRI is the most sensitive and specific imaging modality for assessing arachnoid cyst extension. The signal intensity of arachnoid cyst is as same as CSF in both T1 and T2-weighted MRI. Sometimes, slight hyperintense foci in the cyst is observed on T2-weighted imaging, which is related to increased protein content of sequestered fluid or absence of motion effects. In addition, diffusion weighted MRI helps to distinguish arachnoid cyst features from epidermoid cyst, abscess and tumor, as well as assessment of possible spinal atrophy¹¹. Kinematic MRI (cine-MRI) is widely available and can help evaluate for the presence of communications between the cyst and the subarachnoid space¹².

Treatment includes observation which is suitable for asymptomatic cysts. No correlation exists between the size of a cyst and the need for treatment and annual neuroimaging should be done to detect any new abnormality and determine whether the cyst is truly benign. Another approach is cyst aspiration which is

not routinely advised and may temporarily improve symptoms. Besides, cyst aspiration under fluoroscopic guidance may be appropriate for determining whether a cyst is causing a patient's symptoms and thereby predicting whether surgery can help^{13,14}. However, surgery with en-bloc resection of the lesion is the ideal treatment. Dorsal cysts are usually excised through laminectomy, while ventrolateral cysts require posterior approach with dentate ligament section. Unresectable arachnoid cysts may require fenestration of the cyst wall, percutaneous drainage and cystoperitoneal shunting. Latter approach will fail as a primary treatment modality and it is advised for patients with recurrence of previously treated arachnoid cyst¹⁵.

Our presented case underwent T6 to T10 laminectomy and en-bloc resection of the lesion, with no lesion recurrence and symptom progression in 2-year follow-up. Correlation of clinical manifestation with the defect which is cause by spinal arachnoid cyst is the best predictor of recovery in patients who are candidates for surgical procedures.

REFERENCES

- Dahlgren RM, Baron EM, Vaccaro AR. Pathophysiology, diagnosis, and treatment of spinal meningoceles and arachnoid cysts. *Seminars in Spine Surgery*. 2006;18(3):148-153.
- Apel K, Sgouros S. Extradural spinal arachnoid cysts associated with spina bifida occulta. *Acta Neurochir*. 2006;148(2):221-6.
- Wang MY, Levi AD, Green BA. Intradural spinal arachnoid cysts in adults. *Surg Neurol*. 2003;60(1):49-55.
- Petridis AK, Doukas A, Barth H, Mehdorn HM. Spinal cord compression caused by idiopathic intradural arachnoid cysts of the spine: review of the literature and illustrated case. *Eur Spine J*. 2010;19 Suppl 2:S124-9.
- Raja IA, Hankinson J. Congenital spinal arachnoid cysts; report of two cases and review of the literature. *J Neurol Neurosurg Psychiatry*. 1970;33(1):105-10.
- Donaldson JW, Edwards-Brown M, Luerssen TG. Arachnoid cyst rupture with concurrent subdural hygroma. *Pediatr Neurosurg*. 2000;32(3):137-9.
- Liu JK, Cole CD, Kan P, Schmidt MH. Spinal extradural arachnoid cysts: clinical, radiological, and surgical features. *Neurosurg focus*. 2007;22(2):1-5.
- Mehta S, Dharmarajan S, Brzozowski M, Trojanowski T. Spinal arachnoid cysts—a report of two cases and a review of the literature. *Journal of Pre-Clinical and Clinical Research*. 2010;4(1).
- Kanaan IN, Sakati N, Otaibi F. Type I congenital multiple intraspinal extradural cysts associated with distichiasis and lymphedema syndrome. *Surg neurol*. 2006;65(2):162-6.
- Kumar K, Malik S, Schulte PA. Symptomatic spinal arachnoid cysts: report of two cases with review of the literature. *Spine*. 2003;28(2):E25-9.
- Jain SK, Sundar IV, Sharma V, Goel RS. Lumbosacral arachnoid cyst with tethered cord: A rare case report. *J Craniovertebr Junction Spine*. 2012;3(2):73.
- Doita M, Nishida K, Miura J, Takada T, Kurosaka M, Fujii M. Kinematic magnetic resonance imaging of a thoracic spinal extradural arachnoid cyst: an alternative suggestion for exacerbation of symptoms during straining. *Spine*. 2003;28(12):E229-33.
- Hughes GW, Ugokwe KE, Benzel EC. A review of spinal arachnoid cysts. *Cleve Clin J Med*. 2008;75(4):311-5.
- Nikouei A, Seddighi A, Seddighi AS. The Results of Image Guided Surgery Using Neuronavigation in Resection of Cerebral Gliomas in Eloquent Cortical Areas. *Arch Phys Med Rehabil*. 2016;97(10):e69-70.
- Jensen F, Knudsen V, Troelsen S. Recurrent intraspinal arachnoid cyst treated with a shunt procedure. *Acta Neurochir*. 1977;39(1-2):127-9.