

## ORIGINAL RESEARCH

# Screening Performance of Ultrasonographic B-lines in Detection of Lung Contusion following Blunt Trauma; a Diagnostic Accuracy Study

Saeed Abbasi<sup>1</sup>, Hossein Shaker<sup>1</sup>, Fariba Zareiee<sup>1</sup>, Davood Farsi<sup>1</sup>, Peyman Hafezimoghadam<sup>1</sup>, Mahdi Rezaei<sup>1</sup>, Babak Mahshidfar<sup>1</sup>, Mani Mofidi<sup>1\*</sup>

1. Emergency medicine management research center, Iran University of Medical Sciences, Rasoul Akram Hospital, Tehran, Iran.

Received: March 2018; Accepted: August 2018; Published online: 2 September 2018

**Abstract:** **Introduction:** Chest ultrasonography is routinely used in evaluation of chest trauma for diagnosis of pulmonary injury. This study aimed to evaluate the accuracy of B-Lines for diagnosing lung contusion in patients with blunt trauma of the chest. **Methods:** Trauma patients who met the inclusion criteria were enrolled in the study and underwent ultrasonography by trained emergency medicine residents. Ultrasound results were recorded in terms of number of B-lines and the existence of peripheral parenchymal lesion (PPL). After ultrasound, the patient underwent chest x-ray and chest CT scan (as reference test) and screening performance of B-lines and PPL were evaluated. **Results:** 147 patients underwent chest ultrasound. The mean age of the patients was  $40.74 \pm 18.6$  (78.9% male). B-lines>3 had 94.0% (95% CI: 83.45-98.75) sensitivity and 57.7% (95% CI: 47.3-67.7) specificity, B-lines>6 had 90.0% (95% CI: 78.2-96.7) sensitivity and 93.81% (95% CI: 87.0-97.7) specificity, and PPL had 34.0% (95% CI: 21.2-48.8) sensitivity and 100% (95% CI: 96.3-100.0) specificity. Composite findings of B-lines>6 + PPL had 92.0% (95% CI: 80.8-97.8) sensitivity and 93.8% (95% CI: 87.0-97.7) specificity in the diagnosis of lung contusion. **Conclusion:** PPL and B-Lines>6 had the highest accuracy in detecting lung contusion. B-Line>6 had high sensitivity and specificity and was easy to perform; thus, it seems that B-Line>6 could be considered as an alternative screening tool in detection of lung contusion.

**Keywords:** Diagnosis; emergency service, hospital; diagnostic imaging; ultrasonography; thoracic injuries

© Copyright (2018) Shahid Beheshti University of Medical Sciences

**Cite this article as:** Abbasi S, Shaker H, Zareiee F, Farsi D, Hafezimoghadam P, Rezaei M, Mahshidfar B, Mofidi M. Screening Performance of Ultrasonographic B-lines in Detection of Lung Contusion following Blunt Trauma; a Diagnostic Accuracy Study. *Compr J Emerg Med.* 2018; 6(1): e55.

## 1. Introduction

Chest trauma and its complications are responsible for about 25% of deaths due to blunt trauma. Lung contusion is a common complication of blunt chest trauma as it happens in 30 to 75% of the cases (1). Lung contusion is an independent risk factor of acute respiratory distress syndrome (ARDS), pneumonia, long-term respiratory failure and is associated with 10 to 25% mortality rate (2-4). Early and accurate diagnosis and proper management of pulmonary contusion in emergency department have a significant influence on morbidity and mortality of these patients (3). In the beginning,

Chest Radiography (CXR) is traditionally done to diagnose probable lung contusion, but identification of opacity and its size needs time and generally takes 6 to 48 hours, so lung contusion usually can't be diagnosed in the early phase via CXR (4, 5). Chest Computed Tomography (CT) scan is more sensitive than CXR and is considered as the gold standard technique for detecting lung contusion (6). Chest CT scan reveals the exact distribution and size of pulmonary injury (7). Lung ultrasound is increasingly used as standard trauma care in emergency departments (ED). It can detect alveolar consolidations, interstitial syndrome, pulmonary embolisms and pneumothorax (8). Prompt and accurate bedside detection of thoracic disorders is its advantage compared to other diagnostic modalities (9). Ultrasound is a method with high precision for detecting interstitial edema, which is used in diagnosis of lung contusion based on local interstitial edema

\*Corresponding Author: Mani Mofidi; Emergency medicine management research center, Rasoul Akram Hospital, Tehran, Iran. Email: mani-mofidi@yahoo.com Tel: 00989122263218



due to trauma. Two studies conducted by Soldati and Shadia found that chest ultrasonography had a high sensitivity and precision in diagnosis of lung contusion in patients with blunt trauma (10, 11). B-lines are the important finding in chest sonography of lung contusion, but the number of B-lines that can be used to diagnose is not known. One study believed that less than 3 B-lines could be seen in an uninjured lung (9) and the other one stated the lung ultrasound would be normal in presence of less than 6 B lines (10). A recent meta-analysis study has shown ultrasonography is a preferred screening modality in detection of pulmonary contusion compared to chest radiography, but the eligible studies didn't mention the number of B-lines that indicated pulmonary contusion (12). The aim of this study was to evaluate the accuracy of B-Line in diagnosing of lung contusion in patients with blunt trauma to the chest.

## 2. Methods

### 2.1. Study design and setting

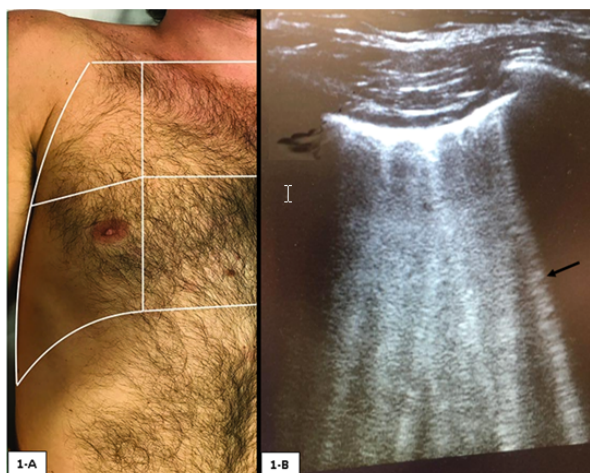This diagnostic accuracy study was conducted in the EDs of Rasool-e-Akram and Sina Hospitals, Tehran, Iran, from 1 August 2014 to 1 June 2014. The study was approved by the ethics committee of Tehran University of Medical Sciences with the code number of 142, 2013. Informed consent was obtained from patients or their relatives.

### 2.2. Participants

The study participants included patients with blunt chest trauma brought to EDs of the mentioned hospitals. We consecutively enrolled eligible patients in the study. Patients suffering from chest trauma or multiple traumas with chest involvement who were aged more than 18 years old and gave consent to participate in the study were included. In addition, patients with hemodynamic instability, patients with diagnosis of pneumothorax, subcutaneous emphysema interfere with the ultrasound images, patients with a Body Mass Index (BMI) >30, pregnant patients, patients without co-operation for ultrasonography, and patients did not give consent to participate in the study or refrained from continuing to cooperate with investigators were excluded.

### 2.3. Imaging

Beside lung ultrasound was performed during the initial assessment with simultaneous resuscitation after the arrival of the patient with blunt chest trauma to the ED and then all patients were sent for CXR and CT scan immediately. We used ultrasound scanner (SonoAce X8, Samsung Medison, Seoul, Korea) equipped with a 7.5 to 10 MHz convex transducer with 5-inch wide field. Ultrasound was performed by six emergency medicine residents who were familiar with ultrasound. First, a one-hour theoretical course was held

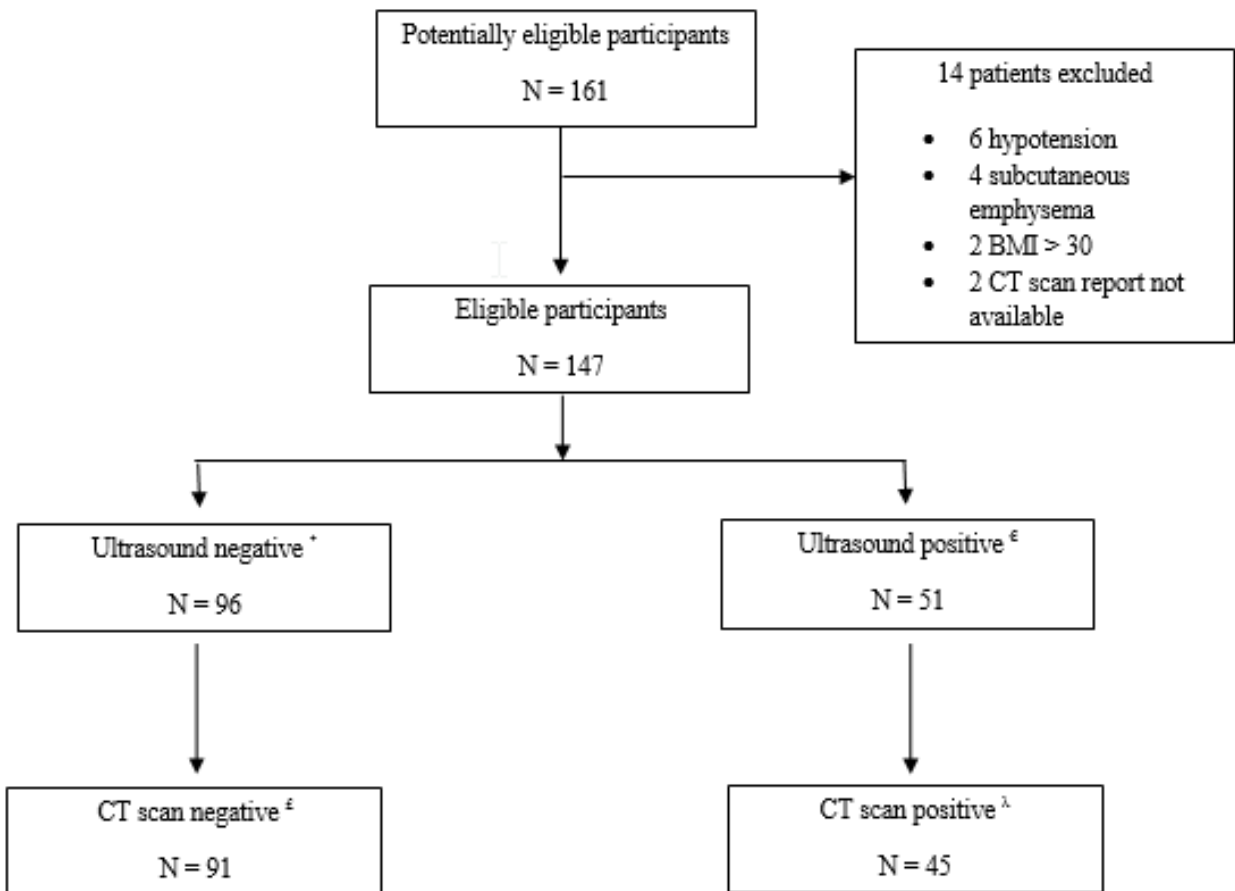


**Figure 1:** A: Lung zones in chest ultrasound (with permission from Credit A, Tozer J, Vitto M, Joyce M, Taylor L. Clinical ultrasound, A Pocket Manual. Springer, 2018). B: lung contusion with more than 6 B-lines (arrow).

for them. Thereafter, bedside tutoring was given by a faculty member of emergency medicine, including at least 25 chest ultrasounds. Each patient was scanned by one of emergency residents. Ultrasonography was done according to the method described by Lichtenstein (13, 14). Each lung area was divided into 4 regions. The upper and lower parts of the anterior and postero-lateral regions of chest walls were scanned with the patient in supine position. We could only examine patients in supine position because of trauma condition. The multiple zones that were examined in ultrasonography are shown in figure 1-A.

In the normal lung, ultrasound was carried out with the probe longitudinally placed in the spaces between the ribs; these indicators can be seen as lung sliding on a line with echogenic view that synchronizes with ventilation. This sign can be seen when visceral pleura moves on the parietal pleura, which rules out pneumothorax. Lung sliding is not always evident and pleural contact and lung movement may be demonstrated by M mode, which is called seashore sign, and is characterized by horizontal lines ("waves") representing the static chest wall and a scattered region ("sand") formed by the dynamic artifacts beyond the pleural line, for which pneumothorax was ruled out. The pleural line was defined as a horizontal hyperechoic line visible at 0.5 cm below the rib line. Horizontal lines arising from and parallel to the pleural line were called A lines; roughly vertical lines arising from and perpendicular to the pleural line were called B lines. During the ultrasound, the probe was placed in the anterior and lateral wall and the rear area around the posterior axillary line. Those who could not move were placed in the supine position. The results were interpreted as follows:

1. Normal ultrasound: lung sliding in addition to less than



**Figure 2:** Study flow chart. \*: equal or less than 6 B-lines, €: more than 6 B-lines, £: true negative, λ: true positive.

3 B-lines on the scanned surface and the absence of any peripheral consolidation.

2. Lung contusion in ultrasound: the presence of one of the following criteria alone or both;

- a) Alveolo-interstitial syndrome (AIS) by the presence of multiple B-lines (more than 3) that originate from pleural line in a person with no clinical cardiopulmonary signs (figure 1-B).
- b) Peripheral parenchymal lesion (PPL), defined by the presence of C-lines: hypoechoic subpleural focal images with or without pleural line gap (10). The chest CT scan and CXR images were analyzed and reported by an attending radiologist. Obviously, physicians performing ultrasound were unaware of the CT and CXR findings. The radiologist was also unaware of the result of the ultrasound performed by the emergency residents. All examinations were performed in the same sequence for all patients.

**2.4. Reference standard**

After the ultrasound, CXR and chest CT scan (lung and mediastinal aspect) without contrast agent were performed. Thoracic CT scan was performed from the apex of the chest to the

diaphragm in a 5-mm interval with the patients in the supine position using a 16 Multi Detector Computed Tomography (MDCT) scanner (Sensation 16, Siemens, Erlangen, Germany). CT scanning can detect lung contusion almost immediately following chest trauma and it is the standard criterion for diagnosis of lung contusion. The evidence of contusion in CT images are non-segmental areas of consolidation and ground-glass opacification that predominantly involve the lung and are directed deeply into the area of trauma, often sparing 1 to 2 mm of subpleural lung parenchyma adjacent to the injured chest wall (15).

**2.5. Data gathering**

Patients’ demographic data as well as ultrasonography, CXR, and chest CT scan findings were collected by trained emergency medicine residents using a predesigned checklist.

**2.6. Statistical Analysis**

The sample size was calculated based on Hosseini et al. (12) study considering  $\alpha$ -error equal to 0.05, power equal to 80%, prevalence of lung contusion equal to 30%, and presumed



**Table 1:** Baseline characteristics of studied patients and imaging findings regarding the presence or absence of lung contusion

Variable	Values
<b>Sex</b>	
Male	116 (78.9)
Female	31 (21.1)
<b>Age (year)</b>	
Mean $\pm$ SD	40.7 $\pm$ 18.6
<b>Mechanism of trauma</b>	
Accident	100 (68.0)
Falling	32 (21.8)
Direct impact	15 (10.2)
<b>Chest X-ray</b>	
Positive	13 (8.8)
Negative	134 (91.2)
<b>Chest CT scan</b>	
Positive	50 (34.1)
Negative	97 (65.9)
<b>Ultrasonography (Number of B-lines)</b>	
Positive (3 – 6)	36 (24.5)
Positive (> 6)	51 (34.7)
Negative ( $\leq$ 3)	60 (40.8)
<b>Ultrasonography (PPL)</b>	
Positive	17 (11.6)
Negative	130 (88.4)

Data are reported as mean  $\pm$  standard deviation (SD) or frequency (%). PPL: Peripheral parenchymal lesion.

sensitivity of 92%. The estimated sample size obtained was 140 patients. All statistical analyses were performed using SPSS 16.0 (SPSS Inc. Chicago, IL, U.S.A.). Quantitative descriptive data was reported using mean  $\pm$  standard deviation (SD), and qualitative data as frequency (%). Quantitative variables such as age and time intervals were assessed regarding normality using One-Sample Kolmogorov-Smirnov Test, and t-test was used for analytical examination. To determine the diagnostic value of ultrasound in lung contusion, sensitivity, specificity, positive predictive value, negative predictive value, positive and negative likelihood ratio, as well as area under the receiver operating characteristic (ROC) curve were calculated. The level of significance was considered less than 5%.

### 3. Results

#### 3.1. Baseline Characteristics of participants

One hundred sixty-one patients were evaluated, 14 patients were secondarily excluded, and finally 147 patients with blunt chest trauma were enrolled (figure 2). The mean age of the patients was  $40.74 \pm 18.6$  (18 - 90) years (78.9% male). Baseline characteristics of patients as well as thoracic imaging findings are shown in Table 1. 96 (65.3%) cases had 6 or less B-lines and 51 (34.7%) had more than 6 B-lines. PPL in favor of lung contusion was observed in 17 (11.6%) patients,

among them 16 cases had more than 6 B-lines and only one case had 3 to 6 B-lines. Chest CT scans of 50 (34%) patients showed definite lung contusion. In eighteen patients, one ninth to three ninths of lung were injured. Half of them (25 patients) had four ninths to six ninths involvement and 7 patients were severely injured (seven ninths to nine ninths involvement).

#### 3.2. Screening performance characteristics of tests

Out of the 51 patients who had more than 6 B-lines on ultrasound, 45 patients had definite contusion and six of them did not show any evidence of lung contusion on CT scan. Table 2 shows the sensitivity, specificity, positive and negative predictive values and likelihood ratios of sonographic B-lines and PPL in detection of lung contusion.

### 4. Discussion

The current study showed acceptable sensitivity and specificity of point of care ultrasound in chest trauma for diagnosis of lung contusion. PPL and more than 6 B-lines had the highest sensitivity and specificity (92.0 and 93.81) in the diagnosis of lung contusion. In addition, when the number of B-lines was >6, it had a good sensitivity and specificity (90.0 and 93.81) in diagnosis of lung contusion. PPL was seen on ultrasound in 17 patients in our study with the sensitivity of 34% (21.21-48.77), and specificity of 100%, which indicated that this is a specific finding in diagnosis of lung contusion. In a study conducted by Soldati et al. (10) out of 37 patients diagnosed with lung contusion, 7 had PPL with a sensitivity of 18.9% and specificity of 100%. The study by Helmy et al. (11) showed that sensitivity and specificity of PPL in diagnosis of lung contusion were 92.5% and 100%, respectively. The Soldati study was more consistent with our results and the notable fact is that the specificity of all three studies was reported to be 100%. In our study, it was found that when more than 3 B-lines was considered as lung contusion, the sensitivity and negative predictive value of the test increased to 94%, but in parallel, specificity and positive predictive value decreased. Therefore, consideration of more than 3 B-lines leads to over-diagnosis of lung contusion. When more than 6 B-lines in ultrasound were considered as lung contusion, specificity and positive predictive value increased significantly; this reduced the probability of false positives. In this study, only 6 false positives were reported, which were diagnosed in chest CT scans as one case of pulmonary fibrosis and one case of pneumonia. Patients with diffuse parenchymal lung disease (DPLD) had positive B-lines on ultrasound as defined in a study conducted by Reibig et al (7). Four other cases diagnosed as B-line by mistake could be Z and E lines. Z lines are vertical lines arising from the pleural line but not



**Table 2:** Diagnostic accuracy of sonographic B-lines and peripheral parenchymal lesion (PPL) in detection of lung contusion considering non-contrast chest CT scan as gold standard

Variable	Specificity	Sensitivity	PPV	NPV	LR <sup>+</sup>	LR <sup>-</sup>
<b>B-line&gt;3</b>						
TP=47						
TN=56	57.73	94.0	53.41	94.92	2.22	0.10
FP=41	(47.28-67.7)	(83.45-98.75)	(42.46-64.12)	(85.85-98.94)	(1.74-2.84)	(0.03-0.32)
FN=3						
<b>B-line&gt;6</b>						
TP=45						
TN=91	93.81	90.0	88.24	94.79	14.55	0.11
FP=6	(87.02-97.70)	(78.19-96.67)	(76.13-95.56)	(88.26-98.29)	(6.67-31.76)	(0.05-0.25)
FN=5						
<b>PLL</b>						
TP=17						
TN=97	100.0	34.0	100.0	74.62	Infinite	0.66
FP=0	(96.27-100)	(21.21-48.77)	(80.49-100)	(66.24-81.84)		(0.54-0.81)
FN=33						
<b>PPL + B-line&gt;6</b>						
TP=46						
TN=91	93.81	92	88.46	95.79	14.87	0.09
FP=6	(87.02-97.7)	(80.77-97.78)	(76.56-95.65)	(89.57-98.84)	(6.82-34.42)	(0.03-0.22)
FN=4						
<b>PPL + B-line&gt;3</b>						
TP=46						
TN=56	57.73	92	52.87	93.33	2.18	0.14
FP=41	(47.28-67.7)	(80.77-97.78)	(41.87-63.67)	(83.8-98.15)	(1.7-2.79)	(0.05-0.36)
FN=4						
<b>CXR</b>						
TP=13						
TN=97	100.0	26.0	100.0	72.39	Infinite	0.74
FP=0	(96.27-100)	(14.63-40.34)	(75.29-100)	(64-79.76)		(0.63-0.87)
FN=37						

Data are presented with 95% confidence interval. TN: true negative; TP: true positive; FP: false positive; FN: false negative; PPV: positive predictive value; NPV: negative predictive value; LR: likelihood ratio.

reaching the distal edge of the screen. E lines are vertical lines that reach the distal edge of the screen but do not arise from the pleural line (10). The above-mentioned studies (10, 11) in traumatic patients reported the sensitivity and specificity of B-line>6 in diagnosis of lung contusion as “94.6% and 96%” and “97.5% and 90%”, respectively, which were consistent with our results. In a study by M. Rocco et al., patients with chest trauma who were under mechanical ventilation in the ICU were assessed for pleural effusion and lung contusion by ultrasound at the time of admission to the ICU. After 48 hours, the authors reported the sensitivity and specificity of ultrasonography in diagnosis of pulmonary contusion to be “86% and 97%” against “89% and 89%” on arrival (8). In our study, the diagnostic value of PLL with the B-line>6 was the highest in diagnosis of lung contusion, with only 2% higher sensitivity when compared to B-line>6 alone. Given that education and diagnosis of B-line>6 is far easier than PPL, it is advised that B-line>6 alone be used as a reliable method for diagnosis of lung contusion. Our study showed that chest x-

ray has low sensitivity and high specificity (26 and 100%) in diagnosis of pulmonary contusion. In a study by McGonigal et al. entitled “Supporting role of lung CT scan in management of patients with blunt trauma”, sensitivity of chest x-ray for lung contusion was reported to be 40% (16). In addition, Hemly et al. showed that chest x-ray has low sensitivity and high specificity, 40% and 90%, respectively (11). Soldati et al. had also reported 27% sensitivity and 100% specificity for chest x-ray, which are consistent with our results (10). Chest radiography is frequently used for evaluation of traumatic patients. Although chest radiography is valuable, based on existing studies, its sensitivity in diagnosis of lung contusion is low and needs several hours to diagnose the lesion (12, 17). CT scan is the gold standard method in chest trauma, but generally needs the patient to be transferred; so, performing it is not possible in an unstable patient. In addition, the cost and radiation of CT scan is high (18). High sensitivity and specificity is considered the advantage of Ultrasound. It seems that sonographic B-lines > 6 could be con-



sidered as a reliable alternative tool in diagnosis of lung contusion.

## 5. Limitation

One of the limitations of the current study was that we excluded the patients with the BMI more than 30, thus the results of study could not be generalized to these patients. Sensitivity and specificity of Ultrasound could be affected by obesity and fat tissue. Also, ultrasound was performed by six emergency residents. They attended a similar education course (lecturing and hands on) but we did not compare them with each other and it could be basically a limitation.

## 6. Conclusion

PPL and B-Lines $>6$  had the highest accuracy in detecting lung contusion. B-Line $>6$  had high sensitivity and specificity and was easy to perform; thus, it seems that B-Line $>$  could be considered as an alternative screening tool in detection of lung contusion.

## 7. Appendix

### 7.1. Acknowledgements

This article was part of Dr. Fariba Zareiee's thesis, who was an emergency medicine resident at the time of the study. The authors would like to thank the nurses of ED at Rasoul-e-Akram and Sina hospitals.

### 7.2. Author contribution

All the authors meet the standard authorship criteria according to the recommendations of international committee of medical journal editors.

#### Authors' ORCIDs

Saeed Abbasi: 0000-0001-6024-1576

Hossein Shaker: 0000-0003-0651-5702

Fariba Zareiee: 0000-0001-9476-7736

Davood Farsi: 0000-0002-8366-2477

Peyman Hafezimoghadam: 0000-0003-0599-369X

Mahdi Rezai: 0000-0003-0486-5717

Babak Mahshidfar: 0000-0001-6174-8432

Mani Mofidi: 0000-0002-0122-3703

### 7.3. Funding/Support

No funds have been received for carrying out this project.

### 7.4. Conflict of interest

There are no conflicts of interest to declare.

## References

- Simon B, Ebert J, Bokhari F, Capella J, Emhoff T, Hayward T, 3rd, et al. Management of pulmonary contusion and flail chest: an Eastern Association for the Surgery of Trauma practice management guideline. *The journal of trauma and acute care surgery*. 2012;73(5 Suppl 4):S351-61.
- Hoff SJ, Shotts SD, Eddy VA, Morris JA, Jr. Outcome of isolated pulmonary contusion in blunt trauma patients. *The American surgeon*. 1994;60(2):138-42.
- Cobanoglu U, Melek M, Edirne Y. Chest radiography diagnosis of pulmonary contusion is associated with increased morbidity and mortality 2010 March 01. 24-9 p.
- Wanek S, Mayberry JC. Blunt thoracic trauma: flail chest, pulmonary contusion, and blast injury. *Critical care clinics*. 2004;20(1):71-81.
- Allen GS, Coates NE. Pulmonary contusion: a collective review. *The American surgeon*. 1996;62(11):895-900.
- Omert L, Yeane WW, Protetch J. Efficacy of thoracic computerized tomography in blunt chest trauma. *The American surgeon*. 2001;67(7):660-4.
- Reissig A, Kroegel C. Transthoracic sonography of diffuse parenchymal lung disease: the role of comet tail artifacts. *Journal of ultrasound in medicine: official journal of the American Institute of Ultrasound in Medicine*. 2003;22(2):173-80.
- Rocco M, Carbone I, Morelli A, Bertolotti L, Rossi S, Vitale M, et al. Diagnostic accuracy of bedside ultrasonography in the ICU: feasibility of detecting pulmonary effusion and lung contusion in patients on respiratory support after severe blunt thoracic trauma. *Acta anaesthesiologica Scandinavica*. 2008;52(6):776-84.
- Lichtenstein DA, Meziere GA. Relevance of lung ultrasound in the diagnosis of acute respiratory failure: the BLUE protocol. *Chest*. 2008;134(1):117-25.
- Soldati G, Testa A, Silva FR, Carbone L, Portale G, Silveri NG. Chest ultrasonography in lung contusion. *Chest*. 2006;130(2):533-8.
- Helmy S, Beshay B, Hady MA, Mansour A. Role of chest ultrasonography in the diagnosis of lung contusion. *Egypt J Chest Dis Tu*. 2015;64(2):469-75.
- Hosseini M, Ghelichkhani P, Baikpour M, Tafakhori A, Asady H, Haji Ghanbari MJ, et al. Diagnostic Accuracy of Ultrasonography and Radiography in Detection of Pulmonary Contusion; a Systematic Review and Meta-Analysis. *Emergency*. 2015;3(4):127-36.
- D L. *General ultrasound in the critically ill*. 2nd ed ed. Germany: Springer-Verlag; 2005.
- Lichtenstein D, Meziere G, Biderman P, Gepner A, Barre O. The comet-tail artifact. An ultrasound sign of alveolar-interstitial syndrome. *American journal of respiratory*



- and critical care medicine. 1997;156(5):1640-6.
15. Johnson SB. Tracheobronchial injury. *Seminars in thoracic and cardiovascular surgery*. 2008;20(1):52-7.
  16. McGonigal MD, Schwab CW, Kauder DR, Miller WT, Grumbach K. Supplemental emergent chest computed tomography in the management of blunt torso trauma. *The Journal of trauma*. 1990;30(12):1431-4; discussion 4-5.
  17. Paydar S, Johari HG, Ghaffarpasand F, Shahidian D, Dehbozorgi A, Ziaeiian B, et al. The role of routine chest radiography in initial evaluation of stable blunt trauma patients. *The American journal of emergency medicine*. 2012;30(1):1-4.
  18. Mayo JR, Aldrich J, Muller NL. Radiation exposure at chest CT: A statement of the Fleischner Society. *Radiology*. 2003;228(1):15-21.

