

ORIGINAL RESEARCH

Diagnostic Accuracy of Ultrasound in Detection of Traumatic Lens Dislocation

Seyed Hossein Ojaghi Haghghi¹, Hamid Reza Morteza Begi¹, Raana Sorkhabi², Mohammad Kazem Tarzamani³, Golshan Kamali Zonouz^{1*}, Akram Mikaeilpour⁴, Farzad Rahmani¹

1. Department of Emergency Medicine, Tabriz University of Medical Sciences, Tabriz, Iran
2. Department of Ophthalmology, Tabriz University of Medical Sciences, Tabriz, Iran
3. Department of Radiology, Tabriz University of Medical Sciences, Tabriz, Iran
4. Department of Cardiology, Tabriz University of Medical Sciences, Tabriz, Iran

Abstract

Introduction: Traumatic eye injuries (TEI) involved about 3% of cases referred to the emergency departments of developing countries. Lens dislocation is one of the critical cases of ophthalmic emergencies. The present study was aimed to evaluate the diagnostic accuracy of ultrasonography in detection of traumatic lens dislocation. **Methods:** In this cross-sectional study the findings of ultrasonography and orbital computed tomography (OCT) of head and face trauma patients, referred to Imam Reza hospital, Tabriz, Iran, from July 2013 to June 2014, have been compared. The sensitivity, specificity, positive and negative likelihood ratio, positive and negative predictive value, and accuracy of ultrasonography were calculated. Cohen's kappa coefficient was presented to assess the agreement of ultrasonography with OCT findings. **Results:** One hundred thirty patients with the mean age of 35.4 ± 18.0 were evaluated (75.4% male). Sensitivity and specificity of ultrasonography were 84.6% (95% CI: 53.7-97.3) and 98.3% (95% CI: 93.3-99.7), respectively. In addition, positive and negative likelihood ratio were calculated 49.5 (95% CI: 12.3-199.4) and 0.15 (95% CI: 0.04-0.56), respectively. Cohen's kappa coefficient of 0.83 (95% CI: 0.66-1.0; $p < 0.0001$) was representative of excellent agreement of these two tests. **Conclusion:** The finding of this project was representative of 84.6% sensitivity, 98.3% specificity, and 96.9% accuracy of ultrasonography in detection of traumatic lens dislocation. It seems that in cases, which OCT is not possible, ultrasonography, could be an acceptable option to assess traumatic eye injuries.

Key words: Ultrasonography; diagnostic techniques; ophthalmological; lens subluxation; eye injuries, trauma

Cite this article as: Ojaghi Haghghi SH, Morteza Begi HR, Sorkhabi R, et al. Diagnostic accuracy of ultrasonography in detection of traumatic lens dislocation. *Emergency*. 2014;2(3):121-4.

Introduction:

Traumatic eye injuries (TEI) involved about 3% of cases visited in emergency departments (ED) of developing countries (1). It is estimated that trauma causes blindness and visual impairment in many referees of ophthalmic emergency (2). Most of these injuries are hard to diagnose in initial ED assessment. On the other hand, more frequent examinations to detect injuries maybe hazardous for the patient (3). Orbital computed tomography (OCT) scan, magnetic resonance imaging (MRI), ultrasonography, and slit-lamp are introduced as the most important imaging tools to evaluate TEI (4-8). Although MRI presents high accurate and quality images, it is an expensive and time-consuming test, which is not accessible in all

emergency centers. Optical methods are cost effective and easy to use, but they have a low accuracy in evaluation of injuries to optical structures such as sclera, pupil, and cornea, as well as hemorrhage. While ultrasonography, known as a non-expensive, accessible, and safe method, has a high accuracy in evaluation of injuries to optical structures (3). When the patient is non-cooperative for fundoscopic tests or suffers from severe edema, chemosis, or hyphema, eye ultrasonography can present valuable and useful information to the physician (9). But, it should be mentioned that diagnostic accuracy of ultrasonography is highly dependent to operator proficiency and it is not reliable in detecting parenchymal injuries (10). Lens dislocation is one of the critical cases of ophthalmic emergencies referred to partial or complete dislocation of eye lens from its natural location to posterior chamber. Trauma is one of the most common reasons of lens dislocation (11). The fast diagnosis of such an injury can be greatly help improv-

*Corresponding Author: Kamali Zonouz Golshan; Emergency Medicine Department, Imam Reza Hospital, Tabriz University of Medical Sciences, Golgasht Avenue, Tabriz, Iran, Tel/Fax: 00984113352078
E-mail: G.Kamali.Z@gmail.com

Received: May 2014; Accepted: June 2014



ing the patients' outcomes. Diagnostic accuracy of ultrasonography in assessment of traumatic lens dislocation is evaluated in a few studies. Whereas some of investigations suggested OCT as an accurate method (12), others consider ultrasonography as a valuable diagnostic tool in detection of lens dislocation, especially in lack of OCT (13-16). However, the low number of studied samples in this field is the critical limitation. Therefore, the present study was performed to evaluate the diagnostic value of ultrasonography versus OCT in traumatic lens dislocation.

Methods:

Study design and setting:

In this cross-sectional study the findings of ultrasonography and OCT of multiple trauma patient with head trauma, referred to Imam Reza hospital, Tabriz, Iran, from July 2013 to June 2014, have been compared. Data collection and ultrasonography was done by an emergency medicine specialist. OCTs (as a gold standard tool) were interpreted by a radiologist who was blind to the aim of study. The protocol of the present project was studied and confirmed by the ethical committee of Tabriz University of Medical Sciences. All researchers adhered the Helsinki declaration during the study. The study protocol did not have any interference with treatment process and no danger threatened patients. The collected forms were anonymous and for each patient an especial code registered. Before the study, patients filled the personal consent form.

Participants

In this study, multiple trauma patients with TEI were entered. Patients with irregularity of the globe contour, and lack of ability to cooperate for imaging were excluded from the study. Sample selection was sequentially. For determining of the sample volume, the least needed samples were achieved 121 persons noticing to at least 93% sensitivity of ultrasonography to detect TEI, 15% prevalence (12), 95% confidence interval ($\alpha=0.05$), 90% power ($\beta=0.1$), and maximum error of 1% ($d=0.01$).

Measurements

The emergency medicine specialist was prospectively assessed demographic data (age, sex, and trauma mechanism), clinical symptoms of each patient, and registered them in data gathering form. Then, the patients underwent eye ultrasonography by a trained emergency medicine specialist. Ultrasonography was done using bedside machine (GH Healthcare; LOGIQ 200, PRO series; Korea) with 10 MHz micro-convex linear transducer in sagittal and transverse plane and closed eye technique with water-soluble gel. Then patients referred to ED radiology unit for performing OCT. The findings of OCT was interpreted by a radiologist blind to the goal of study and recorded. OCT was done using a Toshiba Asteion 16 slices scanner with consid-

ering the one-millimeter distance between image slices. Both ultrasonography and OCT was performed in recumbent position.

Statistical analysis

Data were entered to SPSS version 21.0 and imaging findings reported as the frequency and percentage. For evaluating the quality of ultrasonography receiver operating characteristic (ROC) curve was drawn and finally sensitivity, specificity, accuracy, positive likelihood ratio, negative likelihood ratio, positive predictive value, and negative predictive value calculated. Cohen's kappa coefficient was presented to assess the agreement of ultrasonography with OCT findings. $P<0.05$ was considered as a significant level.

Results:

130 patients with the mean age of 35.4 ± 18.0 were entered to the study (75.4% male). Five patients (3.8%) had systolic blood pressure below 90 and 32 ones

Table 1: Clinical and demographic characteristics of studied patients [↑](#)

| Clinical characteristic | Frequency (%) |
|---------------------------|---------------|
| Gender | |
| Male | 32 (24.6) |
| Female | 98 (75.4) |
| Hypotension | |
| No | 125 (96.2) |
| Yes | 5 (3.8) |
| Glasgow Coma Scale | |
| 14-15 | 74 (56.9) |
| 9-13 | 35 (26.9) |
| 3-9 | 21 (16.2) |
| Mechanism | |
| Pedestrian | 20 (15.4) |
| Car (driver) | 51 (39.2) |
| Motorcycle (driver) | 36 (27.7) |
| Falling | 8 (6.15) |
| Intentional injuries | 7 (5.4) |
| Other | 8 (6.15) |
| Visual accuracy | |
| Normal | 57 (43.85) |
| Abnormal | 8 (6.15) |
| No cooperation | 65 (50.0) |
| Laceration | |
| No | 73 (56.15) |
| Yes | 57 (43.85) |
| Ecchymosis | |
| No | 17 (13.1) |
| Yes | 113 (89.9) |
| Eye bleeding | |
| No | 128 (98.5) |
| Yes | 2 (1.5) |
| Globe Rupture | |
| No | 124 (95.4) |
| Yes | 6 (4.6) |
| Periorbital edema | |
| NO | 67 (51.5) |
| Yes | 63 (48.5) |



Table 2: Diagnostic accuracy of ultrasonography in detection of traumatic lens dislocation [↑](#)

| Value | Rate (95% CI) |
|---------------------------|-------------------|
| Sensitivity | 84.6 (53.7-97.3) |
| Specificity | 98.3 (93.3-99.7) |
| Positive predictive value | 84.6 (53.7-97.3) |
| Negative predictive value | 98.3 (93.3-99.7) |
| Positive likelihood Ratio | 49.5 (12.3-199.4) |
| Negative likelihood Ratio | 0.15 (0.04-0.56) |
| Accuracy | 96.9 (93.9-99.9) |

CI: confidence interval.

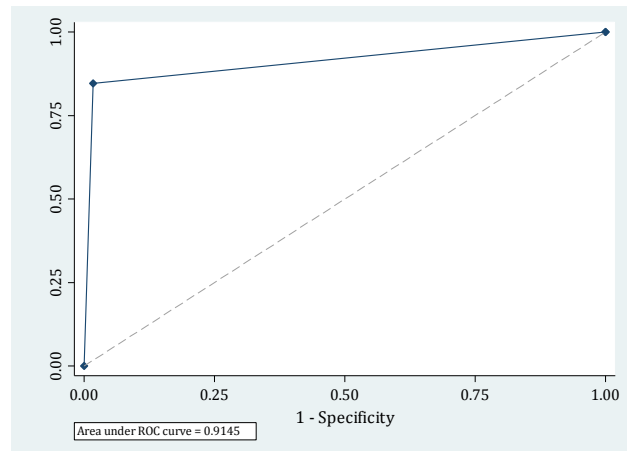
(24.6%) suffered from tachycardia. GCS of 21 patients (16.15%) was below nine and in 35 ones (26.9%) with in 9-13 ([Table 1](#)). The most common mechanism of accident in the patients was related to car (39.2%), motorcycle (27.7%), and pedestrian accidents (15.4%), respectively.

OCT evaluation has detected 13 cases (10%) of traumatic lens dislocation. The findings of ultrasonography in 11 cases were compatible with OCT with two false negative cases, while two false positive were found by ultrasonography. The area under the ROC curve of ultrasonography in traumatic lens dislocation was achieved 0.9145 (95% CI: 0.81-1.0) ([Figure 1](#)). Sensitivity and specificity of ultrasonography were 84.6% (95% CI: 53.7-97.3) and 98.3% (95% CI: 93.3- 99.7), respectively. Positive and negative likelihood ratio of this diagnostic test in detection of lens dislocation were calculated 49.5 (95% CI: 12.3-199.4) and 0.15 (95% CI: 0.04-0.56), respectively ([Table 2](#)). Cohen's kappa coefficient of 0.83 (95% CI: 0.66-1.0; $p < 0.0001$) was representative of excellent agreement of these two tests.

Discussion:

The findings of the present study showed 84.6% sensitivity and 98.3% specificity of eye ultrasonography in detection of traumatic lens dislocation. The accuracy of this diagnostic test was 96.9%. Based on these results, it seems that in cases, which OCT is not possible, ultrasonography, could be an acceptable alternative for evaluation of lens dislocation.

There are a few study assessed the diagnostic value of ultrasonography in detection of lens dislocation. Imran et al. revealed that sensitivity and specificity of ultrasonography are 75% and 97.9% in diagnosis of lens dislocation, respectively (12). Blavis and colleagues by study of 61 patients observed two cases of lens dislocation both of which was detected by ultrasonography (13). The trivial difference between previous studies and the present project could be due to operator-dependent of ultrasonography. On the other hand, reaching a certain diagnosis is time consuming and ophthalmic consult-

**Figure 1:** The receiver operating characteristic (ROC) curve of ultrasonography in detection of traumatic lens dislocation. [↑](#)

ants are not present in all hospitals. All of these issues maybe lead to delay in detection and management whereas eye ultrasonography can be helpful in such situations. However, eye ultrasonography has not yet common in ophthalmic clinicians. In addition, eye ultrasound transducers for eye ultrasonography are different from common transducers applied in the ED (13). In addition, it should be mentioned that clinical evaluation of patients with TEI is painful and not possible in many cases.

Although there is no information regarding the negative effect of entered energy by high frequency ultrasonography on eye structures, more investigation is required in this area. One of the limited studies in this field revealed that using ultrasonography with frequency of 10 to 60 MHz did not have any destructive effects on visual field and histological findings. But, the recent study showed that using ultrasonography causes to increase the internal temperature of eye (17). However, researchers expressed that this test should be used precisely until finding appropriate solutions to the above problems.

Conclusion:

The finding of this project was representative of 84.6% sensitivity, 98.3% specificity, and 96.9% accuracy of ultrasonography in detection of traumatic lens dislocation. It seems that in cases, which OCT is not possible, ultrasonography, could be an acceptable option to assess traumatic eye injuries.

Acknowledgments:

Authors would like to say thanks to all patients and staffs of the emergency department of Imam Reza hospital for their contribution. This article has been written in terms of the residency thesis registered in Tabriz University of Medical Sciences.

Conflict of interest:

None



Funding support:

None

Authors' contributions:

All authors passed four criteria for authorship contribution based on recommendations of the International Committee of Medical Journal Editors.

References:

1. Kubal WS. Imaging of Orbital Trauma. *Radiographics*. 2008;28(6):1729-39.
2. McClenaghan F, Ezra D, Holmes S. Mechanisms and management of vision loss following orbital and facial trauma. *Curr Opin Ophthalmol*. 2011;22(5):426-31.
3. Silverman RH. High-resolution ultrasound imaging of the eye—a review. *Clin Experiment Ophthalmol*. 2009;37(1):54-67.
4. Brisco J, Fuller K, Lee N, Andrew D. Cone beam computed tomography for imaging orbital trauma—image quality and radiation dose compared with conventional multislice computed tomography. *Br J Oral Maxillofac Surg*. 2014;52(1):76-80.
5. Nowinski WL. The future of imaging in orbital disease. New York: Marcel Dekker; 2004. p. 353-70.
6. Nayak B, Desai S, Maheshwari S. Interpretation of magnetic resonance imaging of orbit: Simplified for ophthalmologists (Part I). *J Clin Ophthalmol Res*. 2013;1(1):29-35.
7. Amini A, Eghtesadi R, Feizi AM, et al. Sonographic Optic Nerve Sheath Diameter as a Screening Tool for Detection of Elevated Intracranial Pressure. *Emergency*. 2013;1(1):15-9.
8. Frasure SE, Saul T, Lewiss RE. Bedside ultrasound diagnosis of vitreous hemorrhage and traumatic lens dislocation. *Am J Emerg Med*. 2013;31(6):1002. e1-2.
9. Zvornicanin J, Jusufovic V, Cabric E, Musanovic Z, Zvornicanin E, Popovic-Beganovic A. Significance of ultrasonography in evaluation of vitreo-retinal pathologies. *Med Arh*. 2012;66(5):318-20.
10. Poletti PA, Kinkel K, Vermeulen B, Irmay F, Unger PF, Terrier F. Blunt Abdominal Trauma: Should US Be Used to Detect Both Free Fluid and Organ Injuries? . *Radiology*. 2003;227(1):95-103.
11. Wang R, Bi C-C, Lei C-L, Sun W-T, Wang S-S, Dong X-J. Multiple methods of surgical treatment combined with primary IOL implantation on traumatic lens subluxation/dislocation in patients with secondary glaucoma. *Int J Ophthalmol*. 2014;7(2):264-72.
12. Imran S, Amin S, Daula MIH. Imaging in Ocular Trauma Optimizing the Use of Ultrasound and Computerised Tomography. *Pak J Ophthalmol*. 2011;27(3):146-51.
13. Blaivas M, Theodoro D, Sierzenski PR. A study of bedside ocular ultrasonography in the emergency department. *Acad Emerg Med*. 2002;9(8):791-9.
14. Eken C, Yuruktumen A, Yildiz G. Ultrasound diagnosis of traumatic lens dislocation. *J Emerg Med*. 2013;44(1):e109-10.
15. Eze KC, Enock ME, Eluehike SU. Ultrasonic evaluation of orbito-ocular trauma in Benin-City, Nigeria. *Niger Postgrad Med J*. 2009;16(3):198-202.
16. Silverman RH, Lizzi FL, Ursea BG, et al. Safety levels for exposure of cornea and lens to very high-frequency ultrasound. *J Ultrasound Med*. 2001;20(9):979-86.
17. Palte HD, Gayer S, Arrieta E, et al. Are ultrasound-guided ophthalmic blocks injurious to the eye? A comparative rabbit model study of two ultrasound devices evaluating intraorbital thermal and structural changes. *Anesth Analg*. 2012;115(1):194-201.

