

# Lupus Nephritis in a Patient with Past History of Henoch Schönlein Purpura

Mojtaba Fazel<sup>1</sup>,  
Fateme Nili<sup>2</sup>,  
Seyed Reza Raeskarami<sup>1</sup>,  
Maassoumeh Akhlaghi<sup>3</sup>,  
Mojgan Faraji-Goodarzi<sup>4\*</sup>,  
Mastaneh Moghtaderi<sup>5</sup>  
Parvin Akbari Asbagh<sup>5</sup>

1 Department of Pediatrics, Valiasr Hospital, Imam Khomeini Medical Complex, Tehran University of Medical Science, Tehran, Iran.

2 Department of Pathology, Imam Khomeini Hospital Complex, Tehran university of Medical Sciences, Tehran, Iran.

3 Rheumatology Research Center, Tehran University of Medical Sciences.

4 Department of Pediatrics, Lorestan University of Medical Sciences, Khorramabad, Iran.

5 Department of Pediatric Nephrology, Chronic Kidney Disease Research Center, Tehran University of Medical Sciences, Tehran, Iran.

## \*Corresponding Author

Mojgan Faraji-Goodarzi.  
[mojganfaraji@gmail.com](mailto:mojganfaraji@gmail.com)

**Received:** May, 2020

**Revised:** June, 2020

**Accepted:** June, 2020

## Introduction

SLE is an autoimmune disease with multi systemic involvement. Various organs in the body, including the skin, kidneys, joints, heart, and central nervous system, may be affected. The etiology is unknown, genetic predisposition, epigenetic factors and environmental agents play role in the disease development. Its pathophysiology is related to the loss of the immune tolerance to self-nuclear antigens, followed by the immune complex deposition in various tissues, activation of the complement system, immune system dysregulation, production of various autoantibodies, and cytokines. Interferon alpha plays a major role in the

## Abstract

Systemic lupus erythematosus is an autoimmune disease associated with systemic involvement. Various organs including skin, kidneys, joints, heart, and central nervous system, may be affected. One of the serious organ damages in SLE is renal involvement as lupus nephritis, which occurs in 50-75% of children with SLE. Approximately 6-12% of pediatric SLE may develop other conditions, such as JIA, JDM, and polymyositis, scleroderma, and Crohn's disease. Henoch schönlein purpura (HSP) is another disease that accompanies with SLE. There have been several reports of HSP as the primary manifestation of SLE. In this report we aim to highlight lupus nephritis as the first presentation of SLE and its association with HSP in our patient, a 6-year-old boy with lupus nephritis and past history of HSP 4 years before initiating of SLE.

**Keywords:** Lupus nephritis; Henoch Schonlein Purpura; Child.

Conflict of interest: The author declares no conflict of interest.  
Please cite this article as: Fazel M, Nili F, Raeskarami SR, Akhlaghi M, Faraji-Goodarzi M, Moghtaderi M, et al. Lupus Nephritis in a Patient with Past History of Henoch Schönlein Purpura. *J Ped Nephrol* 2020;8(3):1-5.  
<https://doi.org/10.22037/jpn.v8i3.30962>

disease pathophysiology (1) The presence of autoantibodies reflects the loss of immune tolerance (2).

SLE is rare in children and is more common in young women. However, 20% of cases of SLE occur in children. Its prevalence is 3.3-8.8/100,000 children. SLE is more severe in children with a variable clinical picture. The American Rheumatology Association (ACR) classification criteria has defined 11 criteria for SLE: malar rash, discoid rash, photosensitivity, oral ulcers, serositis, arthritis, neurological and renal involvement, hematologic and immunologic lab tests and the

presence of ANA. One of the most serious presentations of SLE is lupus nephritis, which is more common and severe in children than adults, and occurs in 50-75% of children with SLE (1). The most common clinical features present at the time of diagnosis are constitutional symptoms include fever, fatigue, loss of appetite and musculoskeletal symptoms. In this report we aim to highlight lupus nephritis as the first presentation of SLE and its association with HSP in our patient, a 6-year-old boy with lupus nephritis and past history of HSP 4 years before initiating of SLE.

### Case Report

A 6-year-old boy who complained of low back pain for 2 weeks that started after lifting a heavy object. Low back pain got worse with rest and intensified at night. He experienced Lower limb and back pain from 2 weeks before the visit. He had a history of HSP at the age of 2 without any renal complication in follow-up. He had no family history of rheumatic or renal disease. There was No history of hair loss, fatigue, anorexia or photosensitivity. In physical examination, Subcutaneous nodules were on the right cheek and the left arm without erythema or tenderness, approximately 1 x 2 cm in size.

The hip, vertebrae and peripheral joints were normal. Because of bone pain, bone marrow aspiration was performed which showed normal result as other studies such as MRI of the spine and tri-phasic bone scan. Echocardiography, chest radiography, and abdominal ultrasound were also normal.

Laboratory tests revealed normal CBC, no thrombocytopenia or leukopenia, ESR (74 mm/h), CRP (4 mg/L), creatinine (0.7 mg/dl), urea (23 mg/dl). Proteinuria and microscopic hematuria with an increasing trend was detected. 24-hour urinary protein was reported to be (2557 mg/24h). ANA was Positive, Anti-ds DNA was increased but serum levels of complements were normal, hypoalbuminemia was detected and no dislipidemia was shown. But cholesterol levels were increased a month later. GFR was 90 ml/min/1.73 m<sup>2</sup>. The patient presented nephrotic / nephritic features.

Renal biopsy was performed which on immunofluorescence study, indicated full-house pattern of complement and immunoglobulin deposition with granular pattern along the GBM and mesangial spaces.

On Electron microscopy, subepithelial, mesangial and scattered subendothelial immune type deposits were found. Overall findings are compatible with Lupus Nephritis, ISN/PRS class III(A)+V (Figure 1).

Before starting treatment, PPD was performed, which was negative. The patient was diagnosed with SLE, and treatment with methylprednisolone pulses 1gr/3-days, Mycophenolate Mofetil 600 mg/m<sup>2</sup> twice a day and Hydroxychloroquine 6mg/kg (HCQ) were started, and then oral prednisolone was given at a dose of 1 mg / kg. Because of worsening of edema Hydrochlorothiazide was added to treatment. The proteinuria was decreased, Anti-ds DNA decreased to normal level, MMF and HCQ were continued and tapering of oral prednisolone was considered.

### Discussion

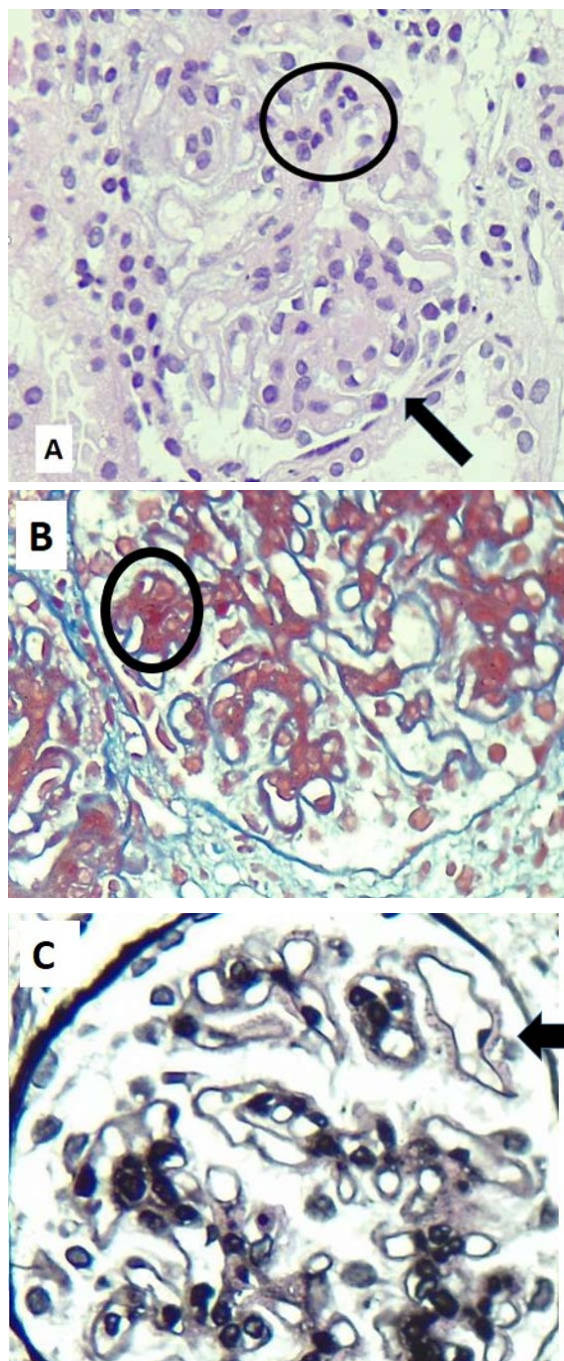
Pediatric SLE is a rare multisystem disease. 20% of cases of SLE occur in children. It affects 0.3-8.8 in 100,000 children a year. It is common among Asians. The disease is rare in children under 5 years of age (3).

In pediatric SLE, 50-75% of cases suffer from renal involvement, which is more common in children than adults. Renal disease is the main cause of mortality and morbidity in these patients. Although the survival of children with lupus nephritis (LN) has improved in recent decades, their mortality is 19 times that of healthy children (1).

LN is more common in boys. Renal involvement may be the first manifestation of SLE, it may develop before extra renal manifestations (4). In LN, glomeruli are the main target of injury, but interstitial tissue may also get involved (3).

LN is characterized by persistent proteinuria, 3+ in the dipstick sample or more than 500 mg within 24 hours or in the presence of urinary casts. It can be presented by nephrotic syndrome, acute nephritic syndrome, mild asymptomatic hematuria or glomerulonephritis. Renal biopsy is needed to assess the severity of the disease and to determine the treatment method and predict the outcome. Delay in the diagnosis decreases survival (1).

According to the SLICC 2012 (Systemic Lupus Collaborating Clinics Classification Criterion for SLE), the presence of 4 criteria is essential, at least



**Figure 1.** Microscopic examination of formalin-fixed paraffin embedded blocks show diffuse mesangial hypercellularity (circles), segmental endocapillary proliferation in some (<50%) glomeruli (black arrow, Fig A and diffuse GBM thickening. Trichrome and Jones' stains reveal subepithelial deposits and GBM spikes (Fig c). A: H&E sections (x400), B: Trichrome stain (x400), C: Jones' stain (x400).

one of which is a clinical criterion and one is an immunologic criterion, or a compatible renal biopsy

result with Lupus nephritis in addition to positive Anti ds-DNA and ANA (3,5).

Histopathology of LN results from deposition of the immune complexes and injury to podocytes, endothelial, mesangial cells and tubulointerstitial tissue. Immune complexes activate macrophages, neutrophils and the classic pathway of complement, leading to the production of inflammatory cytokines. Increased consumption leads to lower complement proteins levels. Decreased C3 and C4 levels are associated with proliferative LN (1). This pathologic process may have started a few years before the clinical onset of the disease. Autoantibodies may be present about 3.3 years before the clinical manifestation of SLE. ANA is detectable earlier than Anti ds-DNA. (6,7) Complement components levels may be normal in 30.6% of patients with SLE (8). In our patient, the levels of C3, C4, and CH50 were normal before and during treatment. LN is classified in Class 1-6 on the recommendation of the International Society of Nephrology and the Renal Pathology Society of ISN / RPS in 2018. The result of our patient's renal biopsy was compatible with class III+V LN. Class III is focal proliferative LN. It is sometimes associated with class V. In such cases, the treatment is similar to class III / IV LN (1). Proliferative LN, class III / IV, are 15-20% of LN cases and have poor prognosis. These patients should receive high-dose Corticosteroid, Cyclophosphamide or MMF (5,9). Mesangioproliferative and focal proliferative pattern of glomerulonephritis can be identified in several diseases, including IgA nephropathy, HSP, infectious-related, C3 GN and Lupus nephritis. Pattern of immune reaction on IF study and ultrastructural finding are distinctive. Full-house pattern of immune reaction and presence of deposits in all mesangial, subepithelial and subendothelial spaces are pathologic finding supportive of Lupus nephritis.

Tubulointerstitial nephritis, thrombotic microangiopathic, minimal change disease and opportunistic renal infections cause features similar to LN. Therefore, in a patient with SLE with persistent urinary hematuria or renal function impairment, renal biopsy is necessary (10).

Treatment includes a 6-month course of induction therapy with MMF or cyclophosphamide with high dose intravenous or oral corticosteroid, followed by maintenance therapy with azathioprine or MMF. The minimum duration of maintenance treatment is

3 years (1). The rate of remission in children with class III and IV LN is 55%, while in class V, remission is higher and is 90%. Approximately 25% of pediatric patients cannot remain in remission and experience renal flare (4). HCQ reduces renal damage in SLE. ACR recommends the use of HCQ for all patients with LN (3).

Approximately 6-12% of children with SLE may develop other conditions, such as JIA, JDM, and polymyositis, scleroderma, and Crohn's disease. HSP is another disease that accompanies with SLE. It is characterized by non-thrombocytopenic purpura, abdominal pain, arthritis and renal involvement. HSP may occur before or after the onset of SLE (11). There have been several reports of HSP as the primary manifestation of SLE. (7) In other words, HSP could be the first manifestation of SLE in children. HSP is more common in boys and the average age of onset is 7 years old, while HSP with SLE is more common in older girls. Some patients may have a deficiency of complement components (12) or abnormality in the clearance of apoptotic cells, leading to the production of autoantibodies and the formation of immune complexes (13). However, another study stated that the low complement level in HSP is transient and does not affect the prognosis of patients (14). In our patient, there was a history of HSP 4 years before the onset of SLE.

He did not complain of any constitutional symptoms, but at the onset of the disease, as mentioned earlier, he suffered from low back pain and subcutaneous nodules. However, his low back pain improved after 3 weeks before starting treatment for SLE. Subcutaneous nodules were also transient and resolve spontaneously without scarring. Musculoskeletal signs and symptoms may present at the onset of the disease with a prevalence of about 72% (15). SLE usually affects the small joints of the hands and knees. However, persistent low back pain has been seen in 26% of adults with SLE (16). Although some patients have inflammatory pain in the lower back, they have only mild inflammation in the axial joints and no radiological evidence of severe sacroiliac involvement (17).

### Conclusion

In conclusion, this report emphasizes the importance of renal biopsy in the diagnosis and management of LN. SLE can be manifest as renal

involvement early in disease course. Decreased complement levels in the SLE and lupus nephritis are common but normal levels are seen in some patients. Relation between pediatric SLE and HSP indicates that long duration follow up is necessary for HSP patients.

### Conflict of Interest

There are no conflicts of interest.

### Financial Support

Not declared.

### References

1. Veloso Brant Pinheiro S, Figueiredo Dias R, Cabral Gonçalves Fabiano R, de Almeida Araujo S, Cristina Simões e Silva A. Pediatric lupus nephritis. *J Bras Nefrol.* 2019; 41(2):252–265.
2. Lech M, Anders H-J. The Pathogenesis of Lupus Nephritis. *J Am Soc Nephrol.* 2013; 24(9): 1357–1366 .
3. Sinha R, Raut S. Pediatric lupus nephritis: Management update. *World J Nephrol.* 2014;3(2):16–23.
4. Wenderfer SE, Natasha M. Ruth an NM, Brunner HI. Advances in the care of children with lupus nephritis *Pediatric Research.* 2017;81(3).
5. Hahn BH, McMahon MA, Wilkinson A, Wallace WD, Daikh DI, Fitzgerald JD, et al.; American College of Rheumatology. American College of Rheumatology guidelines for screening, treatment, and management of lupus nephritis. *Arthritis Care Res.* 2012;64:797-808.
6. Sterner R M, Hartono S P, Grande J P. The Pathogenesis of Lupus Nephritis. *J Clin Cell Immunol.* 2014;5(2): 205.
7. Abdwani R, Abdalla E, El-Naggari M, Al Riyami M. Henoch-Schonlein purpura with lupus-like nephritis: an uncommon occurrence. *International Journal of Rheumatic Diseases.* 2017;20(11): 1853-1855.
8. Afzali P, Isaeian A, Sadeghi P, Moazzami B, Parvaneh N, et al. Complement deficiency in pediatric-onset systemic lupus erythematosus. *J Lab Physicians.* 2018;10:232-6.
9. Ishizaki J, Saito K, Nawata M, Mizuno Y, Tokunaga M, et al. Low complements and high titre of anti-Sm antibody as predictors of histopathologically proven silent lupus nephritis without abnormal urinalysis in patients with systemic lupus erythematosus. *Rheumatology* 2015;54:405-412.
10. Anders HJ, Weening JJ. Kidney disease in lupus is not always 'lupus nephritis'. *Anders and Weening Arthritis Research & Therapy.* 2013;15:108.
11. Peng H, Bao Yu H, Dong Dong Zh, Guang Mei J, Si Yan L, et al. Henoch-Schönlein purpura in a pediatric patient with lupus. *Arch Med Sci* 2017;13(3): 689–690.
12. Al-Attrach I, Al-Shibli A, Al-Riyami L, Al-Salam S. Systemic Lupus Erythematosus with Severe Nephritis That Mimicked Henoch-Schoenlein Purpura. *Arab J of Nephrology and Transplantation.* 2011;4(3):159-61.
13. Murata C, Rodríguez-Lozano AL, Guadalupe Hernández-Huirache H, Martínez-Pérez M, Rincón-

- Arenas LA, et al. IgA vasculitis (Henoch–Schönlein Purpura) as the first manifestation of juvenile Systemic Lupus Erythematosus: Case control study and systematic review. *BMC Pediatrics*. 2019;19:461.
14. Lin Q, Li X. Children with Henoch–Schönlein purpura with low complement levels: follow-up for >6 years. *Pediatr Nephrol*. 2017;32:1279.
  15. Szymanik-Grzelak H, Kuźma-Mroczkowska E, Małdyk J, Pańczyk-Tomaszewska M. Lupus nephritis in children– 10 years’ experience. *Cent Eur J Immunol*. 2016; 41(3): 248–254
  16. Cezarinoa R S, Cardoso J R, Rodriguesa K N, Magalhães Y S, de Souza T Y, et al. Chronic low back pain in patients with systemic lupus erythematosus: prevalence and predictors of back muscle strength and its correlation with disability. *rev bras reumatol*. 2017;57(5):438–444
  17. Yilmaz N, Yazici A, Z. Aydin S and Yavuz S. Inflammatory Back Pain Is Increased in SLE and Associated with Anti-Sm Antibodies. 2012