

Brief Report

J Ped. Nephrology 2015;3(3):121-123
<http://journals.sbmu.ac.ir/jpn>

Clinical Features and Outcome in Children With Primary Hyperoxaluria; Single Center Experience

Nahid Mamizadeh,*Nakysa Hooman, Hasan Otukesh, Rozita Hosieni,
Azar Nickavar, Mahya Goldasteh

How to Cite This Article: Mamizadeh N, Hooman N, Otukesh H, Hosieni R, Nickavar A, Goldasteh M. Clinical Features and Outcome in Children With Primary Hyperoxaluria; Single Center Experience. J Ped. Nephrology 2015;3(3):121-123.

Department of Pediatric Nephrology, Ali-Asghar Children hospital, Iran University of Medical Sciences.
Tehran, Iran.

*Corresponding Author

Nahid Mamizadeh,
Department of Pediatric Nephrology,
Ali-Asghar Children hospital, Iran
University of Medical Sciences.
E-mail: mahya.sobhan@yahoo.com

Primary hyperoxaluria (PH) is a rare autosomal recessive disorder associated with defects in glyoxylate metabolism and overproduction of oxalate. Then, calcium oxalate is deposited in many organs such as the kidney.

Calcium Oxalate is a metabolite end-product. It has a tendency to crystallize in the renal tubules and excretes by the kidney. Overproduction of oxalate, primarily by the liver is the main defect of inherited hyperoxaluria. The earliest symptoms of hyperoxaluria are nephrocalcinosis and urolithiasis, which lead to chronic kidney disease and progressive renal involvement. Renal damage is caused by a combination of nephrocalcinosis and tubular toxicity from oxalate and renal obstruction by nephrolithiasis, often with superimposed urinary tract infection. A second phase of damage in primary hyperoxaluria occurs when the glomerular filtration rate (GFR) drops to 30 to 45 milliliter per minute per 1.73 of body surface area and the kidney is unable to excrete the oxalate load. At this point, plasma levels of oxalate rise and oxalate is subsequently deposited in all tissues particularly in the skeleton and liver [1]. Primary hyperoxaluria (PH) has three types: PH1 (enzyme defect of AGT: alanine glyoxylate aminotransferase) and PH2 (enzyme defect of GRHPR: glyoxylate reductase/hydroxy pyruvate

reductase) and PH3 (non-type 1, non-type 2). Type 1 is more prevalent accounting for about 77% of all patients with PH [2].

Primary hyperoxaluria type 1, has heterogeneous phenotype, is caused by a deficiency of liver-specific peroxisomal enzyme alanine-glyoxylate aminotransferase (AGT), a pyridoxal 5'-phosphate-dependent enzyme, which catalyzes the transamination of glyoxylate to glycine. This deficiency results in the accumulation of glyoxylate and excessive production of both oxalate and glycolate [3]. AGT is a stable homodimer, with its N-terminal amino acids wrapped around the adjacent monomer 8. A common variant, Pro11Leu, creates a stronger N-terminal mitochondrial targeting sequence, which influences the fate of some mutant proteins [1].

Primary hyperoxaluria type 2 is caused by a lack of glyoxylate reductase-hydroxypyruvate reductase (GRHPR), which catalyzes reduction of glyoxylate to glycolate and hydroxypyruvate to D-glycerate. GRHPR has a wide tissue distribution, but it is primarily intrahepatic, presents largely in the cytosol of hepatocytes and to a lesser extent in mitochondria. When there is a deficiency of GRHPR, lactate dehydrogenase metabolizes the accumulated glyoxylate to oxalate and the hydroxypyruvate to L-glycerate.

Primary hyperoxaluria type 3 results from defects in the liver-specific mitochondrial enzyme 4-hydroxy-2-oxoglutarate aldolase (HOGA). This enzyme plays a key role in the metabolism of hydroxyproline, and kinetic studies suggest that the forward reaction, in which 4-hydroxy-2-oxoglutarate (HOG) is converted to pyruvate and glyoxylate, is favored. However, it is unclear why this defect would cause an increase in oxalate levels, since impairment of the synthesis of mitochondrial glyoxylate would be expected. One theory is that the substrate HOG breaks down to oxalate either enzymatically or in some other ways; another is that HOG inhibits mitochondrial GRHPR. The aim of this study was to present the clinical presentation and outcome of children with diagnosis of PHO for better management of these patients. Primary hyperoxaluria may occur at almost any age; the age at diagnosis ranges from less than one year to over 50 years and a median age at presentation is 5.5 years.

The clinical presentation of PH is varied including:

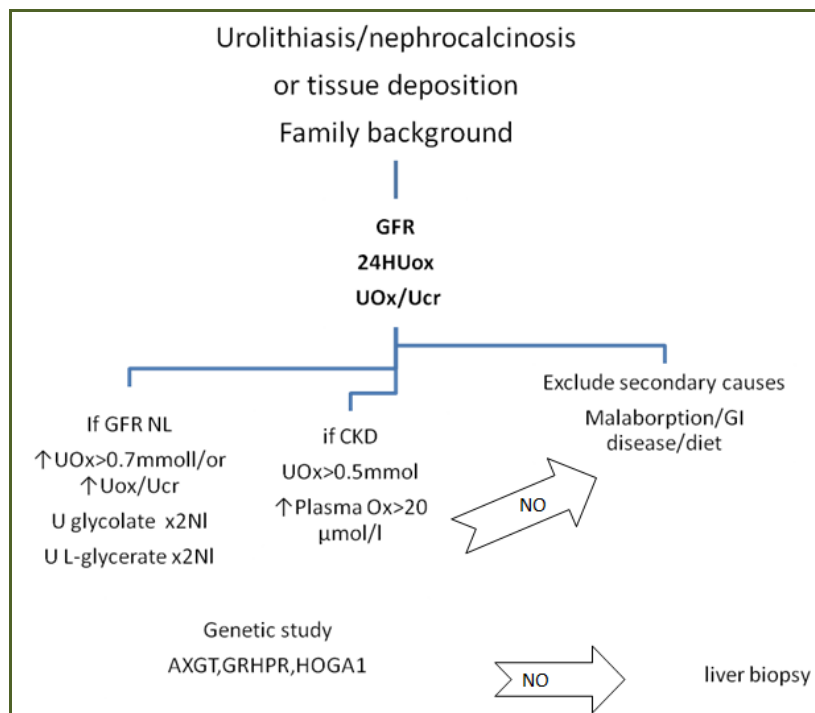
1. Infantile nephrocalcinosis and failure to thrive as a result of renal impairment
2. Recurrent urolithiasis and renal failure in adulthood
3. Occasional stone formation in adulthood
4. Screening subjects with positive family history
5. Post-transplantation recurrence of disease

However, 20% to 50% of patients have advanced chronic kidney disease or even ESRD at the time of diagnosis. Roughly 10% of patients receive a diagnosis of primary hyperoxaluria only when the disease recurs after kidney transplantation. In other cases, the disease is identified before symptoms appear in the course of family evaluations. One of the major organs involved in PH is the kidney, which is because of crystal deposition. Kidney injury, leading to a decrease in GFR, results in chronic kidney failure and ultimately ESRD, together with progressive systemic involvement, blood-vessel walls and bones (with crystal deposits often leading to fractures), joints, retina, skin, bone marrow, heart and central nervous system, leading to severe morbidities and finally mortality. The median age at initiation of renal-replacement therapy is 1.5 years, and the patient survival rate 5 years after the initiation of renal-replacement therapy is 76%, compared with 92% among children with ESRD resulting from other conditions. Primary hyperoxaluria type 1 is the most devastating subtype, particularly when it occurs in infancy, but patients with Gly170Arg or Phe152Ile mutation

have a better overall outcome than those with type 1 disease, partly because of their sensitivity to pyridoxine. A recent trial in 12 genetically confirmed primary hyperoxaluria with GFR > 60 ml/min/1.73 treated with vitamin B6, showed 25 to more than 30% reduction of urine oxalate in 24 months [4]. A large European cohort in 410 patients with AXGT mutation revealed that mutation in G107R and causative factors contribute in late onset end stage renal disease [3]. Patients with primary hyperoxaluria type 2 appear to have a mild course; however, the two types of disorders cannot be distinguished according to age at onset and in some instances, primary hyperoxaluria type 2 is initially assumed to be type 1. Primary hyperoxaluria type 3 has the least severe course and may be silent or limited to stone formation, sometimes even improving over time. Whereas, hyperoxaluria persists in primary hyperoxaluria type 3, nephrocalcinosis and chronic kidney failure are not common and systemic involvement has not been reported. Other factors, including environmental factors and modifier genes, may contribute to the clinical heterogeneity of primary hyperoxaluria [1].

In this cross-sectional single center retrospective study, we reviewed data of all patients with diagnosis of PHO admitted between 2001 and 2012. The diagnosis criteria were: Recurrent/bilateral or unilateral/single or multiple urolithiasis; Urine oxalate (mmol/L) to urine creatinine (mmol/L) more than 95 percentile or 24 hours urine oxalate more than 0.5mmol/1.73/m²; history of calcium oxalate renal stone in relatives or consanguinity of parents, with or without severe chronic kidney disease. From all patients admitted with the diagnosis of urolithiasis or renal failure, 18 patients (12 Females: 67 %, 6 Males: 33%) diagnosed as PHO. The mean age of diagnosis was 4.36 years =52m (ranged 3m-13 y). The clinical presentations were urolithiasis: n=12; 67%) and severe chronic kidney disease (n=6, 33%). Of six patients with CKD, five patients had bilateral nephrocalcinosis. Of six patients with CKD, one patient was found to have PHO by finding oxalate crystals in renal necropsy. The range of creatinine at presentation was 0.3 mg/dL to 10.6 mg/dL. From 12 children with urolithiasis, 75% (n=9) were multiple and 83.3% (n=10) bilateral. Failure to thrive was in 44% (n=8). Family history was positive for either urolithiasis or hyperoxaluria in 55.5% (n=10) and consanguinity of parents reported in 67% (n=12). The patients were

Figure 1. Diagnostic Approach to Hyperoxaluria [2]



GLYCOLATE: 0-31 days: 0-57 mg/g cr ; 1-5 months: 0-54 mg/g cr;6-12 months: 0-60 mg/g cr;1-5 years: 0-89 mg/g cr; > =6 years: 0-78 mg/g cr / **GLYCERATE:** 0-31 days: 0-38 mg/g cr; 1-5 months: 0-71 mg/g cr;6-12 months: 0-56 mg/g cr;1-5 years: 0-17 mg/g cr ; > =6 years: 0-8 mg/g cr / **OXALATE:**0-31 days: 0-301 mg/g cr;1-5 months: 0-398 mg/g cr;6-12 months: 0-280 mg/g cr;1-5 years: 0-128 mg/g cr;6-10 years: 0-72 mg/g cr;> =11 years: 0-56 mg/g cr

GLYOXYLATE: 0-31 days: 0.0-7.9 mg/g cr; 1-5 months: 0.0-11.4 mg/g cr;6-12 months: 0.0-5.5 mg/g cr, 1-5 years: 0.0-3.9 mg/g cr; > =6 years: 0.0-2.9 mg/g cr

Interpretation: type 1: increased concentrations of oxalate and glycolate / **type 2:** Increased concentrations of oxalate and glycerate./**secondary:** Increased concentrations of oxalate with normal concentrations of glycolate and glycerate .

followed up for seven years, seven died with CAPD or HD, one had HD on the time of article writing, four had moderate CKD (creatinine 1.3 to 2.4 mg/dL), three had normal GFR and three were lost to follow-up. Outcome of PHO is poor. High percentage of presentation with renal failure necessitates accurate genetic or enzymatic diagnosis in our country to make earlier precise decision for appropriate intensive treatment. Diagnostic algorithm suggested for evaluation of primary hyperoxaluria and the references values are shown in figure 1 [2].

Conflict of Interest

Authors have no conflict of interest to declare.

Financial Support

Authors have no financial support.

References

1. Cochat P, Rumsby G. Primary Hyperoxaluria. N Engl J Med 2013;369(7):649-658.
2. Leal R, Santos T, Galvão A, Macário F, Pratas J, Cunha FX, Vilarinho L, Campos M. Primary hyperoxaluria type 1: A literature review upon three clinical cases. Port J Nephrol Hypert 2014;28(4):281-289.
3. Mandrile G, van Woerden CS, Berchiolla P, Beck BB, Acquaviva Bourdain C, Hulton SA, Rumsby G; OxalEurope Consortium. Data from a large European study indicate that the outcome of primary hyperoxaluria type 1 correlates with the AGXT mutation type. Kidney Int. 2014;86(6):1197-204.
4. Hoyer-Kuhn H, Kohbrok S, Volland R, Franklin J, Hero B, Beck BB, Hoppe B. Vitamin B6 in primary hyperoxaluria I: first prospective trial after 40 years of practice. Clin J Am Soc Nephrol. 2014;9(3):468-77.