

Photo Quiz

J Ped. Nephrology 2015;3(1):40-41
<http://journals.sbmu.ac.ir/jpn>

A 3 Year old Child Presented with Urinary Retention

A 3 year old male was transferred to pediatric emergency room because of acute urinary retention from one day ago. He had no history of similar problem until now. Physical exam revealed only full bladder. BUN and Creatinine were increased. After urinary catheter insertion, the bladder was decompressed. Kidney ultrasound showed bilateral hydroureteronephrosis. Voiding cystourethrogram (VCUG), TC99m DTPA scan and 99mTc dimercaptosuccinic acid DMSA scan was done after improvement of renal function (Fig. 1,2) and urodynamic study was performed for better evaluation of the bladder (Fig. 3).

What is your diagnosis?

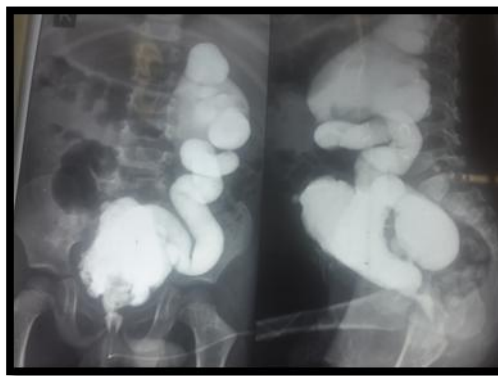


Fig. 1 Patient's VCUG

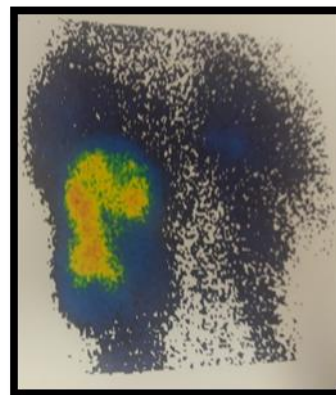


Fig. 2 Patient's DMSA scintigraphy

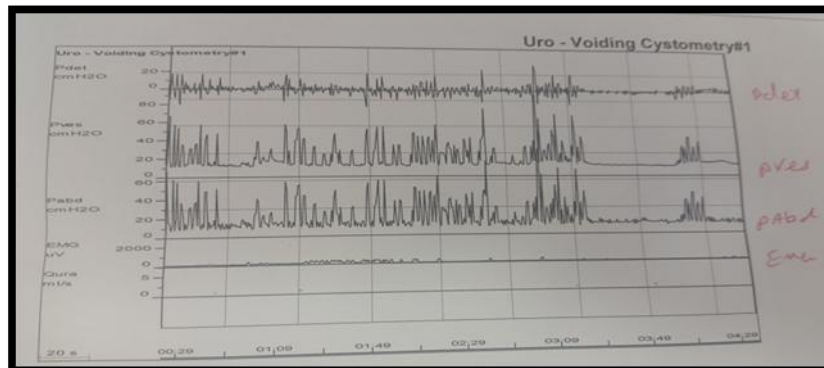


Fig. 3 Patient's Urodynamic study

A 3 Year old Child Presented with Urinary Retention

Leily Mohajerzadeh

How to Cite This Article: Mohajerzadeh L. A 3 Year old Child Presented with Urinary Retention. J Ped. Nephrology 2015;3(1):40-41.

Pediatric Surgery Research Center, Shahid Beheshti University of Medical Sciences, Tehran, Iran

*Corresponding Author

Leily Mohajerzadeh

Mofid Children's Hospital, Shariati Ave. Tehran-Iran.

Tel:00982122227033

Email: mohajerzadehl@yahoo.com

VCUG revealed posterior urethral valve with unilateral high grade VUR and multiple small and large bladder diverticula. In renal scans both kidneys showed severely decreased function with no sign of ureteral obstruction. Urodynamic assessment of this child clearly showed bladder dysfunction. The most common form of anatomical bladder outlet obstruction in the male pediatric population is posterior urethral valves (PUVs). Endoscopic destruction of the valve leaflets can be performed safely in nearly all term infants [1], but this patient referred with prolonged obstruction and bladder dysfunction. The treatment of bladder dysfunction in children with posterior urethral valves depends on the severity and the kind of bladder dysfunction, as well as the efficacy of bladder emptying. Patients with high-pressure voiding dynamics often benefit from the use of anticholinergic medications to improve compliance. In younger patients with an impaired ability to empty the bladder spontaneously, CIC may be required. Although conservative measures are usually effective in modifying bladder dynamics (i.e., keeping bladder volumes sufficiently low to maintain acceptable bladder pressures). A small number of patients may still require bladder augmentation to improve bladder volume and compliance [2].

References

1. Martin Kaefer. Disorders of Bladder Function. In:Coran AG, Adzic NS, Krummel TM, Laberge JM, Shamberger RC, Caldamone AA. Text book of pediatric surgery. 7th Ed Elsevier: Saunders;2012.P: 1453-62.
2. Peter F. Ehrlich, Robert C. Shamberger. Posterior Urethral Valves. In: Holcomb GW, C Murphy PK. Ashcraft's Pediatric Surgery. 6th Ed. Philadelphia:Saunders;2014.P 762-71.