

Photo Quiz

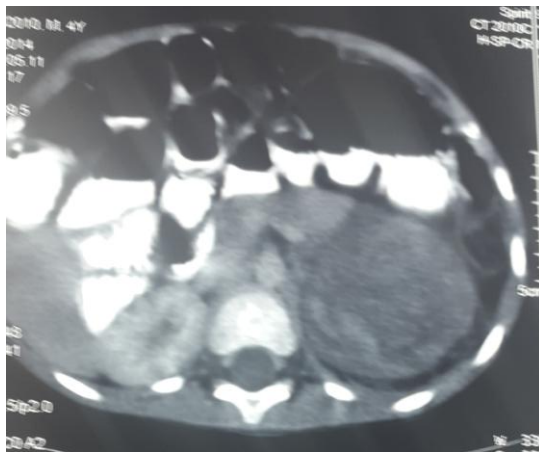
J Ped. Nephrology 2014;2(4):160-161

<http://journals.sbmu.ac.ir/jpn>

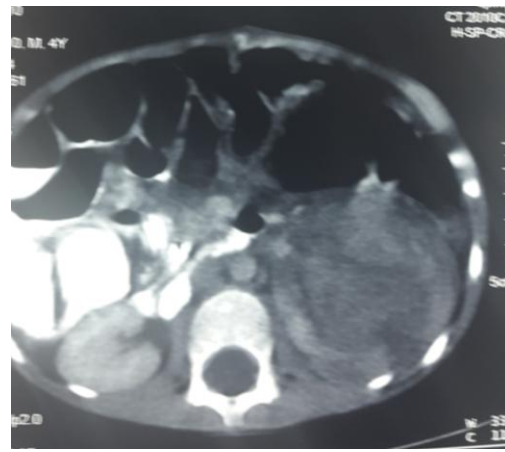
A 4-Year-old Male Presenting with Acute Abdomen

A 4-year-old male was transferred to pediatric emergency room because of acute abdominal pain. He was healthy before and had a history of falling down 2 weeks ago. Physical examination revealed an anxious and ill child with temperature of 37.5°C, pulse of 102/min, respiratory rate of 28/min and blood pressure of 100/70 mmHg. In abdominal exam the patient showed signs of acute abdomen. He was transferred to operating room and the first surgical diagnosis was kidney hematoma. Post operation kidney ultrasound reported large unilateral kidney hematoma. Post operation abdominal CT scan was shown in (Fig.1) (a,b).

What is your diagnosis?



[↑](#) a



[↑](#) b

Figure 1. Abdominal CT scan of the patient

Photo Quiz Answer

A 4-Year-old Male Presenting with Acute Abdomen

Leily Mohajerzadeh

How to Cite This Article: Mohajerzadeh L. A 4-Year-old Male Presenting with Acute Abdomen. J Ped. Nephrology 2014;2(4):160-161.
Pediatric Surgery research center, Shahid Beheshti University of Medical Sciences, Tehran, Iran

*Corresponding Author

Leily Mohajerzadeh
Mofid Children's Hospital, Shariati Ave. Tehran-Iran.
Tel:00982122227033
Email: mohajerzadehl@yahoo.com

CT scan ([Fig.1](#)) shows enlarged left side kidney mass. Ultrasound (not shown) reported organized hematoma. These findings are mostly suggestive of kidney rupture, but we should suspect to underlying disease such as tumor or coagulopathy that leads to this massive hematoma. He underwent surgery and organized hematoma with necrotic tissue revealed. The entire kidney except upper pole was intact. Hematoma was surrounded with gerota fascia. He underwent partial nephrectomy and all the necrotic tissue sent for pathology unit. Pathologist reported ruptured Wilms' tumor.

Most children with Wilms' tumor present with an asymptomatic abdominal mass, often discovered by either a parent or pediatrician. Gross hematuria has been reported in 18.2% of patients and microscopic hematuria in 24.4%. Ten percent of children with Wilms' tumor have coagulopathy, and 20% to 25% present with hypertension because of activation of the renin-angiotensin system. Fever, anorexia, and weight loss occur in 10%. Extension of tumor thrombus into the renal vein can obstruct the spermatic vein and result in a left varicocele and tumor rupture and hemorrhage are also infrequent events that can present as an acute abdomen [1,2].

References

1. Ehrlich PF, Shamberger RC. Wilms' Tumor. In: Coran AG, Adzic NS, Krummel TM, Laberge JM, Shamberger RC, Caldamone AA. Text book of pediatric surgery. 7th edition·Elsevier: Saunders; 2012 P: 423-7
2. Peter F. Ehrlich Robert C. Shamberger. Renal Tumors. In: Holcomb GW ,c Murphy PK. Ashcraft's Pediatric Surgery.6th ed. Philadelphia:Saunders;2014.P:859-79.