

## Case Report

J Ped. Nephrology 2015;3(1):31-34  
<http://journals.sbmu.ac.ir/jpn>

# Amikacin-induced Nephrotoxicity in a Child with Idiopathic Nephrotic Syndrome in Iran: A Case Report

**How to Cite This Article:** Sayarifard A, Javadilarijani F, Mousavi movahhed SM, Moghtaderi M, Javadilarijani F. Amikacin-induced Nephrotoxicity in a Child with Idiopathic Nephrotic Syndrome in Iran: A Case Report. J Ped. Nephrology 2015;3(1):31-34.

**Azadeh Sayarifard,<sup>1</sup>**  
**Faezeh Javadilarijani,<sup>2</sup>**  
**Seyed majid Mousavi movahhed,<sup>3</sup>**  
**Mastaneh Moghtaderi,<sup>2</sup>**  
**Farnia Javadilarijani<sup>4\*</sup>**

1 Preventive and Community Medicine specialist, Center for Academic and Health Policy, Tehran University of Medical Sciences, Tehran, Iran.

2 Pediatric Nephrologist, Pediatric Chronic Kidney Disease Research Center, Tehran University of Medical Sciences, Tehran, Iran.

3 Nephrologist, Tehran University of Medical Sciences, Tehran, Iran.

4 Clinical Psychologist, Science and Research Branch, Islamic Azad University, Tehran, Iran.

### \*Corresponding Authors

- Farnia Javadilarijani, Clinical Psychologist, Science and Research Branch, Islamic Azad University, Tehran, Iran.

Email: f.javadi.larijani@srbiau.ac.ir

- Faezeh Javadilarijani, MD. Pediatric Nephrologist, Tehran University of Medical Sciences, Tehran, Iran.

Email: dr.javadilarijani@yahoo.com

Received: Oct-2014

Revised: Nov-2014

Accepted: Dec-2014

We report an unusual case of Amikacin-induced nephrotoxicity in a child. The patient was a seven and a half year old girl with nephrotic syndrome and cushingoid facial features who was referred to Tehran Children's Medical Center for renal biopsy so as to start cyclosporine therapy for the diagnosis of disease recurrence. Before coming to our center she was admitted to another hospital with complaints of severe abdominal pain and vomiting. In the course of hospitalization in our center, the patient gradually became oliguric and her serum creatinine increased from 0.3 mg/dl to 3.5 mg/dl. During her previous hospitalization about 2 weeks ago, use of amikacin and ceftriaxone was found. There were several reasons for kidney failure in the child, one of which was possibility of amikacin-induced nephrotoxicity. A renal biopsy showed diffuse mesangial proliferative and tubular lesions, which were in favor of amikacin toxicity. It seems that Amikacin can lead to nephrotoxicity if the patient is dehydrated and experiencing reduction of effective vascular volume. Regarding logical use of amikacin, renal function should be monitored regularly.

**Keywords:** Acute Tubular Necrosis; Acute Renal Failure; Acute Tubulointerstitial Nephritis; Nephrotic Syndrome; Amikacin; Iran.

Running Title: Amikacin-induced Nephrotoxicity in Nephrotic Syndrome

## Introduction

Acute renal failure is a rare complication in patients with nephrotic syndrome and many factors may cause it. These factors include: severe intravascular volume depletion, bilateral renal vein thrombosis, acute tubular necrosis, and nephrotoxicity. On the other hand, nephrotoxicity can be a side effect of various drugs. Of course, demonstrating the relationship between nephrotoxicity and a specific drug might be difficult, since in many cases, multiple drugs are administered to a patient simultaneously [1].

Reports of patients with drug-induced nephrotoxicity are available [1-3] and Amikacin is one of them. It is an aminoglycoside antibiotic and plays a major role in the treatment of life-threatening infections, especially infections with gram-negative bacilli. These drugs need dose adjustment in renal failure. Children are vulnerable to the complications of this category of drugs due to their pharmacokinetic and pharmacodynamic differences [4]. We report a

child with amikacin-induced nephrotoxicity which was referred to Tehran Children's Medical Center. Consent was taken from patient and his parents to report the case.

### Case Report

The patient was a seven and a half year old girl with a diagnosis of idiopathic nephrotic syndrome and a cushingoid face caused by steroid use. She had been treated with corticosteroids for one year and was referred for management of disease recurrence and renal biopsy in order to start cyclosporine therapy. Two weeks before admission in our center, she was admitted to another hospital with complaints of severe abdominal pain and vomiting. She was the family's second born child and her birth was by Normal Vaginal Delivery (NVD). Family history revealed diabetes in her grandparents. On admission she had a T=36.4<sup>o</sup>c, PR=108/min, RR=22/min, BP=100/75 mmHg and Weight=29kg. A cushingoid face and pitting edema was also noted. Drug History: she had received amikacin (5 mg/kg q12h) for 10 days during her previous admission 2 weeks ago.

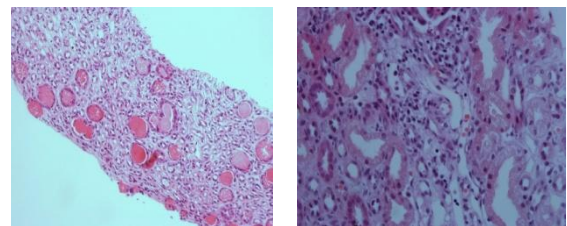
**Laboratory tests:** RBC:  $5.24 \times 10^6$  U/L; Hgb: 14.5 g/dl; PLT:  $633 \times 10^3$ U/L; WBC:  $13.4 \times 10^3$  U/L (N: 66.1% Lym: 27% Mon: 6.3% Eos: 0.5% Bas: 0.1%). Total cholesterol: 628 mg/dl; TG: 548 mg/dl; Amylase: 32; Lipase: 21, C3: 108 mg/dl; C4: 22 mg/dl; CH50: 100 U; ANA: Negative; ANCA: Negative; P- ANCA: Negative; C-ANCA: Negative; Anti-ds-DNA: 23 IU/ml, ESR: 75mm/1h; CRP: 0.5 Alb: 2.9gr/dl, Ca: 8.1mg/dl; P: 3.3mg/dl; Na: 138mEq/l; K: 4.5 mEq/l, PPD: Negative, Chest x-ray was normal.

Because of abdominal pain and vomiting, the patient was started on intravenous ceftriaxone with suspicion of peritonitis. In order to reduce edema, hydrochlorothiazide, Furosemide, spironolactone, and albumin were administered. Creatinine on admission was 0.3 mg/dl but after two days of hospitalization, creatinine increased to 3.5 mg/dl and BUN reached 62 mg/dl and the child gradually became oliguric. Urine analysis showed +2 glycosuria (despite normal serum glucose) and proteinuria but no hematuria. Urine cultures were negative. Increase in serum uric acid was also noted. Doppler ultrasonography of the renal artery showed no thrombosis, but the main renal arteries had a high Resistive Index (RI), which might rise in Acute Tubular Necrosis (ATN) or due to high blood pressure but our

patient never had high blood pressure during hospitalization.

With suspicion of drug-induced nephrotoxicity; ceftriaxone, hydrochlorothiazide, Furosemide, spironolactone, and albumin were discontinued.

The patient gradually became oliguric and her BUN, creatinine and uric acid started to rise, there for steroid pulses (methylprednisolone 30 mg/kg) was administrated for three days with the suspicion of Rapidly Progressive Glomerulonephritis (RPGN) in mind. Meanwhile, the child's hospitalization records and her medical treatments were reviewed. A prescription of amikacin (with a dose of 5 mg/kg q12h for 10 days) was found. Thus, possibility of nephrotoxicity induced by amikacin was raised and the patient underwent a renal biopsy to confirm the diagnosis. Urinary flow was established in patient 2-3 days after cessation of drugs. Rasburicase was administered for high uric acid, and ultimately her uric acid decreased. Supportive treatments were administered to the patient. BUN and creatinine gradually decreased reaching 1 mg/dl. Kidney biopsy pathology report: diffuse mesangial proliferation was seen in glomeruli, RBC casts was seen in some tubules, interstitial inflammation and mild fibrosis was seen; around the vessels, focal perivenular inflammatory cell infiltration was evident without any vasculitis. The pathology was in favor of amikacin toxicity (Fig 1). Considering the nephrologic problems, we preferred to prescribe cyclophosphamide instead of cyclosporine. She was discharged with a good general condition, blood pressure 110/80, good urine output, BUN: 52 mg/dl, Uric acid: 4.9 mg/dl and creatinine: 1mg/dl.



**Figure 1.** Histopathological sections of the kidney ↑

### Discussion

The patient was a seven and a half year old girl with a history of idiopathic nephrotic syndrome who was referred to Tehran Children's Medical

Center. In the course of hospitalization, the patient gradually became oliguric and her serum creatinine level increased. Regarding the clinical symptoms of the patient and her hospitalization history, she was treated with the possible diagnosis of amikacin-induced nephrotoxicity. The renal biopsy result was also in favor of amikacin toxicity. Aminoglycoside-induced nephrotoxicity is defined by tubular necrosis, mesangial cell contraction, basal membrane disruption, proliferation and apoptosis, detected by a decrease in glomerular filtration and alteration in intra glomerular dynamics [5].

Drug-induced nephrotoxicity symptoms are fever, anorexia nervosa and weight loss. Rash, urticaria, and arthralgia are rare. Our patient had manifestations consistent with the symptoms mentioned above. The laboratory tests usually show proteinuria, glycosuria, hematuria, and raised ESR and CRP [1-4]. All of the above mentioned items were also seen in our patient except hematuria. Drugs that are associated with nephrotoxicity include antibiotics, NSAIDs, anticonvulsants, and diuretics [6]. Printza reported an interstitial nephritis case induced by amoxicillin / Clavulanic acid in an 11-year-old girl who had clinical symptoms similar to our case [1]. Chatzikyrkou reported an incidence of Acute Interstitial Nephritis (AIN) in a 65-year-old man due to respiratory tract infection treated with Moxifloxacin [2]. Four cases of AIN caused by Nafcillin were reported by Hoppes [7] and one case caused by rifampicin was reported by Van der Meulen [3]. Incidence of nephrotoxicity due to aminoglycosides has risen from 2-3% in 1969 to 20% in the past decade. Despite nephrotoxicity and ototoxicity, these drugs are still being used in clinical practice because of the antibacterial effect, low cost, and limited bacterial resistance [8].

In a study by Islami et al, it was shown that in monitoring renal performance of the patients treated with amikacin, serum creatinine level was measured before, during and after the course of amikacin only in 17% of patients and 30% of patients did not receive the correct dose of drug based on serum creatinine levels [9]. Baseline serum creatinine measurement prior to initiation of treatment with aminoglycosides and then every 1 to 3 days is essential to evaluate kidney function and diagnosis of drug complication, more monitoring is recommended especially if there is concomitant use of nephrotoxic drugs [4].

Renal Doppler ultrasound, which was performed in our patient, is recommended to evaluate renal artery thrombosis in AIN in patients with active

nephrotic syndrome. Due to clinical manifestations, nonspecific and variable laboratory findings, the importance of renal biopsy is emphasized for AIN diagnosis. Treatment of antibiotic-induced AIN is primarily a supportive treatment including discontinuation of the offending medication and dialysis if required [1].

Using corticosteroid treatment is controversial [1]. It seems that amikacin prescribed to a patient with nephrotic syndrome and dehydration led to nephrotoxicity. It should be noted that low risk drugs should be used in patients who have decreased effective vascular volume rather than amikacin; in order to prevent renal complications. Also, the renal function should be regularly monitored. In the case of our patient, if all drugs administered in the previous hospitalization were mentioned in patient's summary records, the course of diagnosis and treatment would have gone faster. This requires more attention and precision of physicians in writing summary records at the time of patient discharge.

### Acknowledgments

The authors wish to acknowledge all the participants who have helped us prepare this case report.

### Conflict of Interest

None declared

### Financial Support

None declared

### References

1. Printza N, Koukourgianni F, Saleh T, Goga C, Papachristou F. Drug-induced interstitial nephritis in a child with idiopathic nephrotic syndrome. *Saudi J Kidney Dis Transpl* 2009;20(6):1072-5.
2. Chatzikyrkou C, Hamwi I, Clajus C, Becker J, Hafer C, Kielstein JT. Biopsy proven acute interstitial nephritis after treatment with moxifloxacin. *BMC Nephrol* 2010;23;11:19. doi:10.1186/1471-2369-11-19.
3. Van der Meulen J, De Jong GM, Westenend PJ. Acute interstitial nephritis during rifampicin therapy can be a paradoxical response: a case report. *Cases J* 2009;3;2:6643. doi:10.1186/1757-1626-0002-0000006643.
4. Vogelstein B, Kowarski A.A., Lietman P.S. The pharmacokinetics of amikacin in children. *The Journal of pediatrics* 1977;91(2):333-339.
5. Bennett WM, Wood CA, Houghton DC, Gilbert DN. Modification of experimental aminoglycoside

- nephrotoxicity. American J of Kidney Dis 1986; 8:292-6.
6. Perazella MA, Markowitz GS. Drug-induced acute interstitial nephritis. Nat Rev Nephrol 2010; 6(8):461-70. doi:10.1038/nrneph.2010.71.
  7. Hoppes T, Prikis M, Segal A. Four cases of nafcillin-associated acute interstitial nephritis in one institution. Nat Clin Pract Nephrol 2007;3(8):456-61.
  8. Sandhu JS, Sehgal A, Gupta O and Singh A, Aminoglycoside nephrotoxicity revisited. J Indian Acad Clin Med 2007;8(4): 331-333.
  9. Eslami1 G, Salehifar E, Behbudi M, Rezai MS. Rational Use of Amikacin in Buali-Sina Hospital in Sari, 2011. J Mazand Univ Med Sci 2013; 23(100):2-9 (Persian).
  - 10.