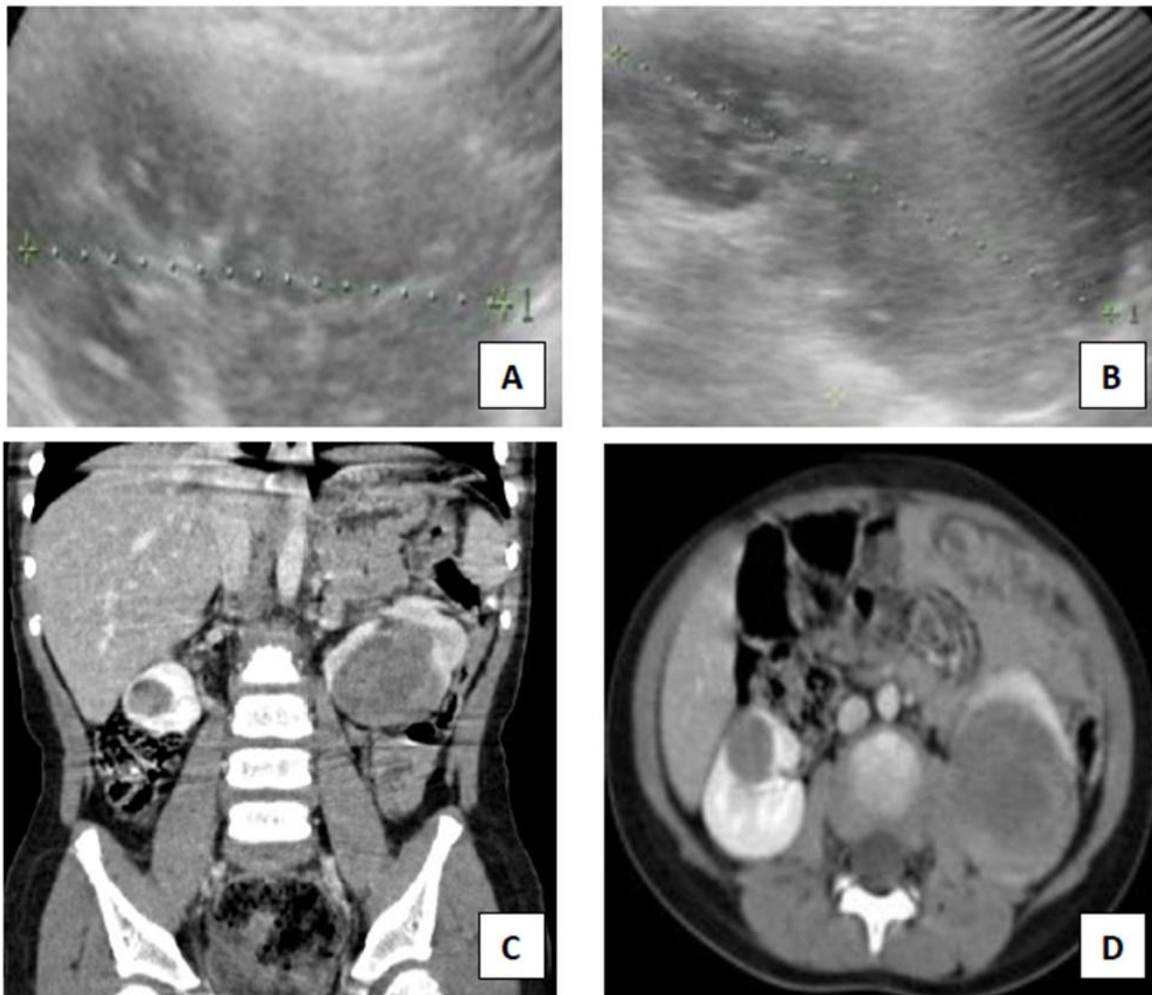


Case Report

<http://journals.sbmu.ac.ir/jpn>

A 3 Year-Old Male Presenting with Hematuria

A 3 year -old boy was admitted because of gross hematuria and abdominal pain. He had been treated with antibiotics over the past 4 days for a presumed lower urinary tract infection. The physical examination showed high blood pressure (BP: 130/95 mmHg) and abdominal mass. The physician performed the abdominal ultrasonography as a first line investigation for hematuria and abdominal pain (fig. A,B). Then he underwent abdominal CT scan for better diagnosis (fig. C, D).



Answer