

Case Report

<http://journals.sbmu.ac.ir/jpn>

A 10 Year-old Male Presenting with Generalized Edema

A 10-year-old male was transferred to hospital because of generalized edema and vomiting. He was healthy until 1 month ago when malaise, anorexia and edema developed. There were positive history of short stature and poor weight gain since childhood in this patient. Physical examination revealed a pale, lethargic, edematous and ill child with temperature of 37.5°C, pulse of 92/min, respiratory rate of 20/min and blood pressure of 160/100 mmHg. His body weight was 23 kg .auscultation of the chest revealed rales in lower parts of lungs, hyperkinetic heart, tachycardia with a III/VI systolic murmur in LSB. The patient had normal abdominal examination. Hypochromic anemia, hyperphosphatemia, increased level of creatinine, potassium and PTH and mild metabolic acidosis were seen in laboratory values. Chest x- ray and abdominal x-ray are shown in figure 1 and 2.

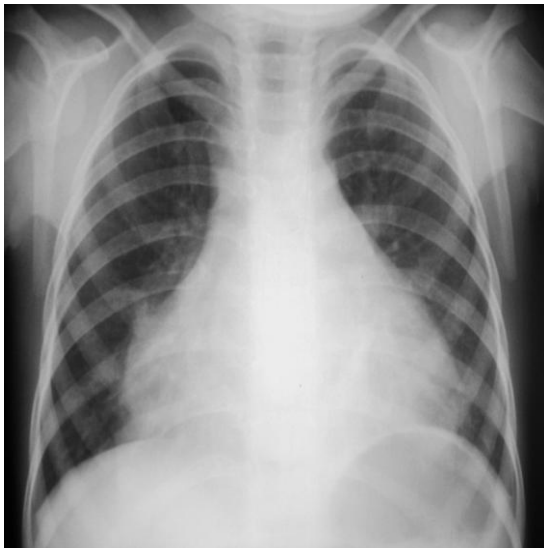


Figure 1. Patient's Chest X Ray [↗](#)

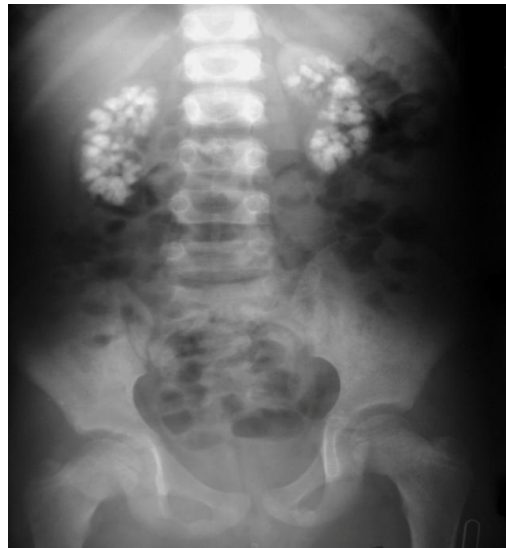

Figure 2. Patient's Abdominal X Ray [↗](#)

Answer