

Photo Quiz

J Ped. Nephrology 2014;2(1):50-51  
<http://journals.sbmu.ac.ir/jpn>

## A 15-Month-Old Female with an Abdominal Mass

A 15-month-old female with an abdominal mass and no other significant findings on physical exam and lab data received abdominopelvic sonography and CT scan with contrast. On abdominal sonography, both kidneys were enlarged with multiple hypoechoic masses of variable sizes with distortion of the renal parenchyma (Figure 1). Abdominopelvic CT scan showed multiple variable sized non enhancing homogeneous masses in both kidneys which had led to renal enlargement. Normal renal parenchyma was merely discernable at the inferior pole of the left kidney and the rest of the parenchyma was noted as linear enhancements between the hypodense masses. Both kidneys excreted the contrast agent into the distorted pyelocalyceal system (Figure 2).

**What is your diagnosis?**

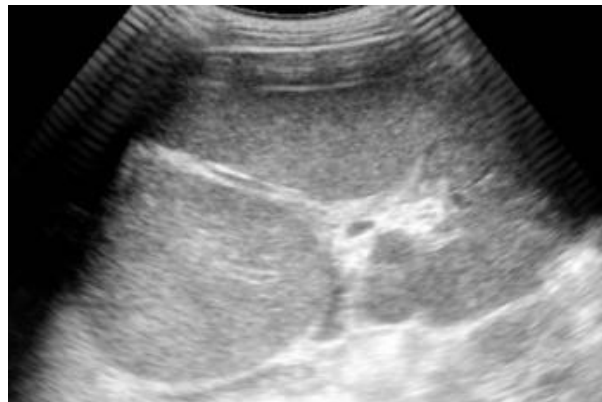

Figure 1. Renal Ultrasonography

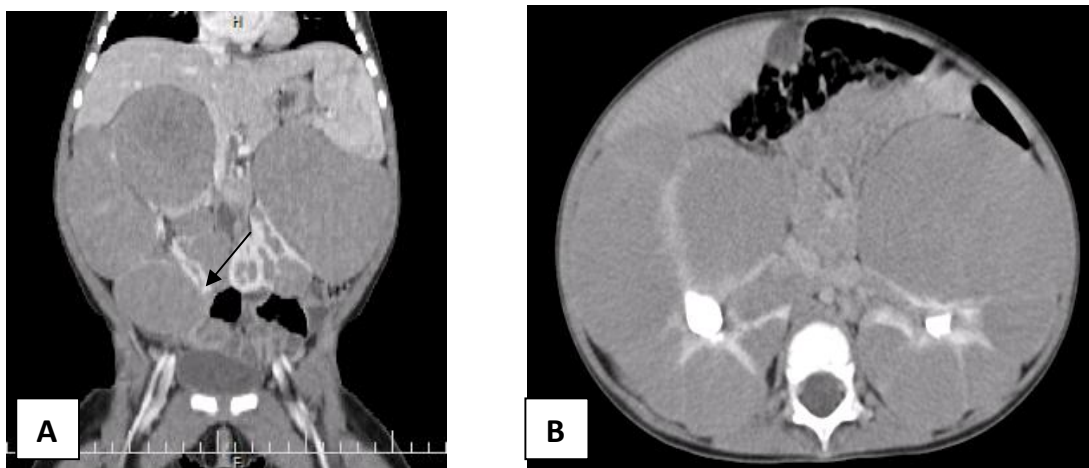


Figure 2. Coronal(A) and Axial(B) contrast enhanced CT scan

## Photo Quiz Answer

# A 15-Month-Old Female with an Abdominal Mass

Roxana Azma,<sup>1\*</sup> Shiva Nazari<sup>2</sup>

**How to Cite This Article:** Azma R, Nazari SH. A 15-Month-Old Female with an Abdominal Mass. J Ped. Nephrology 2014;2(1):132-133.

1 Pediatric Radiology Department, Shahid Beheshti University of Medical Sciences, Tehran, Iran

2 Pediatric Congenital Hematologic Disorder Research Center, Shahid Beheshti University of Medical Sciences, Faculty of medicine, Tehran-Iran

### \*Corresponding Author

Roxana Azma

Mofid Children's Hospital, Tehran-Iran

Email: roxanaazma@gmail.com

Renal sonography showed enlarged kidneys with multiple hypodense masses, and coronal (A) and axial (B) contrast enhanced CT scan showed enlarged and lobulated kidneys with multiple hypodense masses and relative sparing of the inferior pole of the left kidney (black arrow). Nephroblastomatosis was suggested for the patient which was confirmed by biopsy.

Nephroblastoma consists of the foci of persistent embryonal cells called nephrogenic rests. Their distribution can be unifocal, multifocal or diffuse and are associated with 99% of multicentric or bilateral Wilm's tumor [1].

On ultrasonography, nephroblastomatosis is depicted as round areas with mild changes in echogenicity which disrupts the corticomedullary differentiation. However, small lesions are easily missed [2]. On CT scan without contrast, the lesions are isodense to slightly hyperdense relative to cortex [1]. On CT and MRI with contrast, the lesions show homogeneous enhancement which is less than normal renal parenchyma [2].

## References

1. Rohrschneider WK, Weirich A, Rieden K, Darge K, Tröger J, Graf N. US, CT and MR imaging characteristics of nephroblastomatosis. *Pediatric radiology* 1998;28(6):435-43.
2. Riccabona M. Imaging of renal tumours in infancy and childhood. *European radiology* 2003;13(6):L116-L29.