



Successful Treatment of Unilateral Klippel-Trenaunay Syndrome With Pulsed-Dye Laser in a 2-Week Old Infant

Hoda Rahimi, Habib Hassannejad, Hamideh Moravvej*

Skin Research Center, Shahid Beheshti University of Medical Sciences, Tehran, Iran

***Correspondence to**

Hamideh Moravvej, M.D.; Skin Research Center, Shahid Beheshti University of Medical Sciences, Tehran, Iran.
Tel: +98-21 22741507;
Fax: +98-2122744393;
Email:
Hamideh_moravvej@yahoo.com

Published online 28 March 2017



Abstract

Introduction: Klippel–Trenaunay syndrome (KTS) is a rare congenital mesodermal abnormality characterized by varicose veins, cutaneous capillary malformation, as well as bone and soft tissue hypertrophy.

Case Report: A 2-week-old female infant presented to our clinic because of vascular nevus and progressive enlargement of her right extremities and trunk since birth. The patient was treated with 595-nm pulsed-dye laser (PDL). Her port-wine stain (PWS) disappeared completely after third PDL session and the soft tissue hypertrophy stopped. The patient experienced neither recurrence nor any change in size after 7 years of follow up.

Conclusion: PDL can treat KTS completely with no recurrence if it is used in “early stage” of disease.

Keywords: Klippel–Trenaunay syndrome; Laser; Port-wine stain; Vascular malformation.

Introduction

Klippel–Trenaunay syndrome (KTS) is a rare congenital mesodermal abnormality characterized by varicose veins, cutaneous capillary malformation, as well as bone and soft tissue hypertrophy.¹ Usually these symptoms are limited to one extremity; however, multiple extremities, unilateral and even whole body involvement have been described.^{2–6} While lower extremity is the most commonly affected site, the arms, trunk, and rarely the head and neck may be involved, as well.^{7,8}

Early diagnosis is important to avoid complications, such as pulmonary embolism, thrombophlebitis, haemorrhage, stasis dermatitis, and cutaneous ulcerations.⁹

There are absolute and relative indications for treatment of vascular malformations in KTS. The absolute indications include infections, acute thromboembolism, haemorrhage, or refractory ulcers. Relative indications for treatment are pain, functional impairment, swelling due to chronic venous insufficiency, limb asymmetry or cosmetic reasons. The psychological problems of patient and his/her family, caused by a visible deformity of the KTS should not be underestimated and are important indications for treatment.¹⁰

Herein, we report a case of unilateral KTS with early diagnosis and successful treatment with pulsed-dye laser (PDL).

Case Presentation

A 2-week-old female infant presented to our clinic because of vascular nevus and progressive enlargement of her right extremities and trunk since birth. The patient was the result of a normal vaginal delivery at full term, with a birth weight of 3.1 kg. Her parents were non-consanguineous. Her mother denied consumption of any medication during pregnancy. The family history was unremarkable.

Physical examination showed a large, irregular, pink-to-purple patch (compatible with port-wine stain [PWS]) over the right hemiside of her body (trunk, lower and upper extremity) (Figure 1). There was some soft-tissue hypertrophy both in right trunk and right limbs; however, mild difference in limb length was detected only in lower extremity. Color duplex ultrasonography showed no subcutaneous vascular malformation.

The patient was treated with 595-nm PDL at 10–11 J/cm², 1.5–3 ms pulse duration, and 7-mm spot size, for 3 sessions with 3-week intervals. She also received elastic compression dressing for one year. Her PWS disappeared completely after third PDL session and the soft tissue hypertrophy stopped. The patient experienced neither recurrence nor any change in size after 7 years of follow up (Figure 2).

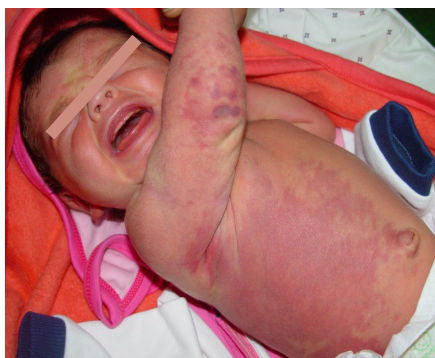

Figure 1. Large port-wine stain and Soft Tissue Hypertrophy (Compatible With Klippel–Trenaunay Syndrome) Over the Right Hemiside of the Body of a 2-Week-Old Infant (Trunk, Lower and Upper Extremity).

Discussion

In this article, we reported a patient with unilateral KTS who presented to our clinic at a very early stage of her disease (when she was only 2 weeks old). The PWS cleared completely after receiving only 3 sessions of PDL with no recurrence after 7 years of follow up. Our experience shows that early intervention at younger age is associated with increased response to PDL.

Management of vascular manifestations of KTS is usually conservative with compression therapy. Although, wearing of compression garments/bandages is efficacious for patients with limb hypertrophy, venous stasis, and phlebitis, their application may cause problems for rapidly growing infants and small children.¹¹ Furthermore, many parents have difficulty in encouraging their child to wear the garment.

PDL is currently the treatment of choice for these capillary malformations. However, the extent to which these lesions may improve varies widely and complete resolution is infrequent.¹²

Woo et al reported only 2% of patients with complete disappearance of lesion after a mean of 17 treatment sessions.¹³

While PDL is very effective in producing initial lightening of PWS lesions, there is a subsequent revascularization after laser therapy that results in frequent treatment failure. This failure has been hypothesized to occur through post-laser angiogenesis via the induction of the hypoxia inducible factor-1a (HIF-1a)¹⁴ and VEGF pathways.^{15,16} Resolution of PWS, as defined by persistent blanching of the lesion, is reported in less than 10%–20% of cases.^{12,17–20} Early intervention is indicated to prevent the development of hypertrophy and nodularity, which has been shown to increase treatment resistance.^{12,21}

Thickened PWS lesions at older age have been associated with increased therapeutic failure.

Sclerotherapy, selective endovenous thermal ablation, surgical stripping, phlebectomy, and occasionally, deep vein reconstructions are other more invasive therapeutic

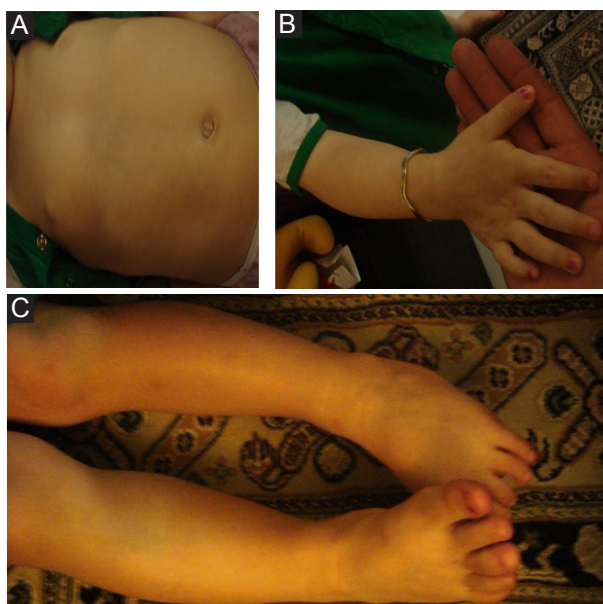


Figure 2. Complete Regression of the Port-wine stain and Cessation of Soft Tissue Hypertrophy in Trunk (A), Upper Limb (B), and Lower Limb (C) After 3 Sessions of Treatment With Pulsed Dye Laser. No recurrence was observed after 7 years.

options for KTS which are recommended to be saved for refractory lesions.

To our knowledge, this is the first case of KTS which is treated with PDL successfully with no recurrence after 7 years of follow up. The use of PDL in “early stage” of disease is the substantial key point, as it results in: (1) decreased risk of treatment failure, (2) decreased risk of recurrence of the lesion, (3) less laser sessions to achieve the complete resolution of the lesion.

Ethical Considerations

Patient’s parents were informed of treatment process and written informed consent was obtained before each laser session.

Conflict of Interests

None to be declared.

References

1. Kihiczak GG, Meine JG, Schwartz RA, Janniger CK. Klippel-Trenaunay syndrome: a multisystem disorder possibly resulting from a pathogenic gene for vascular and tissue overgrowth. *Int J Dermatol.* 2006;45:883-890. doi:10.1111/j.1365-4632.2006.02940.x.
2. Parkes-Weber F. Angioma formation in connection with hypertrophy of limbs and hemi-hypertrophy. *Br J Dermatol Syph.* 1907;19:231–35.
3. Mullins JF, Naylor D, Redetzki J. The Klippel–Trenaunay–Weber syndrome. *Arch Dermatol.* 1962;86:202–206.
4. Glociczki P, Hollier LH, Telander RL, Kaufman B, Bianco AJ, Stickler GB. Surgical implications of Klippel–Trénaunay syndrome. *Ann Surg.* 1983;197:353–362.
5. Lamar LM, Farber GA, O’Quinn SE. Klippel-Trenaunay-Weber Syndrome. *Arch Dermatol.* 1965;91:58–59.

6. Samuel M, Spitz L. Klippel–Trenaunay syndrome:clinical features, complications and management in children. *Br J Surg.* 1995;82:757–61.
7. Lindenauer MS. Congenital arterio-venous fistula and the Klippel–Trenaunay syndrome. *Ann Surg.* 1971;174:248–263.
8. Castro-Magana M, Hernandez-Pérez E. Klippel–Trenaunay–Weber syndrome:a case occurring in the ear and associated with arteriovenous fistulas. *Cutis.* 1980;25:501–502.
9. Chu ST, Han YH, Koh JA, et al. A case of Klippel–Trenaunay syndrome with acute submassive pulmonary thromboembolism treated with thrombolytic therapy. *J Cardiovasc Ultrasound.* 2015;23():266-270. doi:10.4250/jcu.2015.23.4.266.
10. Gloviczki P, Driscoll DJ. Klippel-Trenaunay syndrome: current management. *Phlebology.* 2007;22:291-298.
11. Sung HM, Chung HY, Lee SJ, et al. Clinical Experience of the Klippel-Trenaunay Syndrome. *Arch Plast Surg.* 2015;42:552-558.
12. Marques L, Nunez-Cordoba JM, Aguado L, et al. Topical rapamycin combined with pulsed dye laser in the treatment of capillary vascular malformations in Sturge–Weber syndrome: phase II, randomized, double-blind, intraindividual placebo-controlled clinical trial. *J Am Acad Dermatol.* 2015;72:151–158.e1. doi:10.1016/j.jaad.2014.10.011.
13. Woo WK, Handley JM. Does fluence matter in the laser treatment of port-wine stains? *Clin Exp Dermatol.* 2003;28:556-57.
14. Gao L, Phan S, Nadora DM, et al. Topical rapamycin systematically suppresses the early stages of pulsed dye laser-induced angiogenesis pathways. *Lasers Surg Med.* 2014;46(9):679-688. doi:10.1002/lsm.22296.
15. Nguyen A, Hoang V, Laquer V, Kelly KM. Angiogenesis in cutaneous disease: part I. *J Am Acad Dermatol.* 2009;61:921-942.
16. Laquer VT, Hevezi PA, Albrecht H, et al. Microarray analysis of port wine stains before and after pulsed dye laser treatment. *Lasers Surg Med.* 2013;45(2):67-75. doi:10.1002/lsm.22087.
17. Savas JA, Ledon JA, Franca K. Pulsed dye laser-resistant port-wine stains:Mechanisms of resistance and implications for treatment. *Br J Dermatol.* 2013;168:941-953. doi:10.1111/bjd.12204.
18. Phung TL, Oble DA, Jia W, et al. Can the wound healing response of human skin be modulated after laser treatment and the effects of exposure extended? Implications on the combined use of the pulsed dye laser and a topical angiogenesis inhibitor for treatment of port wine stain birthmarks. *Lasers Surg Med.* 2008;40:1-5.
19. Katugampola GA, Lanigan SW. Five years' experience of treating port wine stains with the flashlamp-pumped pulsed dye laser. *Br J Dermatol.* 1997;137:750-754.
20. Jia W, Sun V, Tran N, et al. Long-term blood vessel removal with combined laser and topical rapamycin antiangiogenic therapy: implications for effective port wine stain treatment. *Lasers Surg Med.* 2010;42:105-112. doi:10.1002/lsm.20890.
21. Ortiz AE, Nelson JS. Port-wine stain laser treatments and novel approaches. *Facial Plast Surg.* 2012;28:611-620.