



# Laser Surgery of Soft Tissue in Orthodontics: Review of the Clinical Trials

Massoud Seifi<sup>1,2</sup>, Negin-Sadat Matini<sup>3\*</sup>

<sup>1</sup>Tayebi Research Center, Marquette University, Wisconsin, USA

<sup>2</sup>Dentofacial Deformities Research Center, Shahid Beheshti University of Medical Sciences, Tehran, Iran

<sup>3</sup>School of Dentistry, Shahid Beheshti University of Medical Sciences, Tehran, Iran

## \*Correspondence to

Negin-Sadat Matini, D.D.S; Dental School, Shahid Beheshti University of Medical Sciences, Tehran, Iran.  
Tel: +98-9122207315;  
Fax: +98 2122749221;  
Email: [negin.matini@hotmail.com](mailto:negin.matini@hotmail.com)

Published online 29 August 2017



## Abstract

**Introduction:** Recently, a wide variety of procedures have been done by laser application in orthodontics. Apart from the mentioned range of various treatments, laser has become a tool for many soft tissue surgeries as an alternative to conventional scalpel-based technique during orthodontic treatments in the management of soft tissue. Due to scarce information in the latter subject, this study was designed in order to include clinical trials that included soft tissue ablation by laser in orthodontics.

**Methods:** Literature was searched based on PubMed and Google Scholar databases in 5 years (2010-2015) with English language restriction and clinical trial design. Studies that performed soft tissue application of laser during orthodontic treatment were extracted by the authors.

**Results:** Only eight studies met the inclusion criteria. No significant difference was found between laser ablation and conventional scalpel technique in the matter of treatment outcome. However, few issues remained to clarify the differences in the mentioned procedures.

**Conclusion:** Laser performance can be recommended in case of preceding less bleeding and discomfort during surgical procedure. There are still quandaries among clinical application of scalpel-based surgery in aesthetic region with bracket-bonded teeth. Precaution and knowledge regarding the characteristics of laser beam such as wavelength, frequency, power and timing is extremely needed.

**Keywords:** Orthodontics; Laser; Soft-tissue ablation.

## Introduction

Laser is a wavelength of light which travels through a collimated tube and delivers a concentration of energy. This energy is then explicated as light. Many elements in periodic table can be used to produce laser irradiation. Different laser systems are able to emit visible lights or invisible lights. The first laser which emits visible light was introduced by Theodore H. Maiman.<sup>1</sup> Visible beams emit laser at (400-780) nm and invisible beams emit at a different spectrum in infrared and ultraviolet ranges. Lasers can be categorized for their properties such as wavelength, laser type, output power and emission type (continuous or pulsed). The difference between irradiation properties can offer different applications. Laser can be classified according to its lasing medium (solid or gas), wavelength (390-700 nm) and tissue applicability (hard tissue and soft tissue).<sup>2</sup> Based on different characteristics, laser has a variety of indication in dentistry including non-surgical sulcular debridement,<sup>3</sup> hard tissue ablation,<sup>4</sup> soft tissue removal,<sup>5</sup> gingival depigmentation,<sup>5,6</sup> ablation

of aphthous ulceration<sup>7</sup> and pain reduction.<sup>8</sup> Numerous studies have focused on laser as an adjunctive procedure in orthodontic practice.<sup>9-11</sup> Many advantages of laser have influenced orthodontic treatments such as accelerating tooth movement,<sup>12</sup> debonding ceramic brackets and soft tissue excision.<sup>13-15</sup> Laser is a beneficial technique in soft tissue surgery compared to scalpel. It coagulates blood vessels, sterilizes the target area and eliminates post operating suture. Studies have reported less post-operative pain and discomfort and also reduction in use of analgesics and local anesthetic drugs in laser surgery.<sup>16-18</sup> However, there are still some disadvantages in regard to adjunctive laser treatment in orthodontics. Application of laser is limited due to the high cost of laser devices.<sup>2</sup> Some clinicians also prefer scalpel because of its tactile sense. Soft tissue ablation is another issue in non-experienced operators. Lack of operating knowledge may cause excessive thermal damage to the tissue and cause bone exposure.<sup>19</sup> Some studies found no difference between conventional scalpel techniques and laser.<sup>20-23</sup>

Common types of laser in soft tissue applications are diode and erbium lasers.<sup>24</sup> Each laser has different wavelengths and input powers which can be used for either soft tissue or hard tissue surgery. Diode laser is almost always used for soft tissue ablation due to its high absorption in soft tissue and low absorption in bone and generally hard tissue.<sup>22,23</sup> This property leads to less damage to hard tissue by diode laser.

The most common erbium laser is erbium-doped yttrium aluminum garnet (Er:YAG). The wavelength range of erbium laser (2780-2940 nm) is much higher than in diode laser (810-980 nm). It can be absorbed by hydroxyapatite and can ablate hard tissue as well. Soft tissue excision in diode laser requires less input power compared to erbium laser.

During recent years, many studies investigated various indications of soft tissue ablation by laser, which are related to orthodontic treatments. Common purposes are frenal excision,<sup>25,26</sup> gingivectomy, surgical uncovering, fibrotomy, and removal of gingival hypertrophy/hyperplasia.<sup>9,27-30</sup> Most investigations are case reports and case series with limited sample size which cannot compare laser with traditional techniques.

The aim of this review is to focus on recent clinical trials applying laser in soft tissue procedures needed in orthodontic practice and to compare different methods of application. Another purpose of this study is to compare laser to the previous techniques used for soft tissue excision.

## Methods

This review is designed to collect adequate researches from PubMed and Google Scholar databases which were published from 2010 to 2015. Keywords based on MeSH terms were gingivectomy, labial frenum, lingual frenum, "soft tissue AND orthodontics", "laser AND surgical uncovering", "gingival hyperplasia" and "gingival hypertrophy". Studies eligible for this review presented the following criteria: (1) Full text in English, (2) prospective randomized clinical trial and non-randomized clinical trial, and (3) studies only on human.

Data extraction was conducted by 2 different authors who independently analyzed the search. Based on PRISMA diagram, a total of 8 articles from 97 qualified for the final analysis. Figure 1 shows the flowchart diagram of clinical trial selection. For each study, year of publication, experimental and control groups, type of laser assessment, treatment indications, age of patients, total number of patients and conclusion were extracted.

## Results

In this review, we included 8 articles. Patients' age ranged between 10 and 32 years old. Table 1 shows a summary of clinical trials that were included in this study. Four studies used laser for gingivectomy<sup>10,29,31,32</sup> and 2 studies reported labial frenectomy.<sup>19,32</sup> Lingual frenectomy was investigated by 2 articles.<sup>32,33</sup> Surgical exposure of delayed tooth eruption was done by Seifi et al<sup>9</sup> and Ize-Iyamu et

al.<sup>32</sup> One of the studies compared laser with conventional scalpel technique for fibrotomy and the result showed efficacy of laser-aided fibrotomy in reducing rotational relapse.<sup>30</sup> In another study, laser operculectomy was done for one patient.<sup>32</sup> Six studies used diode laser.<sup>9,10,29,31-33</sup>

Junior et al used neodymium-doped yttrium aluminum garnet (Nd:YAG) laser for labial frenectomy in comparison with conventional surgical procedure.<sup>19</sup> Jahanbin et al used Er:YAG laser for fibrotomy.<sup>30</sup> Aras et al compared the effect of Er:YAG laser with diode laser in lingual frenectomy.<sup>33</sup> Although most articles applied diode laser in their procedures, there are differences among characteristics of irradiated diode laser exclusively in wavelengths and input power of lasers.

There was no significant difference in treatment outcomes between surgical laser intervention and conventional surgical techniques for the purpose of removing soft tissue in orthodontics. Laser is an advantageous device in reduction of bleeding during procedure, less anesthetic infiltration, hemostasis improvement and avoiding suturing.<sup>17</sup> Some studies claimed that laser decreased postoperative pain.<sup>31</sup> Four studies only used topical anesthesia in laser groups.<sup>10,29,31,32</sup> Aboelsaad and Attia<sup>29</sup> used topical anesthetic gel and applied local anesthesia injection when needed, but the author did not mention how many patients finally got the injection. Two articles used topical anesthetic and local infiltration for all patients.<sup>9,19</sup> Jahanbin et al used infiltration in target area.<sup>30</sup> Aras et al applied laser without any local anesthetic initially and compared diode laser with Er:YAG laser in treatment of tongue-tie. Sixteen patients were enrolled to this study in order to evaluate the acceptability of performing lingual frenectomy without the use of local anesthesia.<sup>33</sup> However, 6 patients in diode laser group required local anesthesia at the beginning of the operation; but also, six patients out of eight in Er:YAG group did not require any local anesthesia during the procedure.

Seifi et al suggested the use of diode laser as an adjunct

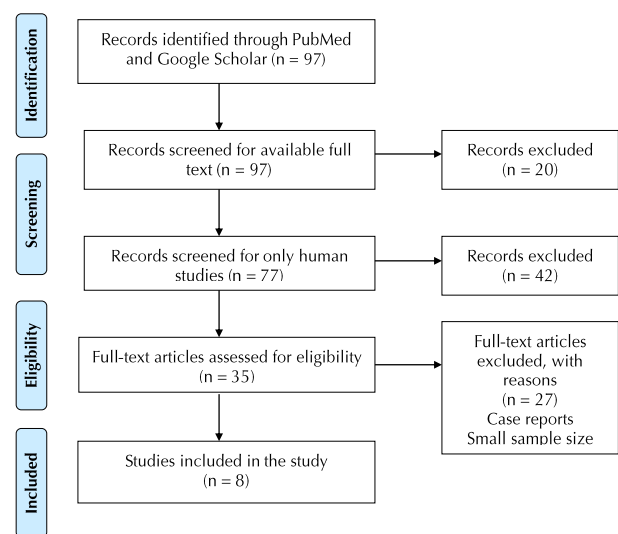


Figure 1. The Flowchart Diagram of Selected Clinical Trials.

**Table 1.** Summary of Clinical Trials Involved in the Study

Author	Year	Journal	Sample Size	Laser Type	Wavelength (nm)	Power (W)	Diameter (mm)	Indication
Aras et al <sup>33</sup>	2010	<i>Photomed Laser Surg</i>	16	Er:YAG Diode	2940 808	1W 2W	- -	Lingual frenectomy
Seifi et al <sup>9</sup>	2013	<i>J Lasers Med Sci</i>	16	Diode	810	1.6	0.3	Gingival uncovering in delayed eruption of second premolar
To et al <sup>10</sup>	2013	<i>Angle Orthod</i>	30	Diode	940	1	0.3	Gingivectomy
Ize-iyamu et al <sup>32</sup>	2013	<i>Ghana Med J</i>	23	Diode	810	-	-	Aesthetic recontouring Gingivectomy Maxillary frenectomy Operculectomy Surgical exposure
Aboelsaad and Attia <sup>29</sup>	2013	<i>Eur Sci J</i>	38	Diode	810	2.5	0.4	Gingivectomy
Sobouti et al <sup>31</sup>	2014	<i>Prog Orthod</i>	30	Diode	940	0.9	0.4	Cosmetic smile lift gingivectomy
Junior et al <sup>19</sup>	2013	<i>Lasers Med Sci</i>	40	Nd:YAG	1064	4		Labial frenectomy
Jahanbin et al <sup>30</sup>	2014	<i>Am J Orthod Dentofacial Orthop</i>	24	Er:YAG	2940	100 mJ	1.1	fiberotomy

to orthodontic treatment.<sup>9</sup> Sixteen patients with delayed second premolar eruption were included in the study. Eight patients received laser irradiation for surgical uncovering. Results showed good gingival status and preserved biological width after the treatment. Data showed that laser intervention significantly accelerated tooth eruption.

In another study, To et al compared adjunctive diode laser gingivectomy to non-surgical periodontal treatment in patients with fixed orthodontic appliance.<sup>10</sup> The difference between the experimental and control groups was only significant at the early stages of treatment, which showed significant improvement in periodontal health in the laser group. Based on the results, diode laser gingivectomy can produce greater periodontal health, earlier.

In a study performed by Ize-Iyamu et al,<sup>32</sup> 23 patients were treated with different soft tissue procedures such as frenectomy, surgical exposure, gingivectomy and operculectomy. The mentioned study did not focus on a specific laser indication in soft tissue treatments. Twelve patients among 23 received soft tissue laser intervention. Postoperative pain and bleeding were significantly reduced in diode laser group. Based on the results, only two operations in diode laser group required anesthetic infiltration. Procedural time was not statistically significant between conventional and laser groups.

Aboelsaad and Attia<sup>29</sup> applied diode laser in hyperplastic gingivae, which were induced by orthodontic treatments. This study was conducted on 38 individuals who were divided in laser group and nonsurgical periodontal group for treatment of gingival enlargement. There was no significant difference between periodontal health between the 2 groups; however, improved periodontal parameters were more evident in earlier stages of the laser group.

Thirty patients were treated in a study by Sobouti et

al with the indication of esthetic-only gingivectomy in anterior maxilla region.<sup>31</sup> Fifteen patients received laser-assisted surgery by diode laser, and conventional surgery by scalpel was conducted for the control group. The experimental group had no postoperative pain and bleeding rate significantly decreased in the laser group. The study suggested the use of laser in patients for cosmetic smile lift surgeries.

Junior et al compared Nd:YAG laser to conventional surgery in labial frenectomy.<sup>19</sup> This study showed no significant difference in postoperative pain or oral function between scalpel technique and laser groups among 40 patients. Differences were found in transoperative bleeding and surgical treatment time, which were reduced in laser group. Another advantage of laser was sutures avoidance. In a study conducted by Jahanbin et al,<sup>30</sup> the efficacy of laser-aided circumferential supracrestal fiberotomy (CSF) was compared with conventional method of CSF in reducing relapse of corrected orthodontic rotation. Twenty-four patients who were at the finishing stage of orthodontic treatment were included in this study. Laser-aided CSF was done on 6 patients with Er:YAG laser (Smart 2940D; Deka Laser, Florence, Italy; 2940 nm, 100 mJ energy). After one month, the degree of relapse was calculated with photographs taken from dental models. The amount of relapse was not significantly different between laser group and conventional CSF technique. However, pain was evaluated to be greater in conventional CSF group.

## Discussion

In recent years, studies regarding laser-aided procedures in orthodontics have increased. However, clinical trials comparing different laser irradiation methods together or with conventional surgical methods are still rare. The

limited number of references is due to the difficulty in designing a clinical trial and the lack of samples included in criterion.

The most common laser used in the clinical trials we studied was diode laser. Diode laser is poorly absorbed by teeth and bone, which makes this laser eligible for soft tissue ablation and makes it a safer procedure due to its lower risk of damage to hard tissue underneath the targeted soft tissue. Diode laser have been used for many operations including gingivectomy, removing inflamed and hyperplastic soft tissue, gingival exposure of impacted tooth and frenal detachment. However, studies applied a variety of wavelengths, input power and tip diameters. Based on recent clinical trials, we could not confirm the exact wavelength or other properties that could be introduced for different indications.

Junior et al used Nd:YAG laser instead of famous diode laser. Nd:YAG has been effective in cutting and coagulating soft tissue.<sup>2</sup> It provides hemostasis and good visibility of tissue during procedure.<sup>34</sup> Histopathological specimens showed better incision quality and less tissue injuries with higher frequency and lower input power.<sup>35</sup> However, diode lasers also showed to be advantageous in excision of soft tissue.<sup>36</sup> Aras et al reported the comparison between diode laser and Er:YAG. Results indicated that Er:YAG could be performed without local anesthetic injection.<sup>33</sup> This characteristic can make it more advantageous than diode laser application, especially in pediatric dentistry.<sup>37</sup> However, the author of the present study suggested the use of local anesthetic injection in some indication such as surgical exposure. The needling demonstrated the depth of soft tissue over the crown of delayed erupted tooth which prevented thermal damage of laser tip over the tooth to underlying tissues, and estimated the amount of tissue that needed to be excised. Most articles have applied topical anesthesia before or without the infiltration of local anesthesia. However, the types of topical anesthetic drugs are not the same. Junior et al and Aboelsaad and Attia<sup>29</sup> have used benzocaine 20% compared with Seifi et al, To et al<sup>10</sup> and Sobouti et al<sup>31</sup> that have applied tetracaine-adrenaline-cocaine also called as TAC 20% (lidocaine 20%, tetracaine 4%, and phenylephrine 2%). Other authors did not mention the type of topical anesthetic that was used. It is required to use a compound topical anesthetic gel in order to obtain adequate soft tissue anesthesia for laser incision such as TAC and lidocaine, prilocaine, tetracaine and phenylephrine with thickeners (profound PET). It is not proved that topical anesthetic gels can be applied for laser incisions without any administration of local anesthesia infiltration. Based on Junior et al local infiltration is indicated when the frenum is long, thick or exhibits gingival, papillary or transpapillary insertion. Therefore, the area of procedure is another concern to assess the type of anesthesia. Hence, the depth of anesthesia in the tissue that can be anesthetized by topical gels which needs to be applied prior to an infiltration technique is not sufficient.<sup>9,33</sup> There is still controversy on whether Er:YAG or Nd:YAG can be applied without

any need for local anesthetic injection.<sup>19,38</sup> Another characteristic concerning the application of Er:YAG laser in soft tissue ablation is its high absorbance by water and mineral apatite.<sup>25</sup> Some studies reported bone exposure, thus, it should not be used in contact with bone or tooth.<sup>19</sup> Risk of thermal damage to hard tissue by this type of laser is enhanced in procedures such as labial frenectomy adjacent to papillary region, aesthetic gingivectomy of anterior maxilla or surgical exposure of delayed erupted tooth. In the mentioned cases, care must be taken to apply lasers which have less absorbance in hard tissue minerals and water, in aesthetic areas. Ankyloglossia treatment is a safer target for such lasers.<sup>33,39</sup> Operator's attention and experience is another major concern during laser irradiation. Clinician must avoid laser irradiation of periosteum or bone structure. Studies are needed to compare Nd:YAG and Er:YAG lasers with diode lasers to prove the efficacy of different type of lasers.

Analgesic administration is almost necessary after any surgery in order to control postoperative pain. Many studies claimed that laser prevents the requirement for prescribing medications in postoperative periods.<sup>31,32,38,40</sup> This could be attributed to less traumatic procedures done by laser.<sup>41</sup> However, some authors prefer the use of analgesic even after laser procedure.<sup>10,19</sup> Some authors believe that depending on the individual factors such as pain threshold, discomfort perceive and extension of the surgical site, over the counter (OTC) analgesics can be used postoperatively as PRN medicines.

Gingival hyperplasia is a very common condition in patients with fixed orthodontics.<sup>28</sup> We believe that administration of surgical laser for removal of hyperplastic gingiva following orthodontic treatments can break the vicious circle that is produced by plaque accumulation which leads to deteriorating the condition. By breaking the above mentioned circle i.e. application of laser for removal of hyperplastic or hypertrophic gingival tissues; less plaque accumulation and consequently less inflammation will exist in the region that is usually underneath of the brackets or with limited access for maintaining oral health. Ease of application, less discomfort during and after the surgeries are among the reasons for this type of interventions or gingivectomies.

Gingival enlargement is also prone to bleeding which may induce the risk of infection transmission between patient and clinician during scalpel technique. Fortunately, laser can maintain a bloodless incision, coagulation and non-contacted tip (if indicated), which may reduce the risk of infection transmission. The ability to produce better infection control by laser ablation can be expanded in cases which needs several surgical procedures during orthodontic treatment duration compared with scalpel-technique which is not enough satisfying for patients.

Excessive bleeding produces less visibility of the area for the operator and causes discomfort for the patient. Some studies claimed that tissue excision by laser shows greater visibility compared to scalpel surgery due to minimized bleeding by laser cut.<sup>34</sup> Shifting from conventional surgical

removal of hyperplastic gingiva in orthodontic induced hyperplasia to laser surgery means diminishing bleeding, better control of infection, and in summary changing the setting from operating room to dental chairside. It means that the same practitioner (i.e. orthodontist) possibly can intervene; which in turn reduces the cost of procedure (referral to periodontist or oral and maxillofacial surgeon). It is also a clinical dilemma, how a scalpel blade can be parallel to root surface when bonded brackets still exist on the teeth. This makes a challenging condition for surgeon, especially in aesthetic region (i.e. anterior maxilla). It is more comfortable to apply laser on teeth with fixed orthodontics due to non-contact laser tip and the ability for the operator to have more freedom in hand position. It is included that surgical laser is an adjunct to the orthodontic treatment for enhancing the result of the rendered service. Controlled removal of soft tissue over impacted or unerupted teeth (with or without fibrotic tissue as a physical barrier on them), gingivectomies for crown lengthening or gummy smile corrections, and gingival zenith positioning are many examples of application of laser during orthodontic treatment.

### Conclusion

In the past few years, studies regarding laser administration have been in majority throughout orthodontic field. However, there are still controversies in application of laser and its comparison with conventional scalpel technique in soft tissue surgeries. Introducing an appropriate laser with suitable wavelength, input power and other properties for mentioned indications needs more research and clinical trials. In an era of advanced technology, some clinicians still prefer conventional scalpel technique over laser-assisted surgery. The potential benefits of laser should be analyzed versus its costs in future studies.

### Ethical Considerations

The present study was approved by ethical committee of institutional review board.

### Conflict of Interests

The authors declare that there is no conflict of interest.

### References

- Maiman TH. Stimulated optical radiation in ruby. 1960.
- Verma SK, Maheshwari S, Singh RK, Chaudhari PK. Laser in dentistry: An innovative tool in modern dental practice. *Natl J Maxillofac Surg.* 2012;3(2):124-132. doi:10.4103/0975-5950.111342.
- Dukic W, Bago I, Aurer A, Roguljic M. Clinical effectiveness of diode laser therapy as an adjunct to non-surgical periodontal treatment: a randomized clinical study. *J Periodontol.* 2013;84(8):1111-1117. doi:10.1902/jop.2012.110708.
- Stubinger S. Advances in bone surgery: the Er:YAG laser in oral surgery and implant dentistry. *Clin Cosmet Investig Dent.* 2010;2:47-62.
- Agrawal AA. Esthetic crown lengthening with depigmentation using an 810 nm GaAlAs diode laser. *Indian J Dent.* 2014;5(4):222-224. doi:10.4103/0975-962x.144739.
- Basha MI, Hegde RV, Sumanth S, Sayyed S, Tiwari A, Muglikar S. Comparison of Nd:YAG Laser and Surgical Stripping for Treatment of Gingival Hyperpigmentation: A Clinical Trial. *Photomed Laser Surg.* 2015;33(8):424-436. doi:10.1089/pho.2014.3855.
- Vale FA, Moreira MS. Low-level laser therapy in the treatment of recurrent aphthous ulcers: a systematic review. 2015;2015:150412. doi:10.1155/2015/150412.
- Yoo YJ, Shon WJ, Baek SH, Kang MK, Kim HC, Lee W. Effect of 1440-nanometer neodymium: yttrium-aluminum-garnet laser irradiation on pain and neuropeptide reduction: a randomized prospective clinical trial. *J Endod.* 2014;40(1):28-32. doi:10.1016/j.joen.2013.07.011.
- Seifi M, Vahid-Dastjerdi E, Ameli N, Badiie M-R, Younessian F, Amdjadi P. The 808 nm laser-assisted surgery as an adjunct to orthodontic treatment of delayed tooth eruption. *J Lasers Med Sci.* 2013;4(2):70.
- To TN, Rabie AB, Wong RW, McGrath CP. The adjunct effectiveness of diode laser gingivectomy in maintaining periodontal health during orthodontic treatment. *Angle Orthod.* 2013;83(1):43-47. doi:10.2319/012612-66.1.
- Seifi M, Vahid-Dastjerdi E. Tooth movement alterations by different low level laser protocols: a literature review. *J Lasers Med Sci.* 2015;6(1):1-5.
- Seifi M, Shafeei HA, Daneshdoost S, Mir M. Effects of two types of low-level laser wave lengths (850 and 630 nm) on the orthodontic tooth movements in rabbits. *Lasers Med Sci.* 2007;22(4):261-264. doi:10.1007/s10103-007-0447-9.
- Dostalova T, Jelinkova H, Sulc J, et al. Ceramic bracket debonding by Tm:YAP laser irradiation. *Photomed Laser Surg.* 2011;29(7):477-484. doi:10.1089/pho.2010.2870.
- Macri RT, de Lima FA, Bachmann L, et al. CO2 laser as auxiliary in the debonding of ceramic brackets. *Lasers Med Sci.* 2015;30(7):1835-1841. doi:10.1007/s10103-014-1688-z.
- Saito A, Namura Y, Isokawa K, Shimizu N. CO2 laser debonding of a ceramic bracket bonded with orthodontic adhesive containing thermal expansion microcapsules. *Lasers Med Sci.* 2015;30(2):869-874. doi:10.1007/s10103-013-1482-3.
- Kumar R, Jain G, Dhodapkar SV, Kumathalli KI, Jaiswal G. The Comparative evaluation of patient's satisfaction and comfort level by diode laser and scalpel in the management of mucogingival anomalies. *J Clin Diagn Res.* 2015;9(10):Zc56-58. doi:10.7860/jcdr/2015/14648.6659.
- Akpinar A, Toker H, Lektetur Alpan A, Calisir M. Postoperative discomfort after Nd:YAG laser and conventional frenectomy: comparison of both genders. *Aust Dent J.* 2015. doi:10.1111/adj.12333.
- Fabre HS, Navarro RL, Oltramari-Navarro PV, et al. Anti-inflammatory and analgesic effects of low-level laser therapy on the postoperative healing process. *J Phys Ther Sci.* 2015;27(6):1645-1648. doi:10.1589/jpts.27.1645.
- Junior RM, Gueiros LA, Silva IH, de Albuquerque Carvalho A, Leao JC. Labial frenectomy with Nd:YAG laser and conventional surgery: a comparative study. *Lasers Med Sci.* 2015;30(2):851-856. doi:10.1007/s10103-013-1461-8.
- Ribeiro FV, Cavaller CP, Casarin RC, et al. Esthetic treatment of gingival hyperpigmentation with Nd:YAG laser or scalpel technique: a 6-month RCT of patient and professional assessment. *Lasers Med Sci.* 2014;29(2):537-

544. doi:10.1007/s10103-012-1254-5.
21. Turer CC, Ipek H, Kirtiloglu T, Acikgoz G. Dimensional changes in free gingival grafts: scalpel versus Er:YAG laser-a preliminary study. *Lasers Med Sci.* 2015;30(2):543-548. doi:10.1007/s10103-013-1349-7.
  22. Fekrazad R, Nokhbatolfoghahaei H, Khoei F, Kalhori KA. Pyogenic granuloma: surgical treatment with Er:YAG Laser. *J Lasers Med Sci.* 2014;5(4):199-205.
  23. Mathur E, Sareen M, Dhaka P, Baghla P. Diode Laser Excision of Oral Benign Lesions. *J Lasers Med Sci.* 2015;6(3):129-132. doi:10.15171/jlms.2015.07
  24. Kravitz ND, Kusnoto B. Soft-tissue lasers in orthodontics: an overview. *Am J Orthod Dentofacial Orthop.* 2008;133(4 suppl):S110-114. doi:10.1016/j.ajodo.2007.01.026
  25. Gontijo I, Navarro RS, Haypek P, Ciamponi AL, Haddad AE. The applications of diode and Er:YAG lasers in labial frenectomy in infant patients. *J Dent Child (Chic).* 2005;72(1):10-15.
  26. Haytac MC, Ozcelik O. Evaluation of patient perceptions after frenectomy operations: a comparison of carbon dioxide laser and scalpel techniques. *J Periodontol.* 2006;77(11):1815-1819. doi:10.1902/jop.2006.060043
  27. De Santis D, Gerosa R, Graziani PF, et al. Lingual frenectomy: a comparison between the conventional surgical and laser procedure. *Minerva Stomatol.* 2013.
  28. Gama SK, De Araujo TM, Pozza DH, Pinheiro AL. Use of the CO<sub>2</sub> laser on orthodontic patients suffering from gingival hyperplasia. *Photomed Laser Surg.* 2007;25(3):214-219. doi:10.1089/pho.2007.2034
  29. Aboelsaad N, Attia N. Diode laser treatment of orthodontically induced gingival hyperplasia. a randomized controlled clinical trial. *Eur Sci J.* 2013;9(27):107-114.
  30. Jahanbin A, Ramazanzadeh B, Ahrari F, Forouzanfar A, Beidokhti M. Effectiveness of Er:YAG laser-aided fiberotomy and low-level laser therapy in alleviating relapse of rotated incisors. *Am J Orthod Dentofacial Orthop.* 2014;146(5):565-572. doi:10.1016/j.ajodo.2014.07.006.
  31. Sobouti F, Rakhshan V, Chiniforush N, Khatami M. Effects of laser-assisted cosmetic smile lift gingivectomy on postoperative bleeding and pain in fixed orthodontic patients: a controlled clinical trial. *Prog Orthod.* 2014;15:66. doi:10.1186/s40510-014-0066-5.
  32. Ize-Iyamu I, Saheeb B, Edetanlan B. Comparing the 810nm diode laser with conventional surgery in orthodontic soft tissue procedures. *Ghana Med J.* 2014;47(3):107-111.
  33. Aras MH, Goregen M, Gungormus M, Akgul HM. Comparison of diode laser and Er:YAG lasers in the treatment of ankyloglossia. *Photomed Laser Surg.* 2010;28(2):173-177. doi:10.1089/pho.2009.2498.
  34. Ilaria G, Marco M, Elisabetta M, et al. Advantages of new technologies in oral mucosal surgery: an intraoperative comparison among Nd:YAG laser, quantal molecular resonance scalpel, and cold blade. *Lasers Med Sci.* 2015. doi:10.1007/s10103-015-1769-7.
  35. Vescovi P, Corcione L, Meleti M, et al. Nd:YAG laser versus traditional scalpel. A preliminary histological analysis of specimens from the human oral mucosa. *Lasers Med Sci.* 2010;25(5):685-691. doi:10.1007/s10103-010-0770-4.
  36. Angiero F, Parma L, Crippa R, Benedicenti S. Diode laser (808 nm) applied to oral soft tissue lesions: a retrospective study to assess histopathological diagnosis and evaluate physical damage. *Lasers Med Sci.* 2012;27(2):383-388. doi:10.1007/s10103-011-0900-7.
  37. Genovese MD, Olivi G. Laser in paediatric dentistry: patient acceptance of hard and soft tissue therapy. *Eur J Paediatr Dent.* 2008;9(1):13-17.
  38. Fornaini C, Rocca JP, Bertrand MF, Merigo E, Nammour S, Vescovi P. Nd:YAG and diode laser in the surgical management of soft tissues related to orthodontic treatment. *Photomed Laser Surg.* 2007;25(5):381-392. doi:10.1089/pho.2006.2068.
  39. Kotlow L. Diagnosis and treatment of ankyloglossia and tied maxillary fraenum in infants using Er:YAG and 1064 diode lasers. *Eur Arch Paediatr Dent.* 2011;12(2):106-112.
  40. Pie-Sanchez J, Espana-Tost AJ, Arnabat-Dominguez J, Gay-Escoda C. Comparative study of upper lip frenectomy with the CO<sub>2</sub> laser versus the Er, Cr:YSGG laser. *Med Oral Patol Oral Cir Bucal.* 2012;17(2):e228-e232.
  41. Amaral MB, de Avila JM, Abreu MH, Mesquita RA. Diode laser surgery versus scalpel surgery in the treatment of fibrous hyperplasia: a randomized clinical trial. *Int J Oral Maxillofac Surg.* 2015. doi:10.1016/j.ijom.2015.05.015.