

Histological Evaluation of Retina after Photo Disruption for Vitreous Humor by Q-Switched Neodymium-Doped Yttrium Aluminium Garnet (Nd:YAG) Laser

Sally Kameel Ghaly¹, Dina Foad Ghoneim¹, Salwa Abdelkawi Ahmed^{*2},
Ahmed Medhat Abdel-Salam¹

¹Ophthalmic Unit, National Institute for Laser Enhanced Science, Cairo University, Egypt.

²Department of Vision Science, Biophysics and Laser Science Unit, Research Institute of Ophthalmology, Giza, Egypt.

Abstract:

Introduction: Rabbits' eyes were exposed to vitreous humor liquefaction with Q - switched (sometimes called "giant pulses") Neodymium-Doped Yttrium Aluminium Garnet (Nd:YAG) laser using two different energy protocols (5 mJ X 100 pulse and 10 mJ X 50 pulse) with and without vitamin C administration. The histological changes in the retina were investigated to evaluate the protective role of vitamin C.

Methods: The rabbits were divided into four main groups (n= 12 each). The first group was divided into three subgroups (n=4) and then treated with 5 mJ X 100 pulse (X means times) delivered to the anterior, middle and posterior vitreous humor respectively. The second group received a daily dose of 25 mg/Kg vitamin C for two weeks then was divided into three subgroups and treated with laser in the same manner as the first group. The third group was divided into three subgroups (n=4) and then treated with 10 mJ X 50 pulse delivered to the anterior, middle and posterior vitreous respectively. The fourth group received a daily dose of 25 mg/Kg vitamin C for two weeks then was divided into three subgroups and treated with laser in the same manner as the third group. After two weeks, rabbits were decapitated and histological examination for the retina was performed.

Results: The results showed that, the anterior vitreous group exposed to 5mJX100 pulse and supplemented with vitamin C, showed no obvious change. Furthermore, all other treated groups showed alteration in retina's tissues histology after laser.

Conclusion: Application of Q-switched Nd: YAG laser in vitreous humor liquefaction induces changes in retina's layers. Although there were some sorts of improvements in retinas supplemented with vitamin C, it cannot protect them against laser oxidative damage.

Keywords: vitreous humors; Nd YAG lasers; retina; vitamin C

Please cite this article as follows:

Ghaly SK, Ghoneim DF, Abdelkawi SA, Abdel- Salam AM. Histological Evaluation of Retina after Photo Disruption for Vitreous Humor by Q-Switched Neodymium-Doped Yttrium Aluminium Garnet (Nd:YAG) Laser. *J Lasers Med Sci* 2013; 4(4):190-8

***Corresponding Author:** Salwa Abdelkawi, Vision Sciences Department, Biophysics and Laser Science Unit, Research Institute of Ophthalmology, P.O. Box12511, 2 El-Ahram St., Giza, Egypt; Fax: +202 35735688; Phone: +20100 1670590; E- mail: saelkawi@yahoo.com

Introduction

Q-switched (sometimes called "giant pulses") Nd:YAG laser has been frequently used in treatment

of several eye diseases such as posterior vitreous detachment ^{1,2}. Posterior vitreous detachment (PVD) leads to vitreous syneresis and asteroid hyalosis ². These symptoms are considered physiological in

nature especially in the cases of myopic. PVD occurs at an earlier age, in which symptoms may be more severe because of retinal image magnification⁴. In addition, Q-switched Nd:YAG vitreolysis has been advocated as an effective treatment for vitreous opacities^{5,6}.

When applying Q-switched Nd:YAG laser treatment for PVD it is necessary to consider the possibility and the extent of complication. The most serious side effect consists of lesion in the tissue posterior to the target location such as, damage to the corneal endothelium, the lens, the artificial lens and the retina causing retinal hemorrhage, rupture of retinal vessels, retinal breaks or retinal detachment^{7,8}.

Furthermore, vitreous floaters are a common complaint in the ophthalmic care setting⁹. Floaters are deposits of different size, shape, consistency, refractive index, and motility within the eye's vitreous humor. Floaters can appear alone or together in the field of vision as spots, threads or fragments, they are not optical illusions but are entopic phenomena¹⁰⁻¹². Most commonly, there is no treatment recommended and vitrectomy may be successful in treating more severe cases but not warranted in minor symptoms cases due to the potential for complications and severe infection¹². In laser vitreolysis, usually Nd: YAG laser is focused onto the floater in a series of short bursts to vaporize and lyse the collagen strands of the floaters. Vitreolysis is much less invasive to the eye than vitrectomy with potentially fewer side effects that include retinal detachment occurring shortly after Nd: YAG vitreolysis^{10,11}. It was reported that, Nd:YAG laser, when focused in mid-vitreous, causes considerable alteration of the molecular structure of the vitreous¹³. Another study stated that, when Nd: YAG laser focused in the lens nucleus or vitreous center plane and its pulse energy was 7.1 – 9.3 mJ with a total of 75-100 pulses that lead to injury to the vitreous body with macular edema, retinal detachment, and cataract development¹⁴.

Photo disruption is the process in which laser pulses of nanosecond duration or shorter are used to induce optical breakdown in tissue. Because of the high-power densities achieved at the focal point, electrons are stripped from their atom causing cavitations (bubbles production), plasma, and shock waves formation¹⁵. The shock waves transient could collapse the vitreous in purely mechanical fashion causing complications such as tissue disruption, retinal damage, and even retinal detachment. The cavitations bubbles will move

into the vitreous cavity with a rate of 100 m/sec and may cause microscopic retinal damage¹⁶. The plasma burst with Q-switched Nd:YAG laser assumes the shape of a long sphere about 30 μ diameter. If the target location for the planned disruption is close to the retina, coagulation or small plasma explosions may occur in the retinal or the choroidal structure¹³. The control of these complications depends on the energy level used and the distance from the target tissue and the neighboring ocular structure.

The aim of the present work is to study the effect of vitreous liquefaction on the retinal structure with two different applications of energy and to evaluate if dietary supplementation of vitamin C can help to protect the retina against the photo oxidative damage of Q-switched Nd:YAG laser vitreolysis.

Methods

Fifty-one Newzealand male rabbits weighing 2-2.5 kg were used in this study. The animals were selected from the animal house of Research Institute of Ophthalmology, Giza, Egypt and were feed on a balanced diet. All procedures were conducted according to the ARVO statement for the use of animals in ophthalmic and vision research. Three rabbits were used as control, and the rest of rabbits were classified into four main groups (n=12 rabbits each).

Group (I): divided into three subgroup (n=4 rabbits each) and received 5 mJ X100 pulse of Q- switched Nd: YAG laser in the anterior, middle and posterior vitreous humor respectively, and the animals were left for two weeks.

Group (II): received a daily dose of 25 mg/ kg body weight of vitamin C by stomach tube started two weeks before laser application. The rabbits were divided into three subgroup (n=4 rabbits each) and treated with laser in the same manner as the previous group, and the animals were left for two weeks.

Group (III): divided into three subgroup (n=4 rabbits each) and received 10 mJ X50 pulse of Q-switched Nd: YAG laser in the anterior, middle, and posterior vitreous humor respectively, and the animals were left for two weeks.

Group (IV): received a daily dose of 25 mg/ kg body weight of vitamin C by stomach tube started two weeks before laser application. The rabbits were divided into three subgroup (n=4 rabbits each) treated with laser in the same manner as the previous group, and the animals were left for two weeks.

Clinical Examination

Before vitreous liquefaction, papillary mydriasis was induced in rabbits' eyes using "Mydriacyl" eye drop 0.5% (Alcon laboratories, Australia, Pty Ltd.) followed by slit lamp biomicroscopic examinations. The results showed no signs of edema or intraocular inflammation in all eyes.

Laser treatment

Animals were generally anesthetized using intramuscular ketamine hydrochloride (ketalar 2.5mg/kg) and 0.4% Benoxinate eye drops was used for local anesthesia. Rabbits underwent vitreous liquefaction using Q- switched Nd: YAG laser. The energies were 5 mJ X100 pulse for groups I and II and 10 mJ X50 pulse for groups III and IV, the spot size was 10 microns, the cone angle was 16 degree, the wavelength was 1064 nm, and the duration of the pulse was 4 n sec.

Histological examination of the retina

The retinal specimens were immediately fixed in

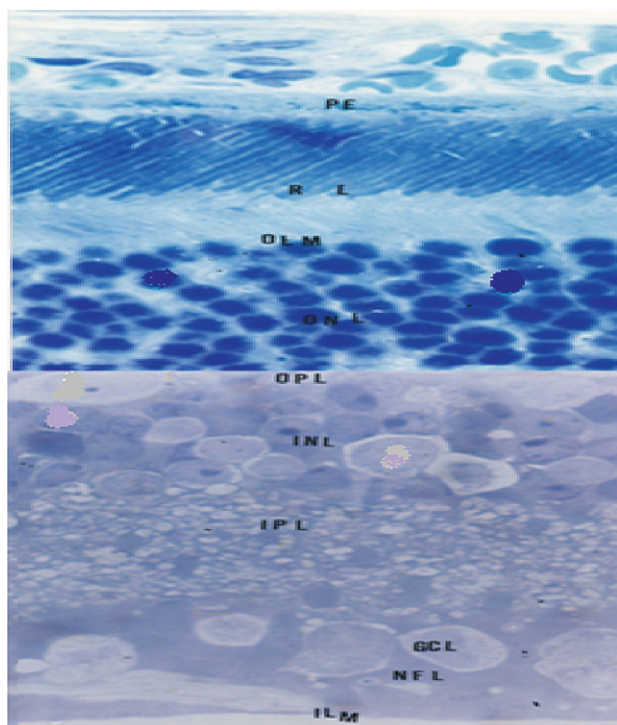


Figure 1. Light micrograph of control albino rabbit's retina showing the outer pigmented epithelium (PE), photoreceptor layer (RL), outer limiting membrane (OLM), outer nuclear layer (ONL), outer plexiform layer (OPL), inner nuclear layer, inner plexiform layer (IPL), ganglion cell layer (GCL), nerve fiber layer (NFL) and inner limiting membrane. (Toluidine blue X 500)

2.5% phosphate buffered glutaraldehyde (pH 7.4) at 4°C for 24 hours and post fixed in 1% osmium tetroxide for one hour, then dehydrated in an ascending grades of ethanol. After immersion in propylene oxide, the specimens were embedded in araldite 512 mixture. Semi-thin sections (1µm) were cut, stained with toluidine blue and examined by light microscope.

Histological examination results

Control retina

The control retina of albino rabbit showed no significant microscopic alteration in all retinas' layers (Figure 1).

Anterior vitreous treated groups with 5mJX100 pulse laser energy

Light micrograph for retina of treated rabbit's anterior vitreous humor with Q- switched Nd: YAG laser (5mJX100 pulse) without vitamin C showed vacuolar changes of the retinal pigment epithelium (RPE), outer nuclear layer (ONL), and inner (IPL) plexiform layer (Figure 2). While the anterior vitreous

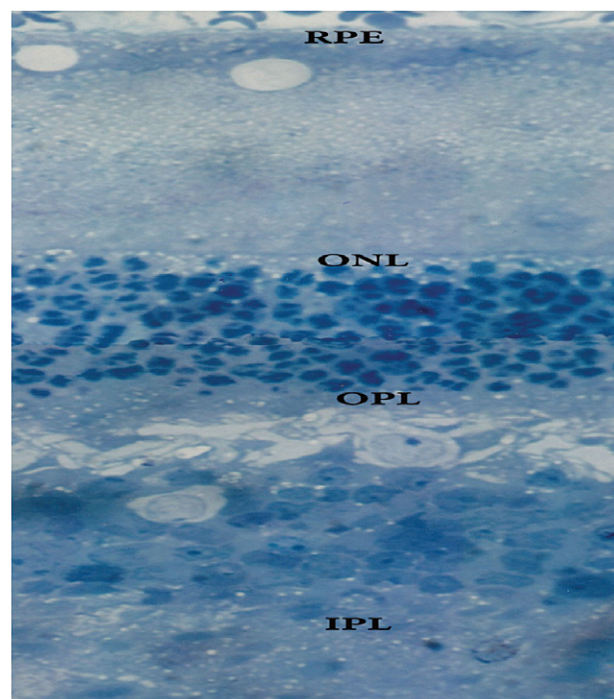


Figure 2. Light micrograph for retina of treated rabbit's anterior vitreous humor with Q- switched Nd: YAG laser (5mJX100 pulse) without vitamin C showing vacuolar changes of the retinal pigment epithelium (RPE), outer nuclear layer (ONL) and inner (IPL) plexiform layer. (Toluidine blue X 500)

treated group supplemented with vitamin C showed no deviation from the control (Figure 3).

Mid- vitreous treated groups with 5mJx100 pulse laser energy

Light microscopic examination for retina of treated rabbit's mid- vitreous humor with Q- switched Nd: YAG laser (5mJX100 pulse) without vitamin C showed fragmented chromatin of nuclei of outer nuclear layer (Figure 4). Moreover, the group supplemented with vitamin C (Figure 5) revealed mild edema between outer segments of photoreceptor and ganglion cell layers.

Posterior vitreous treated groups with 5mJx100 pulse laser energy

Light micrograph for retina of treated rabbit's posterior vitreous humor with Q- switched Nd: YAG laser (5mJX100 pulse) without vitamin C supplementation (Figure 6) showed disorganization of outer segments of photoreceptors. In addition, fragmented chromatin of cell bodies of inner nuclear layer was obvious. Furthermore, after supplementation

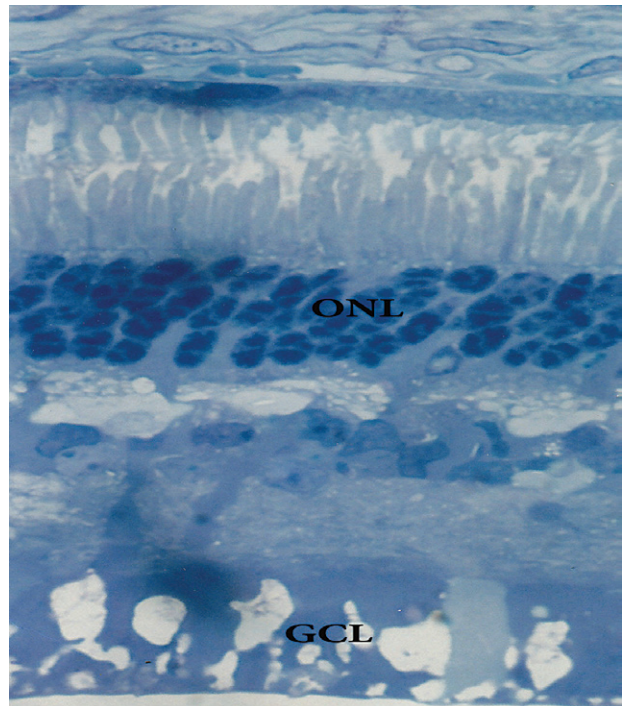


Figure 4. Light micrograph for retina of treated rabbit's mid-vitreous humor with Q- switched Nd: YAG laser (5mJX100 pulse) without vitamin C showing fragmentation in the chromatin of nuclei of outer nuclear layer. (Toluidine blue X 500)




Figure 3. Light micrograph for retina of treated rabbit's anterior vitreous humor with Q- switched Nd: YAG laser (5mJX100 pulse) with vitamin C showing no deviation from the control. (Toluidine blue X 500)




Figure 5. Light micrograph for retina of treated rabbit's mid-vitreous humor with Q- switched Nd: YAG laser (5mJX100 pulse) with vitamin C supplementation showing mild edema between outer segments of photoreceptor and ganglion cell layers. (Toluidine blue X500)

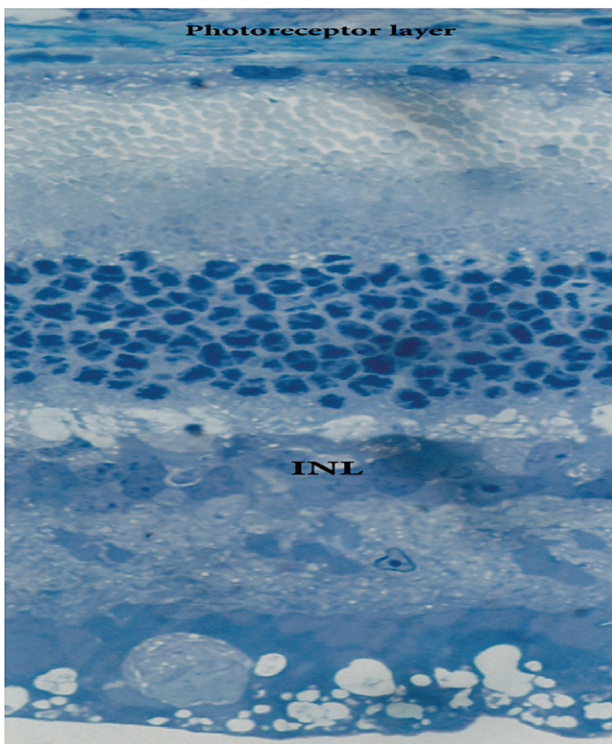


Figure 6. Light micrograph for retina of treated rabbit's posterior vitreous humor with Q- switched Nd: YAG laser (5mJX100 pulse) without vitamin C supplementation showing disorganization of outer segments of photoreceptors and fragmentation of the chromatin of cell bodies of inner nuclear layer. (Toluidine blue X 500)

with vitamin C the retinal layer showed some sort of preservation with some vacuolar changes of the pigment epithelium and ganglion cell layers (Figure 7).

Anterior vitreous treated groups with 10mJX50 pulse laser energy

Light micrograph for retina of treated rabbit's anterior vitreous humor with Q- switched Nd: YAG laser (10mJX50pulse) without vitamin C supplementation showed reduced thickness and ill-defined cellular structure of inner nuclear layer (Figure 8). The light micrograph for retina of treated rabbit's anterior vitreous humor with Q- switched Nd: YAG laser (10mJx50pulse) with vitamin C supplementation indicated the majority of the retinal layers are protected with the exception of the inner segments of photoreceptor layer and outer nuclear layer (Figure 9).

Mid- vitreous treated groups with 10mJX50 pulse laser energy

Light microscopic examination for retina of treated rabbit's mid- vitreous humor with Q-switched Nd:

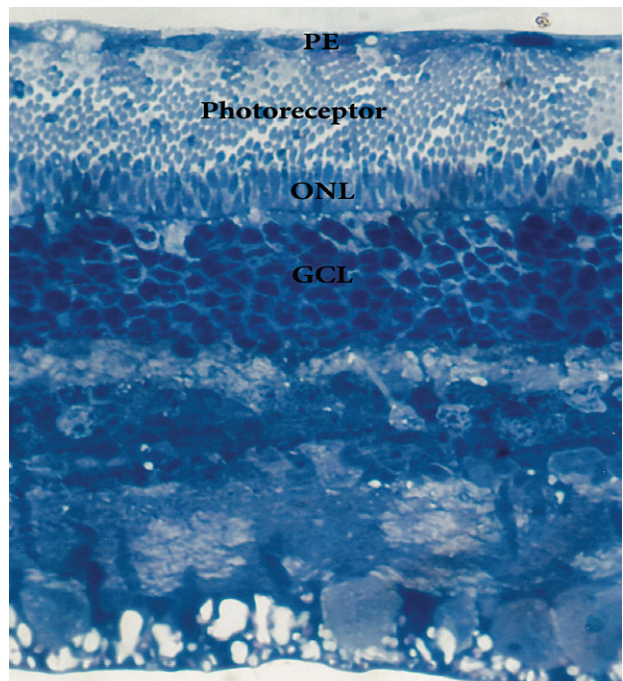


Figure 7. Light micrograph for retina of treated rabbit's posterior vitreous humor with Q- switched Nd: YAG laser (5mJX100 pulse) with vitamin C supplementation showing preservation of the retinal layers with the exception of some vacuolar changes of the pigment epithelium and ganglion cell layers. (Toluidine blue X 500)

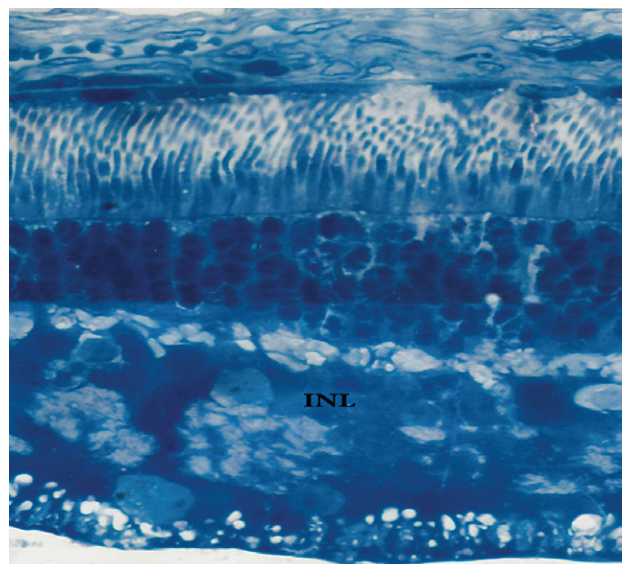


Figure 8. Light micrograph for retina of treated rabbit's anterior vitreous humor with Q- switched Nd: YAG laser (10mJX50pulse) without vitamin C supplementation showing reduced thickness and ill-defined cellular structure of inner nuclear layer.

YAG laser (10mJX50pulse) without vitamin C supplementation revealed lyses of chromatin of some cell bodies of outer nuclear layer in addition to compact internal plexiform layer (Figure 10). The retina of group supplemented with vitamin C showed



Figure 9. Light micrograph for retina of treated rabbit's anterior vitreous humor with Q- switched Nd: YAG laser (10mJX50pulse) with vitamin C supplementation showing the majority of the retinal layers are protected with the exception of the inner segments of photoreceptor layer and outer nuclear layer.

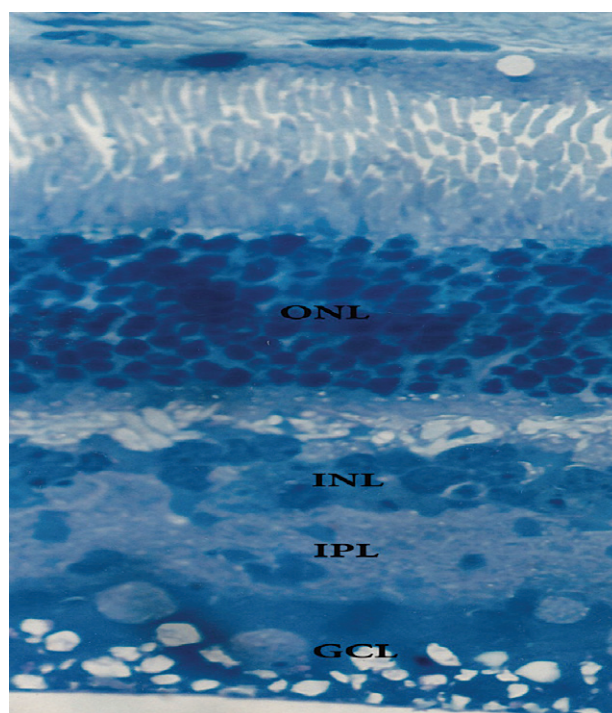


Figure 11. Light micrograph for retina of treated rabbit's mid-vitreous humor with Q- switched Nd: YAG laser (10mJX50pulse) with vitamin C supplementation showing edema in some layers such as outer plexiform layer, ganglion cell layer, and compact internal plexiform layer.

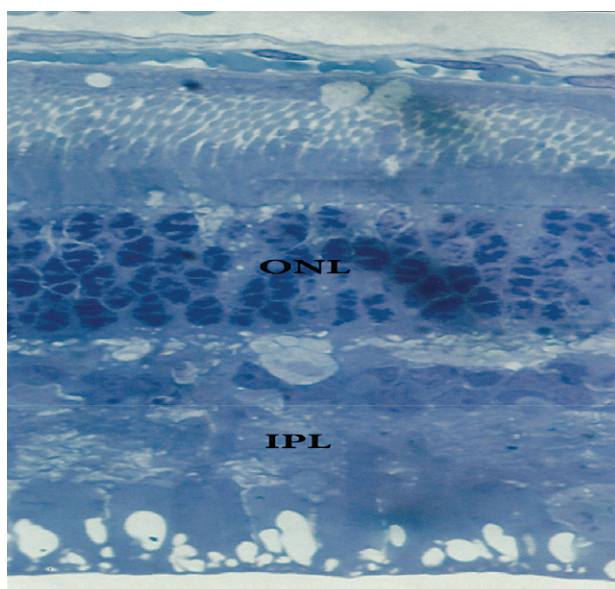


Figure 10. Light micrograph for retina of treated rabbit's mid-vitreous humor with Q- switched Nd: YAG laser (10mJX50pulse) without vitamin C supplementation showing lysis of chromatin of some cell bodies of outer nuclear layer and compact internal plexiform layer. (Toluidine blue X500)

edema in some layers such as outer plexiform layer and ganglion cell layer. Moreover, the internal plexiform layer was compacted (Figure 11).

Posterior vitreous treated groups with 10mJx50 pulse laser energy

Light micrograph for retina of treated rabbit's posterior vitreous humor with Q- switched Nd: YAG laser (10mJX50pulse) without vitamin C supplementation (Figure 12) indicated retinal detachment and disorganized outer segments of photoreceptors. Intercellular edema between the cell bodies of inner nuclear layer, ganglion cell layer and nerve fibre layer was evident. Supplementation of vitamin C showed slight recovery with some vacuolation of photoreceptors and lyses of chromatin of some cell bodies (Figure 13).

Discussion

The vitreous humor is a very important intraocular fluid because of its optical function and its significant roles in the pathogenesis and treatment of the eye. Vitreous humor, present in the posterior chamber often becomes dysfunctional, which takes place during aging leading to separation of the vitreous gel and its detachment from the retina, physical collapse, opacification and vision loss¹⁷. The destruction

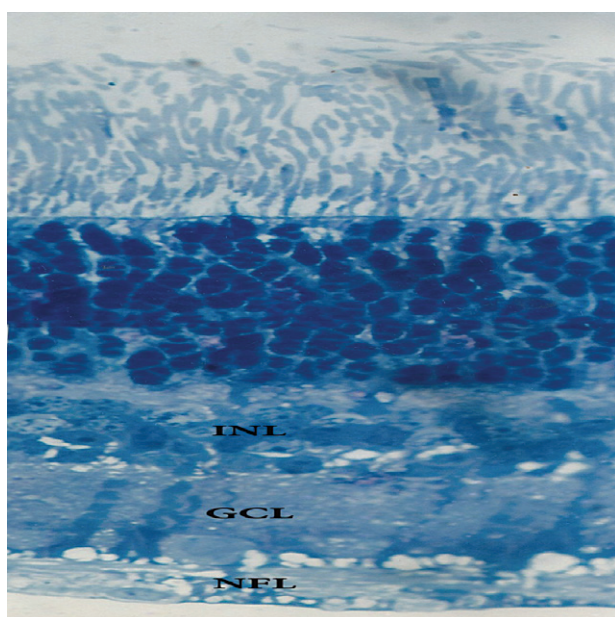


Figure 12. Light micrograph for retina of treated rabbit's posterior vitreous humor with Q- switched Nd: YAG laser (10mJx50pulse) without vitamin C supplementation showing retinal detachment and disorganized outer segments of photoreceptors and intercellular edema between the cell bodies of inner nuclear layer, ganglion cell layer and nerve fibre layer. (Toluidine blue X500)

of vitreous humor can also occur by mechanical, chemical, and thermal trauma. This may result in collapse of vitreous, which has a great tendency to detach from the retina¹⁸.

This study has been undertaken to consider the possible hazardous side effect of Q-switched Nd: YAG laser photo disruption on the retina after anterior, middle, and posterior vitreous liquefaction and to identify the protective role of vitamin C against laser oxidative damage.

The change in histological structure of retina's tissues after treatment with Q-switched Nd: YAG laser (5mJX100 pulse and 10 mJX50 pulse) without and with vitamin C supplementation were evaluated. The results indicated that, the anterior vitreous group exposed to 5mJX100 pulse and supplemented with vitamin C, showed no obvious change. Furthermore, all other treated groups showed alteration in retina's tissues histology after laser.

Obviously, the current data show direct correlation between the target site and the retina's tissues response. It is noticed that, the closer the targeted area is to the retina, the greater the effect.

The groups treated with 5mJX100 pulse without vitamin C supplementation showed vacuolar changes of the retinal pigment epithelium, outer nuclear

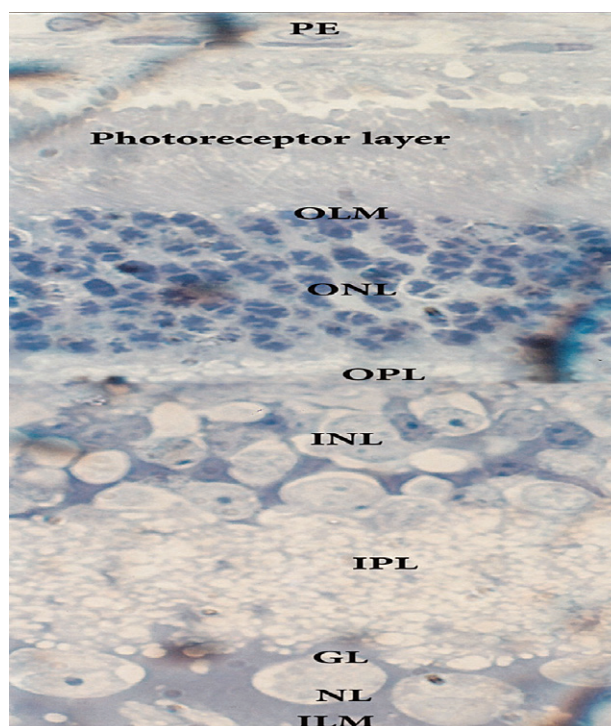


Figure 13. Light micrograph for retina of treated rabbit's posterior vitreous humor with Q- switched Nd: YAG laser (10mJx50pulse) with vitamin C supplementation showing slight vacuolation of photoreceptors and lyses of chromatin of some cell bodies. (Toluidine blue X500)

layer, and inner plexiform layer (anterior vitreous). In addition, fragmented chromatin of nuclei of outer nuclear layer was shown in mid- vitreous treated group. The posterior vitreous treated group revealed disorganization of outer segments of photoreceptors accompanied with fragmented chromatin of cell bodies of inner nuclear layer. Supplementation with vitamin C preserves the retina in all groups to some extent. Mild edema between outer segments of photoreceptor and ganglion cell layers was shown in mid- vitreous. Some sort of preservation was shown in posterior vitreous with vacuolar changes of the pigment epithelium and ganglion cell layers. The changes were in agreement with previous studies by Lerman et al. (1984) and Michael et al. (1996), they reported that the Nd: YAG laser whether focused on the posterior lens capsule or mid- vitreous, causes considerable alteration of the molecular structure of the vitreous and lens, associated with retinal hole formation and detachment^{19, 20}.

By comparing the changes in retinas of groups exposed to 10mJX50 pulse and the previous groups exposed to 5mJX100 pulse, the effect of laser was more pronounced. The resulted effects ranged from changes in cellular structure of inner nuclear layer

(anterior vitreous) to retinal detachment, disorganized outer segments of photoreceptors and edema in different layers of the retina (as shown in the posterior vitreous treated group). For all groups supplemented with vitamin C there were slight recovery in different layers of the retina parts accompanied with alteration in photoreceptor layer, ganglion cell layer and lyses of chromatins of some cell bodies.

It is noticed that, the change in the groups supplemented with vitamin C is lesser than the non-supplemented one. This improvement may be due to the ability of vitamin C to scavenge free radicals and the high level of vitamin C in the eyes of diurnal animals suggested that the vitamin might protect against oxidative or photo-oxidative damage^{21, 22}.

The obtained data hypothesized that, when the vitreous humor were treated with the Nd: YAG laser, it induces optical breakdown. Because of the short-pulsed nature (4 n sec) and the highly localized site of this laser, the temperature reaches several thousand degrees Kelvin, but the extremely short duration of the energy increase makes widespread thermal effects unlikely and produces a shock wave. The shock wave transient could conceivably collapse the vitreous in a purely mechanical fashion. This Change in the gel state structure of the vitreous humor, because of laser photo disruption, may lead to decrease of antioxidant, which normally protect vitreous humor from free radical. This would lead to loss of vitreous function to scavenge free radicals²³. These free radicals play an important role in liquefaction of vitreous. Vitreous humor liquefaction exerts stress on retina especially at the photoreceptor layer and is associated with vitreoretinal pathology^{24, 25}. The obtained results are in agreement with previous results that studied an experimental model of vitreoretinopathy obtained by direct production of free radicals in the vitreous body²⁶.

The vitreous is attached to the retina at the inner limiting membrane where the terminations of Müller cells are contributing component²⁷⁻²⁹. The obtained data is indicating that, Nd: YAG laser exerts an effect on the retina that appears clearly in photoreceptors layer, ganglion cells layer and different retinal layers.

In addition, it can be said that, the vitreous has an integral role in a variety of retinal diseases and it may have a direct impact on retinal oxygenation³⁰. This is consistent with the results of previous intervention trials, which found that, when the vitreous was usually in the gel state, oxygen diffused into the vitreous humor from the vessels in the ciliary epithelium and

was metabolized by retinal tissue³¹⁻³³. Furthermore, when the vitreous liquefies, oxygen accumulates in the vitreous. The more that oxygen is mixed with the vitreous fluid, slowing the consumption of oxygen, the more oxygen is permitted to reach the retina causing oxidative stress.

The present work finds some sort of improvement in retina's layers with supplementation of vitamin C. This improvement is reversely proportional with target site from the retina. It was suggested that, the improvement may be due to the role of vitamin C in reducing the activity of some of the free radicals in vitreous and retina and that may help the vitreous to improve its characteristics³⁴. Additionally, the improvement may be due to the newly regenerated photoreceptors, which are continuously replenishing themselves³⁵. The obtained results agree with previous studies, which showed that the antioxidant treatment could improve the progression of some retinal disorder^{25, 26}.

Because the propagation of the laser damage is posterior, special care must be considered to avoid damaging the neighboring tissues and energy values close to threshold must be used. A safe distance between the target tissue and the neighboring tissues has been estimated to be 2 to 5 mm¹⁰.

Conclusion

Laser tissue interaction after photo disruption with Q-switched Nd:YAG laser induce optical breakdown, could conceivably collapse the vitreous in a purely mechanical fashion that could contribute to retina dysfunction. The effect of laser on vitreous is site and energy dependent. When it is applied with high energy per pulse near the retina, the effect will be more pronounced. Based on interactions between laser and vitreous humor, it should be possible to formulate strategies to prevent or downgrade Q- switched Nd:YAG laser complications.

References

1. Murakami K, Jalkh AE, Avila MP, Trempe CL, Schepens CL. Vitreous floaters. *Ophthalmology* 1983; 90: 1271-6.
2. Morse PH. Symptomatic floaters as a clue to vitreoretinal disease. *Ann Ophthalmol* 1975; 7: 865-8.
3. Noda S, Hayasaka S, Setogawa T. Patients with asteroid hyalosis and visible floaters. *Jpn J Ophthalmol* 1993; 37: 452-5.
4. Morita H, Funata M, Tokoro T. A clinical study of the

- development of posterior vitreous detachment in high myopia. *Retina* 1995; 15: 117-24.
5. Tsai WF, Chen YC, Su CY. Treatment of vitreous floaters with neodymium YAG laser. *Br J Ophthalmol* 1993; 77: 485-8.
 6. Toczolowski J, Katski W. [Use of Nd:YAG laser in treatment of vitreous floaters]. *Klinika Oczna* 1998; 100:155-7. Polish.
 7. Jagger JD, Hamilton AM, Polkinghorne P. Q- switched neodymium YAG laser vitreolysis in the therapy of posterior segment disease. *Graefes Arch Clin Exp Ophthalmol* 1990; 228: 222-5.
 8. Vogel A, Hentschel W, Holzfuß J, Lauterborn W. Cavitation bubble dynamics and acoustic transient generation in ocular surgery with pulsed Neodymium: YAG lasers. *Ophthalmology* 1986; 93: 1259- 69.
 9. Sendrowski DP, Bronstein MA. Current treatment for vitreous floaters. *Optometry* 2010; 81 (3): 157-61.
 10. Benhamou N, Glacet-Bernard A, Le Mer Y, Quentel G, Perrenoud F, Coscas G, et al. [Retinal detachment following YAG Laser section of vitreous strands. Apropos of three cases]. *J Fr Ophthalmol* 1998; 21 (7): 495-500. French.
 11. Delaney YM, Oyinloye A, Benjamin L. ND: YAG vitreolysis and pars plana vitrectomy: surgical treatment for vitreous floaters. *Eye (Lond)* 2002; 16 (1): 21-6.
 12. Roth M, Trittibach P, koerner F, Sarra G. [Pars plana vitrectomy for idiopathic vitreous floaters]. *Klin Monbl Augenheilkd* 2005; 222 (9): 728-32. German.
 13. Krauss JM, Puliafito CA, Miglior S, Steinert RF, Cheng HM. Vitreous changes after Neodymium – YAG laser photo disruption. *Arch Ophthalmol* 1986; 104: 592- 7.
 14. Stepanov AV, Babizhaev MA, Ivanov AN, Aitmaqambetov MT, Deev AI. [Photodamage to the eye in exposure to the radiation from ND: YAG Q-switching laser: The physicochemical structural changes to the crystalline lens and the vitreous]. *Vestn Oftalmol* 1990; 106 (1): 31-5. Russian.
 15. Steinert R F, Puliafito C A: *Laser in ophthalmology: Principles and clinical applications of photo disruption.* pp 22- 35. Philadelphia WB Saunders, Co; 1985.
 16. Puliafito CA, Wasson PJ, Steinert RF, Gragoudas ES. Neodymium – YAG laser surgery on experimental vitreous membranes. *Arch Ophthalmol* 1984;102: 843-7.
 17. Chirila TV, Hong YE, Dalton PD, Constable IJ, Refojo M. The use of hydrophilic polymer as artificial vitreous. *Prog Polym Sci* 1998; 23: 475-508.
 18. Suri S, Banerjee R. Biophysical evaluation of vitreous humor, its constituents, and substitutes. *Trends Biomater Artif Organs* 2006; 20:72-7.
 19. Lerman S, Thrasher B, Moran M. Vitreous changes after Neodymium –YAG laser irradiation of the posterior lens capsule or mid- vitreous. *Am J Ophthalmol* 1984; 97: 470-5.
 20. Michael R, Söderberg PG, Chen E. Long-term development of lens opacities. *Ophthalmic Res* 1996; 25: 209-18.
 21. Garland DL. Ascorbic acid and the eye. *Am J Clin Nutr* 1991; 54(6) (suppl):1198S-1202S.
 22. Rose RC, Richer SP, Bode AM. Ocular oxidants and antioxidant protection. *Proc Soc Exp Biol Med* 1998; 217(4):397-407.
 23. Shui YB, Holekamp NM, Kramer BC, Crowley JR, Wilkins MA, Chu F, et al. The Gel state of the vitreous and ascorbate- dependent oxygen consumption: relationship to the etiology of nuclear cataracts. *Arch Ophthalmol* 2009; 127: 475-82.
 24. Ueno N. [Changes in vitreous structure caused by oxygen free radicals]. *Nihon Ganka Gakkai Zasshi* 1995; 99(12): 1342-60. Japanese.
 25. Fernandez-Robredo P, Moya D, Rodriguez JA, Garcia-Layana A. Vitamin C and E reduce retinal oxidative stress and nitric oxide metabolites and prevent ultrastructural alterations in porcine hypercholesterolemia. *Invest Ophthalmol Vis Sci* 2005; 46(4): 1140-6.
 26. Baudouin C, Pisella PJ, Ettaiche M, Goldschild M, Becquet F, Gstaad P, et al. Effects of EGb761 and superoxide dismutase in an experimental model of retinopathy generated by intravitreal production of superoxide anion radical. *Graefes Arch Clin Exp Ophthalmol* 1999; 237(1): 58-66.
 27. Vogel A, Capon MR, Asiyovogel MN, Birngruber R. Intraocular photo disruption with picosecond and nanosecond laser pulses: tissue effects in cornea, Lens and Retina. *Invest Ophthalmol Vis Sci* 1994; 35 (7): 3032-44.
 28. Matsumoto B, Blanks JC, Ryan SJ. Topographic variations in the rabbit retina and primate internal Limiting membrane. *Invest Ophthalmol Vis Sci* 1984; 25: 71-82.
 29. Hikichi T, Takahashi M, Trempe CL, Schepens CL. Relationship between premacular cortical vitreous defects and idiopathic premacular fibrosis. *Retina* 1995; 15(5): 413-6.
 30. Snead MP, Snead DR, James S, Richard AJ. Clinicopathological changes at the vitreoretinal Junction: posterior vitreous detachment. *Eye (Lond)* 2008; 22: 1257-62.
 31. Stefánsson E, Novack RL, Hatchell DL. Vitrectomy prevents retinal hypoxia in branch retinal vein occlusion. *Invest Ophthalmol Vis Sci* 1990; 31(2): 284-9.
 32. Buerk DG, Shonat RD, Riva CE, Cranstoun SD. O₂ gradients, and countercurrent exchange in the cat vitreous humor near retinal arterioles and venules. *Microvasc Res* 1993; 45(2):134-48.
 33. Harocopos GJ, Shui YB, Mc Kinnon M, Holekamp NM, Gordon MO, Beebe DC. Importance of vitreous liquefaction in age-related cataract. *Invest Ophthalmol Vis Sci* 2004; 45(1):77-85.
 34. Tam WK, Chan H, Brown B, Yap M. Effects of different degrees of cataract on multifocal electroretinogram. *Eye (Lond)* 2004; 18: 691-6.
 35. Kolb H, Nelson R, Fernandez E, Jones B. *Web vision. The organization of the retina and visual system.* Copyright© 2011 web vision powered by word press. University of Utah Disclaimer.