

Holmium-YAG Laser Ureteroscopic Lithotripsy in a Patient with Ectopic Malrotated Kidney

Mohammad Reza Razzaghi¹, Mohammad Mohsen Mazloomfard², Reza Mohammadi²
Hooman Bahrami-Motlagh³

¹Laser Application of Medical Sciences Research Center, Shohada Tajrish Hospital, Shahid Beheshti University of Medical Sciences, Tehran, Iran

²Urology Department, Shohada Tajrish Hospital, Shahid Beheshti University of Medical Sciences, Tehran, Iran

³Radiology Department, Shohada Tajrish Hospital, Shahid Beheshti University of Medical Sciences, Tehran, Iran

Abstract:

The incidence of stone disease among patients with congenital renal anomalies including malrotated kidney is more than in normal population due to poor urine drainage and stasis (1). Various minimally invasive options have been used for the management. Ureteroscopy and Holmium:YAG laser lithotripsy have been reported with favorable outcomes (2). We report a 30-year-old male who presented to our hospital having a right side malrotated kidney with a large stone in it. He underwent two session of ureteroscopy and Holmium:YAG laser lithotripsy.

Keywords: Congenital renal anomalies; Calculus Treatment; Lithotripsy; Laser

Please cite this article as follows:

Razzaghi MR, Mazloomfard MM, Mohammadi R, Bahrami-Motlagh H. Holmium-YAG Laser Ureteroscopic Lithotripsy in a Patient with Ectopic Malrotated Kidney: *J Lasers Med Sci* 2012; 3(2):75-8

***Corresponding Author:** Mohammad Mohsen Mazloomfard, MD; Urology Department, Shohada Tajrish Hospital, Shahid Beheshti University of Medical Sciences, Tehran, Iran. Tel:+98-2122718001-9; Fax:+98-218852 6901; E-mail: mazloomfard@yahoo.com

Introduction

Congenital anomalies of the upper urinary tract comprise a diversity of abnormalities. Kidney malrotation which is found in 1 of 939 autopsies is most often established in conjunction with another renal abnormality, such as ectopia or a horseshoe kidney (3). The ectopic kidney can be located in the pelvis, the abdomen, or, rarely, in the thorax (0.3%) and can be unilateral or bilateral. This anomaly has male predominance with the right side involvement more frequent (4,5). The incidence of stone disease among patients with congenital renal anomalies including malrotated kidney is more than in normal population due to poor urine drainage and stasis (6). Surgical management of stones in anomalous kidney presents a problem for urologic surgeons. Various minimally invasive

management options have been previously reported including shock wave lithotripsy (SWL), percutaneous nephrolithotomy (PNL), as well as ureteroscopy (7). The advancement of ureteroscopy and related working instruments to manipulate or fragment ureteral calculi has significantly increased treatment options for urologists. For stone fragmentation, a variety of lithotripters can be used, including ultrasonic, electrohydraulic, pneumatic and laser lithotripters. Holmium:YAG lithotripsy have been reported with favorable outcomes (2). As new endoscopic technology and adjunctive device developments continue to enter the urologist's armamentarium the role of ureteroscopy continues to expand. Once unapproachable stones may now be addressed via flexible ureteroscopes, improved baskets, and holmium lasers (7).

Case Report

A 30-year-old male presented to the emergency department of our hospital with a right upper quadrant (RUQ) pain due to falling down. At the time of admission, the patient was alert and cooperative. Physical examination revealed stable vital signs, RUQ tenderness. Laboratory tests revealed normal serum creatinine levels, and microscopic hematuria on urinalysis examination. On blood cell count no anemia was detected.

Chest radiograph film was unremarkable. Abdominopelvic computed tomography (CT) scan revealed the presence of a mild liver subcapsular hematoma with a little amount of fluid in its lower pole. Also, both kidneys had horizontal axis, the right one possessed a huge renal pelvis located laterally and consisting of a large opacity in favor of stone (Figure 1).

The patient was admitted in intensive care unit for conservative support of liver trauma.

Four weeks after trauma, the patient underwent ureteroscopy under spinal anesthesia. After passage of the ureteroscope through the right uretero-pelvic junction, a dilated huge pelvis was observed with a 2.5-3 cm stone in it. Laser lithotripsy was done using the ablative 50-watt Holmium: YAG laser 2140 nm (manufactured by the Atomic Energy Organization of Iran [AEOI]). Due to the large size

of the stone the procedure could not be performed completely in the first session of therapy; so, after insertion of a ureteral stent, he was discharged from the hospital on the same day of operation without any complications. The second session of laser lithotripsy was done after 2 weeks and the stone was totally fragmented (Figure 2). The postoperative period was uneventful.

Discussion

Kidney malrotation is one of the congenital anomalies of the upper urinary tract, which is found in 1 of 939 autopsies. In most malrotation cases, the malrotation occurs ventrally, ventromedially, dorsally, or laterally. Generally, an ectopic kidney is smaller, is of irregular shape and variable rotation, and is vascularized by multiple arteries with various levels of origin (3-5). The incidence of stone disease among patients with congenital renal anomalies varies widely and depends on the type of renal anomaly. Twenty percent of patients with horseshoe kidneys and polycystic kidney diseases develop renal stones (6). Poor urine drainage and stasis are the major causes of stone formation in congenital renal anomalies; rather than metabolic and genetic causes which may assist stone formation in polycystic kidney disease (1,8). Surgical management of stones in

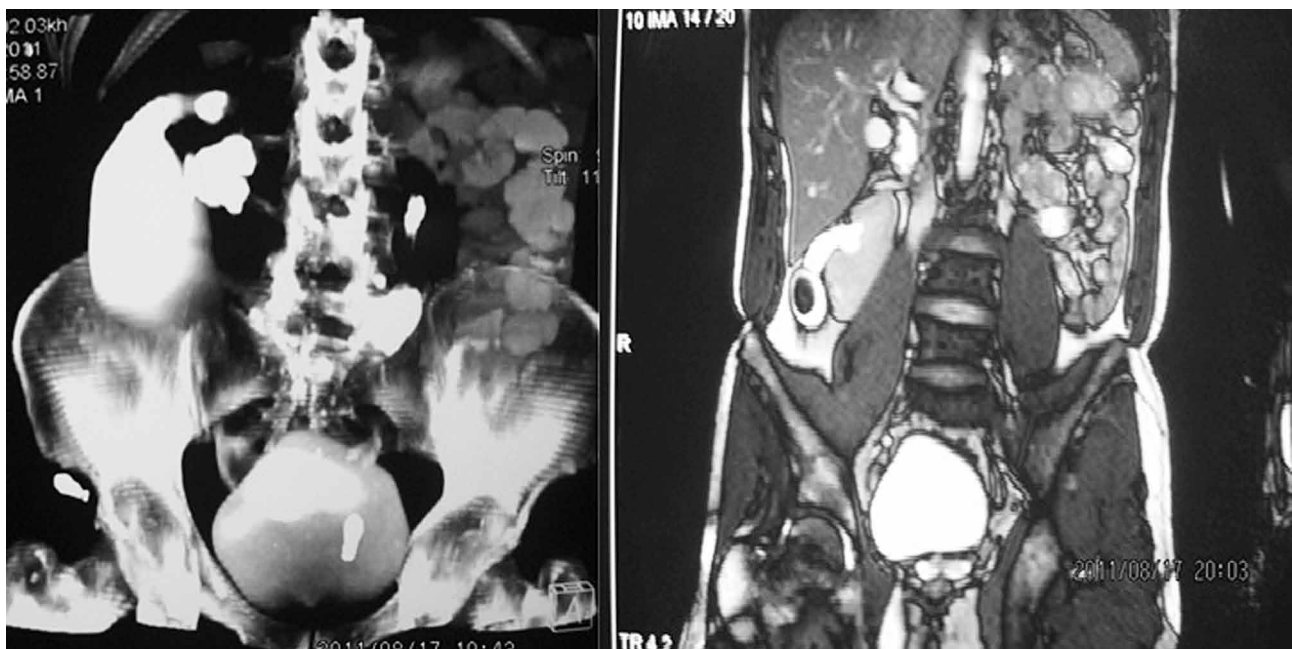


Figure 1. Coronal reconstruction of contrast-enhanced abdominal CT scan shows malrotated kidneys of both sides.

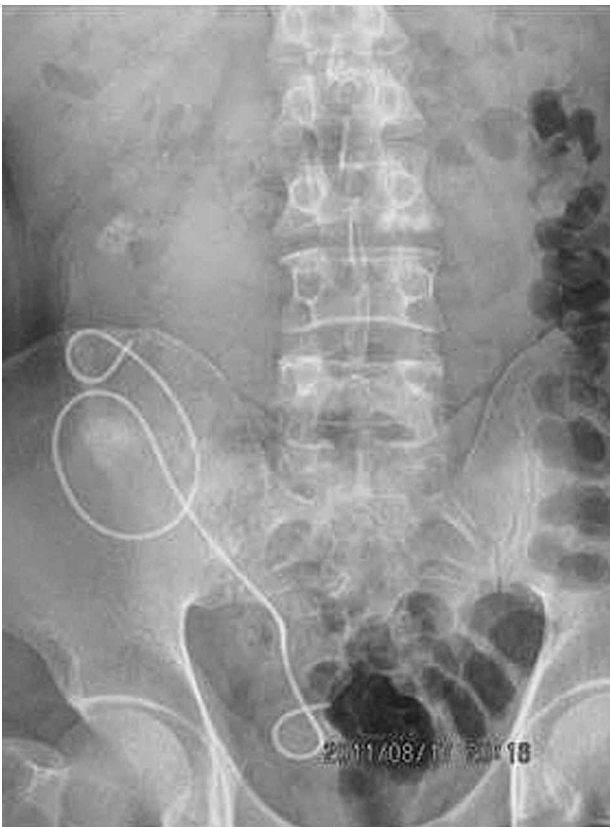

Figure 2. Plain abdominal X-ray (Kidney-Ureter-Bladder [KUB]) revealed no stone fragment and DJ in ectopic kidney.

anomalous kidneys presents a problem for urologic surgeons. Various minimally invasive management options have been previously reported, including shock wave lithotripsy (SWL), percutaneous nephrolithotomy (PNL), as well as ureteroscopy (7).

Mosavi-Bahar and colleagues performed PNL in patients with kidney malformations including 5 cases of rotation anomalies. The authors concluded that patients with malformed kidneys and complex calculi can be managed safely and effectively with PCNL when they are properly selected and appropriately assessed before operation (9).

Al-Tawheed and coworkers studied the effectiveness of SWL in the treatment of stones in kidneys with congenital anomalies to determine factors that may affect the results. They mentioned that in majority of patient calculi may be treated successfully by ESWL as a first-line therapy. With position modifications, localization of stones may be facilitated and disintegrated (6).

However, recent improvements in endoscopic technology and intracorporeal lithotripsy make ureteroscopy possible for most cases of stones in

ectopic, pelvic, or transplant kidneys. Additionally, many of the limitations of shock wave lithotripsy and/or percutaneous nephrolithotomy can be overcome with an ureteroscopic approach (7). As new endoscopic technology and adjunctive device developments continue to enter the urologist's armamentarium the role of ureteroscopy continues to expand. Once unapproachable stones may now be addressed via flexible ureteroscopes, improved baskets, and holmium lasers (10). Literatures show excellent results for ureteroscopic lithotripsy using the holmium laser for proximal ureteral calculi, with a mean stone-free rate of 95% associated with a low perforation and stricture rate of about 1% (11). For this purpose, a better outcome could be achieved by flexible ureteroscopic lithotripsy as the primary approach (12). Although, using the holmium laser or flexible ureteroscopic lithotripsy is expensive and not available in many centers (2).

Ferrandino et al. suggest that success rates of ureteroscopic management of stones in anomalous kidneys are similar to those reported for SWL and the morbidity is less than PNL. They believed that ureteroscopy could play a larger role in the management of these challenging patients, with subsequently reduced patient morbidity, taking into account the increasing dissemination of ureteroscopic skills, improved technology and enhanced adjunctive devices (i.e.; sheaths and baskets) (7).

The mechanism of holmium: YAG lithotripsy is photothermal (13). Holmium: YAG energy heats the stones to a critical thermal threshold at which the stone composition is altered, yielding a stone crater and small fragments. Therefore, undesired upward migration of stone or fragments can be minimized (14). Our patient was treated with this technique with total clearance of stone and no stone migration.

Conclusion

Surgical management of stones in anomalous kidney presents a problem for urologic surgeons. In our experience, Holmium: YAG laser lithotripsy was effective and safe in this special patient.

References

1. Smith JE, Van Arsdalen KN, Hanno PM, Pollack HM. Extracorporeal shock wave lithotripsy treatment of

- calculi in horseshoe kidneys. *J Urol* 1989; 142(3):683–6.
- Razzaghi MR, Razi A, Mazloomfard MM, Mokhtarpour H, Javanmard B, Mohammadi R. Trans-Ureteral Ureterolithotripsy of Ureteral Calculi: Which is the Best; Pneumatic or Holmium Laser Technique? *J Lasers Med Sci* 2011;2(2): 59-62.
 - Lim TJ, Choi SK, You HW, Kim MJ, Ahn JS, Kim TG, et al. Renal cell carcinoma in a right malrotated kidney. *Korean J Urol* 2011;52(11):792-4.
 - Dretler SP, Olsson C, Pfister RC. The anatomic, radiologic and clinical characteristics of the pelvic kidney: an analysis of 86 cases. *J Urol* 1971;105(5):623–7.
 - Zăhoi DE, Miclăuș G, Alexa A, Sztika D, Pusztai AM, Farca Ureche M. Ectopic kidney with malrotation and bilateral multiple arteries diagnosed using CT angiography. *Rom J Morphol Embryol* 2010;51(3):589–92.
 - Al-Tawheed AR, Al-Awadi KA, Kehinde EO, Abdul-Halim H, Hanafi AM, Ali Y. Treatment of calculi in kidneys with congenital anomalies: an assessment of the efficacy of lithotripsy. *Urol Res* 2006;34(5):291-8.
 - Ferrandino MN, Preminger GM. Ureteroscopic management of stones in anomalous kidneys. *Arch Ital Urol Androl* 2008; 80(1):18-20.
 - Hoenig DM, Shalhav AI, Elbahnasy AM, McDougall EM, Clayman RV. Laparoscopic pyelolithotomy in a pelvic kidney: a case report and review of the literature. *JLS* 1997; 1(2):163–5.
 - Mosavi-Bahar SH, Amirzargar MA, Rahnavardi M, Moghaddam SM, Babolhavaeji H, Amirhasani S. Percutaneous nephrolithotomy in patients with kidney malformations. *J Endourol* 2007;21(5):520-4.
 - Singal RK, Denstedt JD. Contemporary management of ureteral stones. *Urol Clin North Am* 1997; 24(1): 59–70.
 - Mugiya S, Nagata M, Un-No T, Takayama T, Suzuki K, Fujita K. Endoscopic management of impacted ureteral stones using a small caliber ureteroscope and a laser lithotripter. *J Urol* 2000;164(2):329-31.
 - Harmon WJ, Sershon PD, Blute ML, Patterson DE, Segura JW. Ureteroscopy: current practice and long-term complications. *J Urol* 1997;157(1):28-32.
 - Vassar GJ, Chan KF, Teichman JM, Glickman RD, Weintraub ST, Pfefer TJ, et al. Holmium:YAG lithotripsy: photothermal mechanism. *J. Endourol* 1999; 13(3): 181–90.
 - Teichman JM, Vassar GJ, Bishoff JT, Bellman GC. Holmium:YAG lithotripsy yields smaller fragments than lithoclast, pulsed dye laser or electrohydraulic lithotripsy. *J Urol* 1998;159(1): 17–23.