

Case Reports: Abortion Induced by Peganum Harmala Ingestion in a Pregnant Woman: A Case Report and Literature Review



Maryam Vahabzadeh¹, Ali Banagozar Mohammadi², Mohammad Delirrad^{3*}

1. Medical Toxicology Research Center, Mashhad University of Medical Sciences, Mashhad, Iran.

2. Department of Internal Medicine, Faculty of Medicine, Tabriz University of Medical Sciences, Tabriz, Iran.

3. Department of Forensic Medicine and Toxicology, School of Medicine, Urmia University of Medical Sciences, Urmia, Iran.



Citation: Vahabzadeh M, Mohammadi AB, Delirrad M. Abortion Induced by Peganum Harmala Ingestion in a Pregnant Woman; A Case Report and Literature Review. International Journal of Medical Toxicology and Forensic Medicine. 2019; 9(3):165-170. <https://doi.org/10.32598/ijmtfm.v9i3.25910>

<https://doi.org/10.32598/ijmtfm.v9i3.25910>



Article info:

Received: 16 Nov 2018

First Revision: 15 Dec 2018

Accepted: 23 Apr 2019

Published: 01 Jul 2019

Keywords:

Peganum harmala, Poisoning, Induced abortion, Pregnancy, Pregnant woman

ABSTRACT

Background: Peganum harmala is a medicinal plant used in Iran and other countries. Many therapeutic effects have been described for this plant; it is insect repellent, disinfectant, antimicrobial, sedative, analgesic, anti-inflammatory, emetic, and abortifacient. Roots and seeds are medicinally-active parts of the plant containing some β -carboline and quinazoline alkaloids, which are responsible for its pharmacological and toxicological effects. Poisoning with high doses of Peganum harmala can be life-threatening.

Case Report: We reported a 31-year old woman with an unwanted pregnancy, who ingested 1 glass of Peganum harmala seeds to induce abortion. On admission, she had severe nausea and vomiting, mild abdominal pain, and stable vital signs. Physical examination was unremarkable, and the leukocytosis was the only abnormal laboratory finding. The patient underwent nasogastric tube insertion, gastric lavage, as well as the administration of activated charcoal. Although she left the hospital on self-consent, further follow-up revealed that she had a spontaneous abortion without any complications.

Conclusion: Although most cases of Peganum harmala intoxication can be managed successfully, this poisoning led to abortion in our case. Physicians working in Iran and other regions, where Peganum harmala is used as traditional medicine, must be aware of its toxicity for the early diagnosis and management.

1. Introduction

Peganum harmala (*P. harmala*) is a permanent herbaceous plant that grows in semi-arid conditions, steppe areas, and sandy soils [1, 2]. The primary origin of the plant

is central Asia, but nowadays, it is native to the Mediterranean region, including the Middle East, North Africa, and southern Europe. It also grows in other subtropical areas such as Australia and southwest of the United States [3-5]. The plant is a multi-branched shrubby raising to 60cm with short creeping roots, deeply cleft linear

* Corresponding Author:

Mohammad Delirrad, PhD.

Address: Department of Clinical Toxicology, Faculty of Medicine, Urmia University of Medical Sciences, Urmia, Iran.

Tel: +98 (914) 3887678

E-mail: Delirrad@umsu.ac.ir

leaves, white 5-petaled flowers, and rounded 3-celled seed capsules carrying more than 50 seeds [2]. The flowering period is March to April and seeds are gathered in the summer [1, 6]. The medicinally-active parts of the plant are seeds and roots [1, 3, 4, 7, 8].

P. harmala, also known as “Espand” or “Esfand” in Persian [3, 4], has been used to ward off the evil eye as an old belief in Iran [9]. The seeds of the plant are burnt to produce a scented smoke that is used as an air purifier and mostly as a charm against “the evil eye”. This Persian practice seems to date back to the pre-Islamic period [4].

Similarly, the dried capsules of the plant are hung in some houses to protect against “the evil eye” in some regions of Iran and Turkey [2]. *P. harmala* is recognized as “Üzerlik” or “Yüzerlik” in Turkey, “Harmel” or “Harmal” in North Africa and Arab countries, and “African Rue”, “Syrian rue”, “Turkish Rue”, and “Mexican Rue” in the United States [1-7]. For centuries, it has been used to produce a red dye for Persian carpets, and in the 1920s, it was imported into the United States for this purpose [5].

Traditional Iranian Medicine (TIM) have described many medicinal effects for the seeds of *P. harmala*, also known as “Espand-daneh”. The seeds are insect repellent, disinfectant (antibacterial and antifungal), sedative, analgesic (for the management of sciatic pain, joints pain, coxalgia, chronic headache, and toothache), anti-inflammatory, antispasmodic, antithrombotic, antihypertensive, antidiabetic, emetic, purgative, carminative, diuretic, galactagogue, emmenagogue, abortifacient, anthelmintic, aphrodisiac, and vision-strengthening [1, 2, 4, 7-11]. Ingestion is the main way of both administration and intoxication, but inhalation and fumigation are also frequent [1]. In western countries, *P. harmala* is increasingly used for psychoactive recreational purposes [1].

Some studies report poisoning with *P. harmala* and its ingredients in the literature. The subject is new and the words “Peganum” and “*P. harmala*” have been introduced into the Medical Subject Headings (MeSH) of the National Library of Medicine (NLM) in 2003 [12]. Moreover, the leading textbooks of medical toxicology have mentioned either no or very little information about *P. harmala* intoxication [13-16]. Here, we report a case of *P. harmala* intoxication in a pregnant woman and discuss the clinical signs and symptoms, treatment, and outcome.

2. Case Presentation

Our patient was a 31-year-old married woman with a history of unwanted pregnancy, who had decided to consume 1 glass (~50g) of comminuted ‘Espand-daneh’ (*P. harmala* seeds) with water to induce abortion. Two hours after ingestion, she had suffered from severe nausea and vomiting. The patient had been transferred to the emergency room of a local hospital in Fariman, Razavi Khorasan Province, Iran. She underwent Nasogastric Tube (NG-Tube) insertion and gastric washing with 2 liters of saline, as well as the administration of activated charcoal (50g) suspension via NG-Tube. After Intravenous (IV) access, the patient had received sodium chloride (0.9%) solution (1000 mL, IV, over 1 hour), Metoclopramide (10mg, IV), and Pantoprazole (40mg, IV). She was, then, admitted to the toxicology department of Imam Reza Hospital, Mashhad, Iran. Two hours later, the patient was awake, fully alert with no complaint, except with mild abdominal cramps. In further history taking, she claimed that her last menstrual period was about 8 weeks ago and her pregnancy test was positive. Hence, she consumed the seeds to induce abortion based on her neighbor’s recommendation. Her history was negative for a previous illness, allergy, food or drug sensitivity, medication use, smoking, or any substance abuse.

In physical examination, vital signs were stable (HR=80 bpm, RR=14 min, BP=115.65 mmHg, T=36.8°C, SpO₂=97%) and bedside glucometry was 89mg/dL. Pupils were midsize, symmetrical, and reactive to the light. The examination of the heart and the lungs were normal. There was a generalized abdominal tenderness on deep palpation. Fetal ultrasonographic assessment and additional laboratory tests were requested and performed based on gynecology consultation.

All laboratory analyses including electrolytes, hematologic, renal, and liver function tests were normal except mild hyponatremia, hypokalemia, and leukocytosis (Table 1). After about 6hours staying in the hospital, symptoms and signs of the intoxication relieved and the patient had no complaint or problem. Despite the physician’s recommendation for further observation, the patient left the hospital with her written express consent. Further follow-up by telephone revealed that 3 days after the ingestion of the seeds, she had experienced spontaneous expulsion of the fetus following abnormal vaginal bleeding and no other complications occurred.

Table 1. Laboratory results of the patient intoxicated by ingestion of *Peganum harmala* seeds (Tests were performed on admission)

	Test	Result	Normal Values	Unit
CBC/Diff	WBC	16.3	4.4-11.3	$\times 10^3 \mu\text{L}$
	- Neut	92.6	45-73	%
	- Lymp	5.3	20-45	%
	- Mixed (Mono + Eos + Baso)	2.1	5-9	%
	RBC	3.82	4.5-5.1	$\times 10^6 \mu\text{L}$
	Hemoglobin	12.7	12.3-15.3	g/dL
	Hematocrit	36.3	36-45	%
	MCV	95.0	80-96	fL
	MCH	33.2	26.5-32.5	pg
	MCHC	35.0	33-36	g/dL
	Platelets	160	150-450	$\times 10^3 \mu\text{L}$
Biochemistry	Plasma Sodium	133	135-145	mEq/L
	Plasma Potassium	3.4	3.5-5.3	mEq/L
	Plasma Calcium (Total)	8.9	8.5-10.5	mg/dL
	Plasma Magnesium	1.88	1.7-2.7	mg/dl
	Blood Glucose	123	-	mg/dL
	Urea	18	17-50	mg/dL
	Creatinine	0.7	Up to 1.5	mg/dL
	AST	12	5-40	U/L
	ALT	11	5-40	U/L
ALP	102	64-306	U/L	

International Journal of
Medical Toxicology & Forensic Medicine

ALT: Alanine Aminotransferase; ALP: Alkaline Phosphatase; AST: Aspartate Aminotransferase; CBC/Diff: Complete Blood Count with Differential; Lymp: Lymphocytes; MCH: Mean Corpuscular Hemoglobin; MCHC: Mean Corpuscular Hemoglobin Concentration; MCV: Mean Corpuscular Volume; Mixed (Mono+Eos+Baso): Monocytes+Eosinophils+Basophils; Neut: Neutrophils; RBC: Red Blood Cells; WBC: White Blood Cells

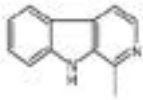
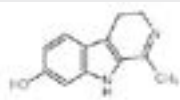
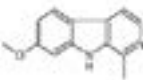
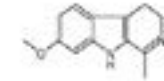
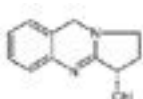
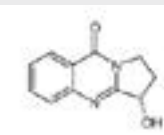
3. Discussion

Herbal medicine can be considered an alternative to some medical treatments. However, most people think that herbal medicines are harmless. Although the ingestion of *P. harmala* seeds usually leads to a transient and self-limited intoxication that recovers with supportive care, the consumption of high doses either accidentally and intentionally or for suicide attempt may be fatal [8].

While the recommended therapeutic dose ranges from 4-9g in TIM, there is a wide range of therapeutic dosages from 25 to 750 mg in modern phytotherapy [4]. The ingestion of low doses (3-4g) of the seeds may result in stimulant and hallucinogenic effects in humans, while large doses may cause more severe intoxication [2, 4, 5]. The higher therapeutic dose in TIM might be as a result of using the seeds with other corrective substances [4].

Pharmacologically-active compounds of *P. harmala* are several β -carboline alkaloids (harman, harmalol,

Table 2. Chemical properties of *Peganum harmala* alkaloids

Names	MeSH Entry Terms ¹	CAS Number ²	PubChem CID ¹	Molecular Formula ¹	Chemical Structure ³
Harman	1-methyl-beta-carboline harman harman hydrochloride harmane	486-84-0	5281404	C ₁₂ H ₁₀ N ₂	
Harmalol	harmalol harmalol dihydrochloride harmalol hydrochloride, dihydrate harmalol lactate, dihydrate harmalol trihydrate	6028-07-5	5353656	C ₁₂ H ₁₂ N ₂ O	
Harmine	Banisterine Harmine Leucoharmine Telepathine Yageine	442-51-3	5280953	C ₁₃ H ₁₂ N ₂ O	
Harmaline	Dihydroharmine Harmaline Harmidine	304-21-2	5280951	C ₁₃ H ₁₄ N ₂ O	
Vasicine	peganine peganine hydrochloride dihydrate vasicine vasicine hydrochloride, (R)-isomer vasicine monohydrochloride, (R)-isomer vasicine, (+)-isomer	6159-55-3	667496	C ₁₁ H ₁₂ N ₂ O	
Vasicinone	vasicinone	486-64-6	442935	C ₁₁ H ₁₀ N ₂ O ₂	

International Journal of
Medical Toxicology & Forensic Medicine

- Retrieved from PubChem Open Chemistry Database, URL: <https://pubchem.ncbi.nlm.nih.gov/search/#collection=compounds> [Last access: 21 Nov. 2018]
- A proprietary registry number assigned by the Chemical Abstracts Service (CAS) division of the American Chemical Society (ACS) often used to help describe chemical ingredients. URL: <https://www.cas.org/> [Last access: 21 Nov. 2018]
- Retrieved from URL: <http://www.molbase.com/> [Last access: 21 Nov. 2018]

harmine, harmaline) and quinazoline derivatives (vasicine and vasicinone) [4, 7, 16]. Table 2 presents the chemical properties of these alkaloids. β -carbolines can modulate the levels of amine neurotransmitters in the Central Nervous System (CNS) and induce a series of behavioral changes. Although controversial, the hallucinogenic effects of harmine and harmaline are suggested to be the result of their binding to 5-Hydroxytryptamine (5-HT or serotonin) receptors [2, 5, 7, 9]. Quinazoline alkaloids vasicine and vasicinone have been attributed to the abortifacient effect of the plant [7]. The highest levels of alkaloids (2%-7% of dry weight) are found in the

seeds and roots of the plant, while low levels are present in the stems and leaves, and none in flowers [2, 7].

The suggested mechanisms of toxicity of *P. harmala* include the inhibition of sodium-dependent transport, increasing the production of hypothalamic norepinephrine and serotonin, and decreasing the inhibitory synaptic transmission [17].

The clinical presentations of *P. harmala* intoxication mainly result from the involvement of gastrointestinal, cardiovascular, and nervous systems. Patients may have nausea, vomiting, bradycardia, hypotension, headache,

dizziness, euphoria, agitation, tremors, convulsions, visual hallucinations, altered mental status, hypoacusia, and paresthesia [2, 5, 9, 17]. A low-grade fever may also exist [9]. Monoamine Oxidase (MAO) inhibitory effect of harmaline can induce tachycardia or hypertension crisis as an unusual presentation, particularly when co-ingested with other drugs or foods [5, 16]. Nearly, all reported cases presented different kinds of impaired cerebellar function such as ataxia, nystagmus, abnormal knee to heel, or nose to finger tests. It seems that these are related to harmaline effect [9].

In a report of about 200 cases of *P. harmala* poisonings (older than 24 years) in Morocco, neurological, gastrointestinal, and cardiovascular manifestations were seen in (34.4%), (31.9%), and (15.8%) of the patients, respectively. In this report, the fatality rate was (6.2%) [2]. No sufficient data exist regarding the toxic effects of *P. harmala* during pregnancy; there was only 1 case report of spontaneous expulsion of the fetus in a 24-year-old woman, 22-week pregnant, intoxicated with the seeds of *Peganum harmala*. [7]. Another research has stated that the plant is contraindicated in pregnant women because of its abortive and mutagenic effects [5].

The definitive diagnosis of *P. harmala* intoxication depends on the identification of the plant or its alkaloids by High-Performance Liquid Chromatography (HPLC) or more sensitive methods, such as Gas Chromatography/Mass Spectrometry (GC/MS) [2]. There was only 1 case report of *P. harmala* intoxication in the literature, in which alkaloids were identified by GC/MS in the seeds extract and the patient's urine [2].

The management of *P. harmala* poisoning is mainly supportive [6, 9]. Soon after massive ingestion, the patient may benefit from gastric lavage and administering activated charcoal. However, Gastrointestinal (GI) decontamination should only be performed in patients with protected airway. Patients with severe agitation or delirium may respond to IV benzodiazepines [18]. Hypotension usually responds well to volume replacement therapy and rarely require any vasoconstrictors [6, 9]. Seizures may respond to benzodiazepines or other anti-convulsants such as barbiturates [18].

One limitation of this case report was the lack of laboratory confirmation because of the absence of appropriate analytical tools to detect *P. harmala* alkaloids in our hospital.

4. Conclusion

Poisoning with the high doses of *Peganum harmala* can be life-threatening, although patients usually recover with supportive cares alone. The main clinical presentations are gastrointestinal and neurological symptoms. The ingestion of *Peganum harmala* seeds during pregnancy may lead to abortion and should be avoided. Physicians working in the areas, where *Peganum harmala* is used as traditional medicine, must be aware of the clinical presentations of its toxicity to provide appropriate care such as early gastrointestinal decontamination, the administration of activated charcoal, fluid therapy, and other supportive cares.

Ethical Considerations

Compliance with ethical guidelines

All procedures involving the human participant were in accordance with the ethical standards of the institutional and or national research committee, the 1964 Helsinki Declaration, and its later amendments or comparable ethical standards.

Funding

This research did not receive any specific grant from funding agencies in the public, commercial, or not-for-profit sectors.

Author's contributions

Patient care, data acquisition, literature review, drafting and submitting the manuscript: Mohammad Delirrad; critically reviewed the draft for important intellectual content: Ali Banagozar Mohammadi, Maryam Vahabzadeh; revised it for English style and language: Maryam Vahabzadeh. Reviewe and approved the final and submitted version of the manuscript: Mohammad Delirrad, Maryam Vahabzade, Ali Banagozar Mohammadi.

Conflict of interest

The authors declare no conflict of interest.

Acknowledgements

We would like to thank Dr. Bita Dadpour for her expert advice and encouragement through this work.

References

- [1] Chevallier A. Encyclopedia of herbal medicine, 3rd edition. London: DK Publishing; 2016.
- [2] Frison G, Favretto D, Zancanaro F, Fazzin G, Ferrara SD. A case of beta-carboline alkaloid intoxication following ingestion of Peganum harmala seed extract. *Forensic Science International*. 2008; 179(2-3):e37-43. [DOI:10.1016/j.forsci-int.2008.05.003] [PMID]
- [3] Achour S, Rhalem N, Khattabi A, Lofti H, Mokhtari A, Soulaymani A, et al. [Peganum harmala L. Poisoning in Morocco: about 200 cases (Spanish)]. *Therapies*. 2012; 67(1):53-8. [DOI:10.2515/therapie/2012003] [PMID]
- [4] Mina CN, Farzaei MH, Gholamreza A. Medicinal properties of Peganum harmala L. in traditional Iranian medicine and modern phytotherapy: A review. *Journal of Traditional Chinese Medicine*. 2015; 35(1):104-9. [DOI:10.1016/S0254-6272(15)30016-9]
- [5] Yuruktumen A, Karaduman S, Bengi F, Fowler J. Syrian rue tea: A recipe for disaster. *Clinical Toxicology (Philadelphia)*. 2008; 46(8):749-52. [DOI:10.1080/15563650701323205] [PMID]
- [6] Mahmoudian M, Jalipour H, Salehian Dardashti P. Toxicity of Peganum harmala: Review and a case report. *Iranian Journal of Pharmacology and Therapeutics*. 2006; 1(1):1-4.
- [7] Berdai MA, Labib S, Harandou M. Peganum harmala L. intoxication in a pregnant woman. *Case Reports in Emergency Medicine*. 2014; 2014:783236. [DOI:10.1155/2014/783236] [PMID] [PMCID]
- [8] Sadr Mohammadi R, Bidaki R, Mirdrikvand F, Mostafavi Yazdi SN, Yazdian Anari P. Peganum harmala (aspad) intoxication: A case report. *Emergency (Tehran)*. 2016; 4(2):106-7. [PMID] [PMCID]
- [9] Moshiri M, Etemad L, Javidi S, Alizadeh A. Peganum harmala intoxication: A case report. *Avicenna Journal of Phytomedicine*. 2013; 3(3):288-92. [PMID] [PMCID]
- [10] Moloudizargari M, Mikaili P, Aghajanshakeri S, Asghari MH, Shayegh J. Pharmacological and therapeutic effects of Peganum harmala and its main alkaloids. *Pharmacognosy Reviews*. 2013; 7(14):199-212. [DOI:10.4103/0973-7847.120524] [PMID] [PMCID]
- [11] Amiri MS, Joharchi MR. Ethnobotanical investigation of traditional medicinal plants commercialized in the markets of Mashhad, Iran. *Avicenna Journal of Phytomedicine*. 2013; 3(3):254-71. [DOI:10.22038/AJP.2013.487]
- [12] Peganum (MeSH Unique ID: D032443). MeSH. [Internet]. Bethesda (MD): National Library of Medicine (US), National Center for Biotechnology Information [Internet]. 2003 [updated 2017 November 10].
- [13] Hoffman RS, Howland MA, Lewin NA, Nelson LS, Goldfrank LR. *Goldfrank's Toxicologic Emergencies*, 10th edition. New York: McGraw-Hill Education; 2014.
- [14] Shannon MW, Borron SW, Burns MJ, Haddad LM, Winchester JF. *Haddad and Winchester's clinical management of poisoning and drug overdose*. 4th edition. Philadelphia: Saunders/Elsevier; 2007.
- [15] Olson KR. *Poisoning and drug overdose*, 6th edition. New York: McGraw-Hill Education; 2011.
- [16] Brent J, Burkhart K, Dargan P, Hatten B, Megarbane B, Palmer R, White J. *Critical care toxicology: Diagnosis and management of the critically poisoned patient*. 2nd edition. Switzerland: Springer International Publishing; 2017. [DOI:10.1007/978-3-319-17900-1_186]
- [17] Hamouda C, Amamou M, Thabet H, Yacoub M, Hedhili A, Bescharnia F, et al. Plant poisonings from herbal medication admitted to a Tunisian toxicologic intensive care unit, 1983-1998. *Veterinary and Human Toxicology*. 2000; 42(3):137-41. [PMID]
- [18] Sharma AN, Hoffman RJ. Toxin-related seizures. *Emergency Medicine Clinics of North America*. 2011; 29(1):125-39. [DOI:10.1016/j.emc.2010.08.011] [PMID]