

Research Paper: The Value of Foramen Magnum Diameters for Gender Identification Among Iranian Population



Siamak Soltani¹, Kamran Aghakhani¹, Hanieh Saboori-Shekofte¹, Sahar Rismantab-Sani², Forouzan Faress¹, Tayebe Khayamdar^{1*}

1. Department of Forensic Medicine, School of Medicine, Iran University of Medical Sciences, Tehran, Iran.

2. Department of Gastroenterology, School of Medicine, Ramsar Campus, Mazandaran University of Medical Sciences, Ramsar, Iran.



Citation: Soltani S, Aghakhani K, Saboori-Shekofte H, Rismantab-Sani S, Faress F, Khayamdar T. The Value of Foramen Magnum Diameters for Gender Identification Among Iranian Population. International Journal of Medical Toxicology and Forensic Medicine. 2019; 9(4):205-212. <https://doi.org/10.32598/ijmtfm.v9i4.25367>

<https://doi.org/10.32598/ijmtfm.v9i4.25367>



Article info:

Received: 13 Jan 2019

First Revision: 25 Feb 2019

Accepted: 23 Jun 2019

Published: 01 Oct 2019

Keywords:

Foramen magnum, Gender identification, Iranian population

ABSTRACT

Background: By assessing the size of the foramen magnum, it is possible to distinguish two genders, as well as the intergenerational interdependence of the affected individuals. The present study aimed at assessing the value of diameters of foramen magnum for gender identification among the Iranian population.

Methods: This analytical comparative cross-sectional study was performed on 200 Iranian cadavers (100 men and 100 women) referred to Kahrizak Autopsy Hall in Tehran between 2017 and 2018. In each case, the foramen magnum was measured by observation and its parameters were measured in a longitudinal anteroposterior and transverse diameter, using a calibrated caliper.

Results: The Mean±SD anterior-posterior diameter of the foramen magnum in men and women were 35.59±0.49 mm and 33.90±1.07 mm, respectively, which was significantly higher in men (P<0.001). Similarly, the Mean±SD transverse diameter of the foramen magnum in males and females was 29.49±0.56 mm and 28.5±0.50 mm, respectively, which was significantly higher in men (P<0.001). Based on the area analysis under the Receiver Operating Characteristic (ROC) curve, the anterior-posterior and transverse diameters of the foramen magnum had a high value in the differentiation of the male and female genders (AUC=0.953 and 0.896, respectively, P<0.001). The Mean±SD foramen magnum index in men and women was 84.15±3.02 and 82.87±1.95, respectively, which had a significant difference between the two genders.

Conclusion: Given that the anterior-posterior and transverse diameters of the foramen magnum in Iranian men are far more than Iranian women, these diameters can be used to distinguish between the two genders in the precise legal field.

* Corresponding Author:

Tayebe Khayamdar, PhD.

Address: Department of Forensic Medicine, School of Medicine, Iran University of Medical Sciences, Tehran, Iran.

Tel: +98 (912) 5497355

E-mail: tayebekhayamdar9@gmail.com

1. Introduction

One of the essential requirements for corpse examination in forensic science is the recognition of identity and the identification using human skeletons is one of the legal skills of medical records [1]. Gender determination is one of the most important issues of identification. If all the skeletons of an individual are available, gender determination is not a problem and 100% of gender determination can be achieved with a complete skeleton [1]. However, sometimes there are only remnants of the human skeleton or fragments of the collapsed skeleton; for example, in air accidents, natural disasters, fire or mutilation, in which gender determination is not easy [2]. Scientists in this field are always looking for a way to solve this problem and find a sign of authentication in these cases. As a solution in these cases, experts in this field try to use the biological features of the human skeleton to determine gender [3].

Skull is the most convenient part of the skeleton for gender determination [1]. The human skeleton may have remained for centuries and one of the most resilient parts in the human skeletons is foramen magnum in the skull base. The foramen magnum is a large foramen in the skull base, which according to studies shows that the parameters of this foramen are useful in determining gender [4]. This foramen is a useful mark on the base of the skull, and its intuitive shape can be useful in identifying race and identity [5].

In addition to the importance of understanding the foramen magnum anatomy and its variations in the treatment of various types of diseases, it can be very important to evaluate these variances in the distinction between the two genders [6, 7]. Foramen magnum diameters are, therefore, used in forensic and anthropological methods to determine the gender of the human embryo [8-10]. It is worth noting that the area of the foramen magnum is completely covered by soft tissue mass. Therefore, the foramen magnum area should be evaluated by assessing changes in its soft tissue coverage. In total, the morphometric analysis of this foramen is highly diagnostic and useful in cases of traumatic injuries, accidents, and even fires. In fact, thanks to the major changes in these diameters in these injuries, it is sometimes possible to detect the gender of deceased persons only through some indicators, such as evaluating the magnitudes of the foramen magnum [11, 12]. In some studies, the foramen magnum diameters have been used to identify gender in cadavers [13, 14].

In total, it has been determined that the anterior-posterior and transverse diameters of the foramen magnum, in general, are higher in males than females [15, 16]. In some cases, the structural difference in foramen magnum in different races has been also shown [17]. Also, the relationship between the foramen magnum diameters in a person with the generations of that person is shown [18]. Therefore, by assessing the size of this foramen, it is possible to distinguish between two genders, as well as the intergenerational interdependence of the affected individuals. The present study aimed at assessing the value of diameters of foramen magnum for gender identification among the Iranian population.

2. Materials and Methods

This analytical comparative cross-sectional study was performed on 200 Iranian cadavers (100 men and 100 women) referred to Kahrizak Autopsy Hall in Tehran between 2017 and 2018. The subjects were in the age range of 20 to 60 years and included simple consecutive sampling. Cadavers that underwent forensic exploration because of unnatural death or suspected causes of death were included in the study and none was dissected just for the purpose of this study. Cadavers with traumatic injury and fractures in the skull were excluded. In each case, the foramen magnum was measured by observation and its parameters were measured in a longitudinal anteroposterior and transverse diameter, using a calibrated caliper. The foramen magnum index and its area were measured based on the specific formula. The shape of the foramen magnum was determined based on the defined patterns of the exterior check-list as round, oval, pentagon, hexagonal, and irregular with exact observation. The longitudinal diameter of the foramen magnum was measured as the maximum distance between anterior and posterior points of foramen magnum with a digital coulter. The transverse diameter of the foramen magnum was measured as the maximum distance between right and left ends (maximum width) of foramen magnum with a digital coulter. Foramen magnum index and area of foramen magnum were calculated based on the following Formulas 1, 2, 3 and 4:

$$1. \text{ Foramen magnum index} = (\text{Sagittal diameter} / \text{Transverse diameter}) \times 100$$

Area of foramen magnum based on Teixeira's Formula [4]:

$$2. \text{ FM Area} = \pi [(\text{Sagittal diameter} + \text{Transverse diameter}) / 4]^2$$

Area of foramen magnum based on Ritual's Formula [4]:

$$3. FM\ Area = Sagittal\ diameter \times Transverse\ diameter \times \pi/4$$

Average longitudinal and transverse diameter of foramen magnum:

$$4. (Sagittal\ diameter + Transverse\ diameter) / 2$$

For statistical analysis, the results were presented as Mean±SD for quantitative variables and were summarized by absolute frequencies and percentages for categorical variables. Categorical variables were compared, using the Chi-square test or Fisher's exact test when more than 20% of the cells with an expected count of less than five were observed. The quantitative variables were also compared with t test or Mann-Whitney U test. To measure the correlation between the values of diameters across the men and women, Pearson's correlation test was used. To assess the difference between men and women regarding foramen magnum diameters with the presence of baseline variables was assessed, using the Multivariable linear regression analysis. For the statistical analysis, the statistical software SPSS V. 16 for windows (SPSS Inc., Chicago, IL) was used. P-values of 0.05 or less were considered statistically significant.

3. Results

In this study, 100 male and 100 female samples were studied in terms of foramen magnum indices, including sagittal diameters (anterior-posterior) and transverse diameters. The age of the sample population was between 20 and 60 years old (Table 1). The Mean±SD anterior-posterior diameter of the foramen magnum in

men and women was 35.59±0.49 mm and 33.90±1.07 mm, respectively. The Mean±SD transverse diameter of the foramen magnum in males and females was 29.49±0.56 mm and 28.50±0.50 mm, respectively. The Mean±SD foramen magnum index in men and women was 82.87±1.95 and 84.15±3.02, respectively, and the Mean±SD foramen magnum area based on Teixeira's Formula in men and women was 831.33±18.98 and 764.58±29.18, respectively. The Mean±SD foramen magnum area based on Ritual's Formula in men and women was 823.92±19.35 and 758.59±27.80, respectively. All of the calculated parameters were significantly higher in men than women (P<0.001) (Table 2). Based on the area analysis under the Receiver Operating Characteristic (ROC) curve (Figure 1), all of the indices had high sensitivity and specificity in the differentiation of the male and female genders (Table 3). The association between gender and measured dimensions may be confounded by body mass index (BMI), which was not matched in both groups. To find the independent gender predictors among the measured variables and also to adjust for BMI, Logistic Regression analysis was applied (Table 4). Multivariate Logistic Regression analysis revealed that all of the calculated parameters were independent gender predictors.

4. Discussion

Various skeletal indices are used to distinguish genders in cases where gender detection is not possible through the evaluation of soft tissues (especially in the case of burns, traumas, and explosions). In previous studies, the evaluation of parameters such as the length and diameter of the upper and lower limbs, various skull sizes,

Table 1. Comparison of demographic characteristics between genders

Index	Gender	Mean±SD	Z1	P
Sagittal diameter (mm)	Female	33.90±1.07	-14.37	<0.001
	Male	35.59±0.49		
Transvers diameter(mm)	Female	28.50±0.50	-13.16	<0.001
	Male	29.49±0.56		
Foramen magnum index	Female	82.87±0.01	-18.99	<0.001
	Male	84.15±0.01		
Teixeriab formula	Female	764.58±29.18	-19.28	<0.001
	Male	831.33±18.98		
Ritual's formula	Female	758.59±27.80	-19.28	<0.001
	Male	823.92±19.35		
Mean of sagittal and transvers diameter	Female	31.20±0.60	-18.99	<0.001
	Male	32.54±0.37		

Table 2. Comparison of foramen magnum indices between two genders

Characteristics	Gender	Mean±SD	Min	Max	P
Age (Years)	Male	40.65±12.18	20	60	0.26
	Female	38.71±12.08	20	59	
BMI	Male	26.30±2.84	21.62	35.16	0.01
	Female	24.18±1.88	17.93	31.25	

International Journal of
Medical Toxicology & Forensic Medicine**Table 3.** The best cut-off point, sensitivity, and specificity

Index	Cut-off Point	Sensitivity (%)	Specificity (%)	P
Sagittal diameter (mm)	35.1	77	96	<0.001
Transvers diameter (mm)	29.2	67	92	<0.001
Foramen magnum index	83.4	100	91	<0.001
Teixeria formula	766.445	97	91	<0.001
Ritual's formula	789.49	97	90	<0.001
Mean of sagittal and transvers diameter	31.45	97	91	<0.001

International Journal of
Medical Toxicology & Forensic Medicine

short and wide bone diameters, as well as the apparent features of facial bones have led to their confirmation as distinctive indices of male and female. In this study, we examined the diagnostic value of diameters of the foramen magnum, including anterior-posterior diameters, transverse diameter, foramen magnum index, and area of the foramen magnum in male and female. By examining the parameters, their high diagnostic value for gender identification was confirmed, and all of them were significantly higher in men than that of women. Hence,

these diameters can be used to distinguish between the two genders in the Iranian population.

The review of the past studies was also fully consistent with the claims of this study but in other human societies. Most of the studies are conducted on the CT scan to evaluate foramen magnum parameters and in a few of them, such as the current study, foramen magnum diameters are calculated on skeleton and cadavers [19].

Table 4. Logistic regression analysis for gender prediction

Input Variables	Univariate Analysis					Multivariate Analysis				
	Beta	Odd's ratio	P	CI		Beta	P	Adjusted Odd's ratio	95%CI	
				0.025	0.975				0.025	0.975
Sagittal diameter (mm)	1.33	3.2	<0.001	23.108	461.11	1.21	<0.001	2.93	20.87	451.8
Transvers diameter (mm)	1.52	4.13	<0.001	10.221	55.960	1.54	<0.001	4.42	9.70	60.77
Foramen magnum index	0.20	0.82	<0.001	0.73	0.92	0.19	<0.001	0.82	0.73	0.92
Teixeria formula	0.163	1.177	<0.001	1.112	1.245	0.15	<0.001	1.16	1.10	1.23
Ritual's formula	0.151	1.163	<0.001	1.105	1.224	0.14	<0.001	0.15	1.10	1.21
Mean of sagittal and transvers diameter	1.87	4.52	<0.001	15.871	60.178	1.35	<0.001	3.62	13.73	278.165

International Journal of
Medical Toxicology & Forensic Medicine

Table 5. Comparison of foramen magnum indices in different studies

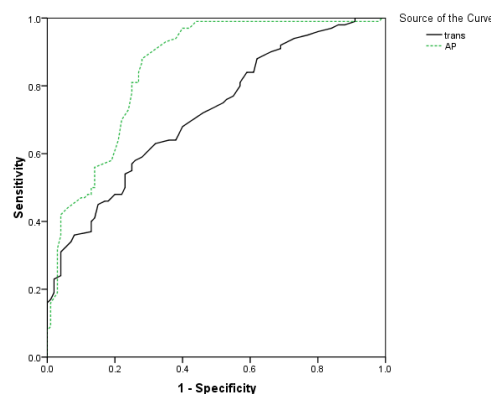
Study	Type of Sample	Number of Samples		Sagittal Diameter		Transverse Diameter		Area of the Foramen Magnum (Teixeria Formula mm ³)		Foramen Magnum Index	
		Female	Male	Female	Male	Female	Male	Female	Male	Female	Male
Current study	skull	100	100	33.90	35.59	28.50	29.49	764.58	831.33	82.87	84.15
Soltani et al. 2016 Iran [4]	CT scan	50	50	34.37	37.71	28.34	31.68	773.96	946.66	82.41	83.97
Edward et al. 2013 Switzerland [10]	CT scan	106	144	36.66	38.17	31.44	32.05	812.14	887.60	–	–
Kamath et al. 2015 India [21]	skull	31	41	30.99	33.21	25.45	26.96	630.57	715.32	–	–
Tellioglu et al. 2015 Turkey [19]	CT scan	50	50	32.99	34.73	28.40	30.47	–	–	–	–
Uthman et al. 2014 Iraq [1]	CT scan	45	43	32.90	34.90	27.30	29.50	670.20	765.20	–	–
Gapret et al. 2009 U.K [22]	skull	76	82	34.71	35.91	29.36	30.51	731.28	783.83	–	–
Madiam et al. 2017 Saudi Arabia [20]	CT scan	100	100	36.10	37.21	30.06	31.65	869.80	925.84	84.96	85.22

International Journal of
Medical Toxicology & Forensic Medicine

In the study of Soltani et al. in 2016, foramen magnum diameters were calculated based on the CT scan in the Iranian population. The sample size was 100 (50 males and 50 females). Sagittal diameter, transverse diameter, foramen magnum index, and foramen magnum area were in a close range with the current study and the

minor difference could be because of the method of the measurement [4]. The results are compared in Table 5.

In the study of Tellioglu et al. in Turkey, foramen magnum diameters were evaluated in 100 CT scans [20]. The mean of anterior-posterior diameters, transverse diameter, and cavity surface area was significantly higher



International Journal of
Medical Toxicology & Forensic Medicine

Figure 1. Diagnostic value of foramen magnum diameters in gender differentiation based on ROC curve

in men than in men (Table 5). They used univariate and multivariate discriminant analysis and revealed that anteroposterior diameter could be able to detect 64% of women and 70% of men. In the current study, foramen magnum parameters had an acceptable level of sensitivity and specificity in gender determination (Table 3).

In our study, there was a significant relationship between BMI and gender. To reveal the independent predictor parameters, we used multivariate logistics regression and found all calculated parameters to predict gender notwithstanding BMI (Table 4).

In a study by Madadin et al. in Saudi Arabia, sagittal diameter, transverse diameter, and area of foramen magnum were significantly higher in men than in women. All of the dimensions were greater than what we found in this study. They calculated foramen magnum index 84.96 in women and 85.22 in men. In our study, the foramen magnum index was 82.87 in women and 84.15 in men. This variation could be because of different ethnic groups and suggest that dimensions should be evaluated separately in different societies and races [21]. The study of Kamath et al. in India [22] also showed a significant difference in foramen magnum parameters between two genders (Table 5).

In assessing and comparing the values of foramen magnum dimensions in different societies, we conclude that the measurements of these diameters are very effective in the differentiation of the two genders; also, in different societies and races, they are highly adaptive in the corresponding diameters.

This determines the common origin of all human races in terms of the growth and development of skeletal structures. The techniques of measuring the corresponding diameters (using manual methods or using advanced imaging techniques), as well as the inclusion criteria, are very effective in measuring these indices in various studies. Therefore, in determining the final limits for cranial diameters in different societies and in order to achieve comprehensive human diameters, the use of common measurement techniques and the alignment of the inclusion criteria are necessary.

5. Conclusion

As a general conclusion, given that the anterior-posterior and transverse diameters of the foramen magnum, foramen magnum index, and area of the foramen magnum in Iranian men are far more than Iranian women,

these diameters can be used to distinguish between the two genders in the precise legal field.

Ethical Considerations

Compliance with ethical guidelines

The research protocol was approved by the Ethics Committee of the Iran University of Medical Sciences, Tehran, Iran. The approval number: IR,IUMS,FMD,R EC,139609511223005.

Funding

This research was extracted from the MD. thesis of Tayebe Khayamdar in the Department of Forensic Legal Medicine, Hazrat Rasul Akram Hospital, Iran University of Medical Sciences, Tehran.

Author's contributions

Data gathering and data preparation: Siamak Soltani, Tayebe Khayamdar, and Foroozan Fares; Designing and conducting the research, performing the statistical analyses, participating in all stages of the research, preparing, and editing the manuscript: Siamak Soltani and Kamran Aghakhani; Designing and conducting the research and correcting the English manuscript: Hanieh Saboori-shekofta, Siamak Soltani, Tayebe Khayamdar, and Sahar Rismantab-sani; and Reading and approving the content of the manuscript: Siamak Soltani, Tayebe Khayamdar, Kamran Aghakhani, Hanieh Saboori-Shekofta, Sahar Rismantab-sani, and Foroozan Fares.

Conflicts of interest

The authors declared no conflict of interest.

Acknowledgments

The authors wish to express appreciation to Legal Medicine Organization of Iran (Tehran autopsy hall) for collaborating in collecting samples.

References

- [1] Uthman AT, Al-Rawi NH, Al-Timimi JF. Evaluation of foramen magnum in gender determination using helical CT scanning. *Dentomaxillofacial Radiology*. 2012; 41(3):197-202. [DOI:10.1259/dmfr/21276789]

- [2] Günay Y, Altinkök M. The value of the size of foramen magnum in sex determination. *Journal of Clinical Forensic Medicine*. 2000; 7(3):147-9. [DOI:10.1054/jcfm.2000.0430] [PMID]
- [3] Krishan K, Chatterjee PM, Kanchan T, Kaur S, Baryah N, Singh RK. A review of sex estimation techniques during examination of skeletal remains in forensic anthropology case-work. *Forensic Science International*. 2016; 261:165-e1-e8. [DOI:10.1016/j.forsciint.2016.02.007] [PMID]
- [4] Aghakhani K, Kazemzadeh N, Ghafurian F, Soltani B, Soltani S. Gender determination using diagnostic values of foramen magnum. *International Journal of Medical Toxicology and Forensic Medicine*. 2016; 6(1):29-35. [DOI:10.22037/ijmtfm.v6i1(Winter).9503]
- [5] Poonamjeet L, Ongeti K, Pulei A, Ogengo J, Mandela P. Gender related patterns in the shape and dimensions of the foramen magnum in an adult Kenyan population. *Anatomy Journal of Africa*. 2013; 2(2):138-41.
- [6] Kanodia G, Parihar V, Yadav YR, Bhatle PR, Sharma D. Morphometric analysis of posterior fossa and foramen magnum. *Journal of Neurosciences in Rural Practice*. 2012; 3(3):261-6. [DOI:10.4103/0976-3147.102602] [PMID] [PMCID]
- [7] Standardizing S. *Gray's anatomy: The anatomical basis of clinical practice*. London: Elsevier Churchill Livingstone; 2005.
- [8] Kanchan T, Gupta A, Krishan K. Craniometric analysis of foramen magnum for estimation of sex. *International Journal of Medical, Health, Biomedical and Pharmaceutical Engineering*. 2013; 7(7):111-3.
- [9] Suazo Galdames IC, Perez Russo P, Zavando Matamala DA, Smith RL. Sexual dimorphism in the foramen magnum dimensions. *International Journal of Morphology*. 2009; 27(1):21-3. [DOI:10.4067/S0717-95022009000100003]
- [10] Edwards K, Viner MD, Schweitzer W, Thali MJ. Sex determination from the foramen magnum. *Journal of Forensic Radiology and Imaging*. 2013; 1(4):186-92. [DOI:10.1016/j.jofri.2013.06.004]
- [11] Manoel CC, Prado FB, Caria PH, Groppo FC. Morphometric analysis of the foramen magnum in human skulls of Brazilian individuals: Its relation to gender. *Brazilian Journal for Morphological Sciences*. 2009; 26(2):104-8.
- [12] Shepur MP, Magi M, Nanjundappa B, Havaladar PP, Gogi P, Saheb SH. Morphometric analysis of foramen magnum. *International Journal of Anatomy and Research*. 2014; 2:249-55.
- [13] Holland TD. Sex determination of fragmentary crania by analysis of the cranial base. *American Journal of Physical Anthropology*. 1986; 70(2):203-8. [DOI:10.1002/ajpa.1330700207] [PMID]
- [14] Graw M. [Morphometrische und morphognostische Geschlechtsdiagnostik an der menschlichen Schadelbasis (German)]. *Osteologische Identifikation und Altersschätzung*. 2001:103-21.
- [15] Barut NR, Kale AN, Turan Suslu HK, Ozturk A, Bozbuga M, Sahinoglu K. Evaluation of the bony landmarks in transcondylar approach. *British Journal of Neurosurgery*. 2009; 23(3):276-81. [DOI:10.1080/02688690902814725] [PMID]
- [16] Furtado SV, Thakre DJ, Venkatesh PK, Reddy K, Hegde AS. Morphometric analysis of foramen magnum dimensions and intracranial volume in pediatric Chiari I malformation. *Acta Neurochirurgica*. 2010; 152(2):221-7. [DOI:10.1007/s00701-009-0480-5] [PMID]
- [17] Howale DS, Bathija A, Gupta S, Pandit DP. Correlation between cranial index and foramen magnum index in human dried skulls. *Global Journal For Research Analysis*. 2014; 3(1):3-6. [DOI:10.15373/22778160/January2014/65]
- [18] Kumar A, Dave M, Anwar S. Morphometric evaluation of foramen magnum in dry human skulls. *International Journal of Anatomy and Research*. 2015; 3(2):1015-23. [DOI:10.5137/1019-5149.IJTA.4297-11.1] [PMID]
- [19] Singh PK, Tamrakar D, Karki S, Menezes RG. Determination of sex from the foramen magnum using 3DCT: A nepalese study. *Kathmandu University Medical Journal*. 2017; 15(57):62-6.
- [20] Tellioglu AMI, Durum Y, Gok M, Karakas S, Polat AG, Karaman CZ. Suitability of foramen magnum measurements in sex determination and their clinical significance. *Folia Morphologica*. 2018; 77(1):99-104. [DOI:10.5603/FM.a2017.0070] [PMID]
- [21] Madadin M, Menezes RG, Al Saif HS, Alola HA, Al Muhanna A, Gullenpet AH, et al. Morphometric evaluation of the foramen magnum for sex determination: A study from Saudi Arabia. *Journal of Forensic and Legal Medicine*. 2017; 46:66-71. [DOI:10.1016/j.jflm.2017.01.001] [PMID]
- [22] Kamath VG, Asif M, Shetty R, Avadhani R. Binary logistic regression analysis of foramen magnum dimensions for sex determination. *Anatomy Research International*. 2015; 2015(459428):1-9. [DOI:10.1155/2015/459428] [PMID] [PMCID]

This Page Intentionally Left Blank
