

Case Report: An Unusually High Blood Alcohol Level in a Burnt Child Homicide Victim



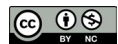Masoud Ghadipasha¹ , Maryam Akhgari^{1*}

1. Legal Medicine Research Center, Iranian legal Medicine Organization, Tehran, Iran.



Citation: Ghadipasha M, Akhgari M. An Unusually High Blood Alcohol Level in a Burnt Child Homicide Victim. International Journal of Medical Toxicology and Forensic Medicine. 2019; 9(1):45-49. [https://doi.org/10.22037/ijmtfm.v9i1\(Winter\).23486](https://doi.org/10.22037/ijmtfm.v9i1(Winter).23486)

[https://doi.org/10.22037/ijmtfm.v9i1\(Winter\).23486](https://doi.org/10.22037/ijmtfm.v9i1(Winter).23486)



Article info:

Received: 12 Jul 2018

First Revision: 03 Aug 2018

Accepted: 28 Nov 2018

Published: 01 Jan 2019

Keywords:

Criminal burning, Postmortem examination, Forensic toxicology, Alcohol, Cause of death

ABSTRACT

Background: Alcohol detection is one of the most prevalent requests in forensic toxicology laboratories for medico-legal investigation. Interpretation of analytical toxicology results is important in deciding the cause and manner of death. The aim of the present case report is to introduce an unusually high blood alcohol level in a homicide victim and interpretation of analytical toxicology results considering crime scene investigation.

Case Presentation: In the present study, we report a case of a burnt body on which autopsy examination and forensic toxicology analyses were carried out. Autopsy examination showed several stab wounds in the neck and thorax regions. Forensic toxicology analysis results showed 1055 mg/dL ethanol and 71 mg/dL methanol in right heart blood using headspace gas chromatography. The leading cause of death was stab wounds. Burning seemed to be a tool for covering up the homicide. Use of alcoholic fire accelerant and contamination of the corpse with alcohol was the main reason to detect high blood alcohol levels.

Conclusion: It is essential to determine ethanol in different sampling sites to reach a reliable and scientific interpretation of analytical toxicology results. Also, some important factors such as crime scene investigation should be considered in the interpretations of unusual forensic toxicology results.

1. Introduction

Homicide was the leading cause of death of about 500000 people all over the world in 2012 [1]. Identification of the criminal burning and cause of death of a burnt body are of crucial importance in forensic practice. There are several ways to cover up homicide and criminal actions, including burning, burying,

or throwing the dead body in water [2]. Determining the cause and manner of death in burnt bodies raises a challenging task to forensic practitioners [2]. Therefore it is fundamental to look for trauma, stab wounds, and other injuries as the leading cause of death before burning [3].

Some important questions asked from forensic practitioners and also forensic toxicologists are whether any criminal act is involved or there is any probability

* Corresponding Author:

Maryam Akhgari, PhD.

Address: Legal Medicine Research Center, Legal Medicine Organization, Tehran, Iran.

Tel: +98 (912) 2125864

E-mail: akhgari1349@yahoo.com

of being poisoned and what the source of drugs and substances in postmortem samples are [4]. The issue of whether the person was alive before being in fire scene has been addressed by several researchers. In a study conducted on 88 burned corpses, it was reported that some key factors such as histologically soot deposits in the respiratory tract, esophagus, stomach and also positive carboxyhemoglobin levels can be categorized as vitality signs in burned bodies [5].

In his case report, Caughlin discussed an unusual source of postmortem findings of methyl ethyl ketone and methanol in two homicide victims [6]. Evidence from France and Turkey studies suggest that criminal burning seemed to be a means of covering up homicide [2, 3]. Postmortem forensic toxicology analysis and interpretation of obtained results are important issues for experts engaged in court cases [7]. It has been proven that in rare cases, the interpretation of blood ethanol analysis results requires answering some questions prior to medico-legal decision making [8]. The purpose of the present study was to draw attention to the proper interpretation of postmortem forensic toxicology analysis results in burnt bodies.

2. Case Presentation

Our case was a 6-year-old girl. Her parents saw her two days before discovering her body in the bathtub of the neighbor's house. Bloodstains were detected on the floor of the bathroom. Two empty capped bottles with alcohol smell were found beside the bathtub. The bottles were labeled as "denatured alcohol". The case was examined with regard to accompanying injuries, autopsy examination, and manner of death. Total body surface area was carbonized over 70%. In autopsy examination, it was found that the victim had been stabbed with a sharp knife several times in the neck and thorax.

Soot was not detected in her upper airway, esophagus, and stomach. Systematic toxicological analysis was performed on liver, gastric content and right heart blood (containing 2% w/v sodium fluoride) samples using thin layer chromatography as screening and High-Performance Liquid Chromatography (HPLC) and Gas Chromatography/Mass Spectrometry (GC/MS) as confirmatory tests for the detection of organic drugs. The urinary bladder was empty and femoral vein blood could not be obtained due to the burning the surface of the body. The method for the detection of ethanol and methanol was validated and the calibration curve was drawn using 100, 200, 400, and 600 mg/dL of methanol and ethanol ($r^2=0.999$).

The Limit of Detection (LOD) and Limit of Quantitation (LOQ) for methanol and ethanol were 0.1 and 1 mg/dL, respectively. Toxicological analysis showed blood alcohol concentrations as 1055 mg/dL and 71 mg/dL for ethanol and methanol, respectively using Head Space Gas Chromatography (HSGC) instrumentation. Analytical separation of methanol and ethanol was achieved using HSGC (Agilent 6890N, USA) equipped with a Flame Ionization Detector (FID). The column for GC (gas chromatography) was DB-ALC1 (30 m×320 μm ×1.5 μm).

In the present study, an Agilent HSGC system was used to allow automated sample pretreatment and injection. The sample volume was set at 1000 μL . The incubation temperature was 60°C for 15 min before injection. The syringe and loop-transfer line temperatures were set at 60°C and 140°C, respectively. The GC injector and detector temperatures were set at 150°C and 300°C, respectively. The FID detector was used for quantitative analysis of methanol and ethanol in the blood sample. The blood sample was diluted to fit on the calibration curve and back-calculated for nominal concentration. Figure 1 shows the chromatogram of ethanol and methanol in the blood sample.

Alcohol was not detected in gastric content and liver tissue. The toxicological study was negative for opioids, amphetamine-type stimulants, benzodiazepines, barbiturates, and other drugs and poisons. Furthermore, the blood sample analysis results for Carboxyhemoglobin (CO-Hb) and cyanide were negative. The vitreous humor sample could not be collected because of the major destruction of the face. No spermatozoa were identified on vaginal, anal and oral swabs. During forensic psychiatric assessment and offender's blood alcohol analysis, it was concluded that blood ethanol level was equal to 258 mg/dL and the offender was under the influence of alcohol.

3. Discussion

The purpose of the present study was to report an unusual source of postmortem findings of high blood alcohol concentration in a burnt homicide victim. In many instances, the manner and cause of death in burnt bodies is difficult to be determined. It is essential to look for the cause of death in burnt bodies and investigating antemortem fire exposure. Autopsy reports, systematic toxicological analysis, crime scene investigation, and police reports often help determine the cause of death.

In the present study, the autopsy report showed that the offender stabbed the victim several times in the neck and

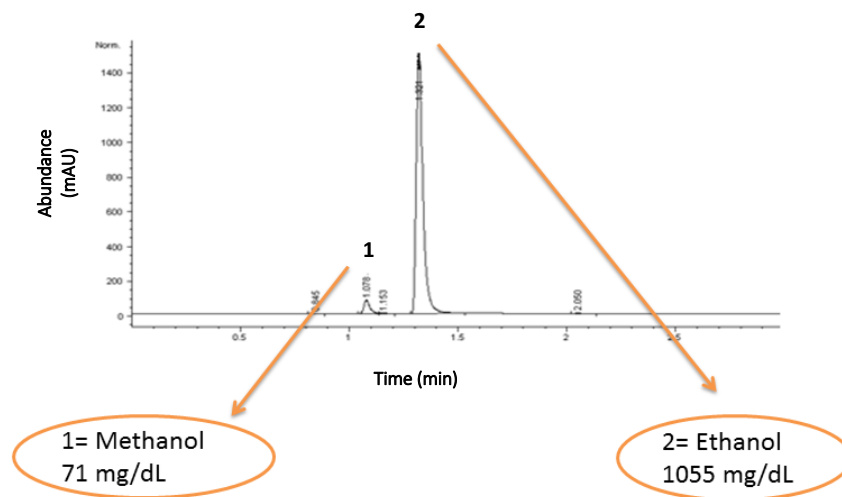
International Journal of
Medical Toxicology & Forensic Medicine

Figure 1. The ethanol and methanol concentrations in right heart blood of the homicide victim burnt case after death

thorax. The stab wounds were over the anterior thorax wall and accompanied by internal organs (heart) ruptures. This finding is in accordance with previous studies that reported the thorax was one of the most affected regions to be traumatized by stab wounds [7].

Results of the postmortem toxicological analysis indicated that the right heart blood sample contained a high concentration of ethanol, and to a lesser extent, methanol. The interpretation of postmortem alcohol concentration and the source of ethanol in biological samples is one of the most vexing problems faced by forensic practitioners [9]. Ethanol may be produced or lost from the body due to microbial (*Candida albicans*, *Proteus* spp., *Escherichia coli*, *Staphylococcus* spp.) activity from the time of death to autopsy in the intact body or in vitro in biological samples [9, 10].

Analytical findings can be best interpreted by reviewing the circumstances and scene investigation. Two empty alcohol bottles were found beside the victim in the bathtub. It was supposed that the offender had poured denatured alcohol on the dead body to accelerate the fire. Denatured alcohol is a flammable liquid consisting of methanol, ethanol, and methyl isobutyl ketone used as a fuel for alcohol burners and camping stoves [11].

One assumption in the interpretation of high blood alcohol level is the diffusion of ethanol and methanol from perforating trauma to the surrounding blood vessels because of a concentration gradient. Therefore postmortem contamination of body with an alcoholic solution was a plausible explanation for high blood alcohol concentration. It should be mentioned that with the support of strong evidence, the suspected neighbor confessed soon

after the decision-making about the cause and manner of death to use denatured alcohol as fire accelerant for burning dead body.

A fire accelerant is used to increase the rate of fire production for materials that will not burn under typical fire conditions [12]. Consequently, it would be prudent that the subject had used an alcoholic solvent (ethanol and methanol mixture) as fire accelerant due to the finding of empty alcohol bottles in the scene investigation. Femoral vein whole blood and vitreous humor samples are among the most suitable samples in the official medico-legal investigation [9]. These two valuable samples were not available in the present case.

A number of postmortem processes influence blood alcohol concentration. Bacterial action, diffusion from the gastrointestinal tract, and contamination are factors to be considered in the interpretation of postmortem ethanol concentration [9]. It is already impossible to assume that ethanol was produced after death. According to the literature, alcohol may be produced as high as 200 mg/dL during the putrefaction process [3]. Also, postmortem redistribution of ethanol from ingested alcoholic beverages could be ruled out as a result of negative results for alcohols in liver tissue and gastric content samples.

It was worth noticing that blood analysis for CO-Hb and cyanide was negative. Various toxic gases such as Hydrogen Cyanide (HCN) and Carbon monoxide (CO) are generated in the fire site. There are some reports about the role of HCN and CO in fire victims. Domestic fire can be one of the sources of cyanide production due to the burning of wool, silk, and plastic textures under pyrolysis conditions at high temperature [13].

Some authors assert that HCN poisoning is the main toxic agent, others, however, consider CO to be the main lethal toxic agent under fire condition [14]. None of these toxic agents were found in postmortem samples in the present study. Also in accordance with other studies on postmortem burning, no soot was detected in the respiratory or gastrointestinal tract [2]. One strong possible explanation for these findings is that the victim was exposed to the fire after death. However, in rare cases, vital signs may be negative, despite the exposure of the victim to fire during breathing [2].

The offender in the present study was under the influence of ethanol when the crime had taken place. The police were unable to establish a motive for murder. Alcohol abuse is recognized to be one of the important contributory factors in the incidence of violent crime, child abuse, suicide, and many personality disorders [15].

4. Conclusion

The mission of a forensic practitioner is to establish whether the death was accidental, suicidal, homicidal, etc. Postmortem medico-legal investigation with complete toxicological analysis and autopsy examination are important to determine and classify unnatural deaths in children.

Ethical Considerations

Compliance with ethical guidelines

The study protocol was in conformity with the ethical guidelines of the 1975 Declaration of Helsinki, revised in 1983. Private information, including name, surname, and burial permit was removed from the data sheet to comply with ethical concerns. According to Legal Medicine Research Center, Legal Medicine Organization, and Iran Ethics Committee, the information about human cadavers was fully confidential.

Funding

This research did not receive any specific grant from funding agencies in the public, commercial, or not-for-profit sectors.

Authors contributions

Design of the study: All Authors; Data collection: Masoud Ghadipasha; Interpretation of the data and drafted the manuscript: Maryam Akhgari; and read and approved the final version of the manuscript: All Authors.

Conflict of interest

The authors declared no conflict of interest.

References

- [1] United Nations Office on Drugs and Crime. Global study on homicide. Vienna: United Nations Publication; 2013.
- [2] Tümer AR, Akçan R, Karacaoğlu E, Balseven-Odabaşı A, Ketan A, Kanburoğlu C, et al. Postmortem burning of the corpses following homicide. *Journal of Forensic and Legal Medicine*. 2012; 19(4):223-8. [DOI:10.1016/j.jflm.2012.01.001]
- [3] Fanton L, Jdeed K, Tilhet-Coartet S, Malicier D. Criminal-burning. *Forensic Science International*. 2006; 158(2-3):87-93. [DOI.org/10.1016/j.forsciint.2005.04.040] [PMID]
- [4] Athanaselis S, Stefanidou M, Koutselinis A. Interpretation of postmortem alcohol concentrations. *Forensic Science International*. 2005; 149(2-3):289-91. [DOI:10.1016/j.forsciint.2003.04.001]
- [5] Bohnert M, Werner CR, Pollak S. Problems associated with the diagnosis of vitality in burned bodies. *Forensic Science International*. 2003; 135(3):197-205. [DOI:10.1016/S0379-0738(03)00214-7]
- [6] Caughlin JD. An unusual source for postmortem findings of methyl ethyl ketone and methanol in two homicide victims. *Forensic Science International*. 1994; 67(1):27-31. [DOI:10.1016/0379-0738(94)90408-1]
- [7] Hwa HL, Pan CH, Shu GM, Chang CH, Lee TT, Lee JC. Child homicide victims in forensic autopsy in Taiwan: A 10-year retrospective study. *Forensic Science International*. 2015; 257:413-9. [DOI:10.1016/j.forsciint.2015.10.020]
- [8] Odell MS, Young GR. Apparent elevated blood alcohol due to laboratory artefact: A potential cause of misinterpretation. *Journal of Forensic and Legal Medicine*. 2016; 44:27-8. [DOI:10.1016/j.jflm.2016.08.007]
- [9] Kugelberg FC, Jones AW. Interpreting results of ethanol analysis in postmortem specimens: A review of the literature. *Forensic Science International*. 2007; 165(1):10-29. [DOI:10.1016/j.forsciint.2006.05.004] [PMID]
- [10] Laurens JB, Sewell FJJ, Kock MM. Pre-analytical factors related to the stability of ethanol concentration during storage of ante-mortem blood alcohol specimens. *Journal of Forensic and Legal Medicine*. 2018; 58:155-63. [DOI:10.1016/j.jflm.2018.06.003]
- [11] Helmenstine AM. What Is denatured alcohol or ethanol? [Internet]. 2018 [Updated 2018 March 23]. Available from: <https://www.thoughtco.com/what-is-denatured-alcohol-p2-603999>
- [12] Wikipedia. Fire accelerant [Internet]. 2018 [Updated 2018 May 6]. Available from: https://en.wikipedia.org/wiki/Fire_accelerant
- [13] Akhgari M, Baghdadi F, Kadkhodaei A. Cyanide poisoning related deaths, a four-year experience and review of

the literature. Australian Journal of Forensic Sciences. 2016; 48(2):186-94. [DOI:10.1080/00450618.2015.1045552]

- [14] Ferrari LA, Giannuzzi L. Assessment of carboxyhemoglobin, hydrogen cyanide and methemoglobin in fire victims: A novel approach. Forensic Science International. 2015; 256:46-52. [DOI:10.1016/j.forsciint.2015.08.010]
- [15] Mc Sweeney T. Calling time on 'alcohol-related' crime? Examining the impact of court-mandated alcohol treatment on offending using propensity score matching. Criminology & Criminal Justice. 2015; 15(4):464-83. [DOI:10.1177/1748895814561471]