

Unsuspected Tracheal Web with Asthma-Like Symptom in a Young Female: Case Report

Moinazad-Tehrani M¹, Agin K^{1*}

¹ Department of Internal Medicine, Loghman Hakim Hospital, Shahid Beheshti University of Medical Sciences, Tehran, Iran

ARTICLE INFO

Article Type:
Case Report

Article History:
Received: 2 Feb 2016
Revised: -
Accepted: 12 Feb 2016

Keywords:
Asthma
Tracheal webfinding
Vocal Cord Dysfunction

ABSTRACT

Background: Although most patients with asthma are easily controlled with appropriate medication, a small proportion of patients (approximately 5% of asthmatics) are difficult to control despite maximal inhaled therapy.

Case Report: A 20-year-old girl admitted to the emergency ward (EW) of loghman hakim hospital in tehran with severe dyspnea. She was born with asphyxia for which oxygen therapy prescribed for two days. **Conclusion:** Congenital abnormality of the trachea can rarely present as asthma symptoms in adulthood. It is important to know, when encounter too difficult to treat asthma as the condition can be curable surgically.

Copyright©2016 Forensic Medicine and Toxicology Department. All rights reserved.

► *Implication for health policy/practice/research/medical education:* Unsuspected Tracheal Web with Asthma-Like Symptom

► *Please cite this paper as:* Moinazad-Tehrani M, Agin K. *Unsuspected Tracheal Web with Asthma-Like Symptom in a Young Female: Case Report. International Journal of Medical Toxicology and Forensic Medicine.* 2016; 6(3): 175-8.

1. Introduction:

Although most patients with asthma are easily controlled with appropriate medication, a small proportion of patients (approximately 5% of asthmatics) are difficult to control despite maximal inhaled therapy.

2. Case Report:

A 20-year-old girl admitted to the emergency ward (EW) of loghman hakim hospital in tehran with severe dyspnea. She

was hospitalized in the last year over three times with attack asthma. The label of recent admission was refractory asthma. Expiratory stridor was the noticeable record in the last attack. History has shown a previous bronchial asthma for three years. Physical examination revealed in the EW including; weight 67 Kg, respiratory rate 25, blood pressure 140/95 mmHg and temperature 37.5C. General inspiratory and expiratory wheezes detected in both lung fields. Chest x-ray disclosed over inflation pattern with the clear lung field. Laboratory data were WBC 8500, Hgb 12.5mg/dl. Arterial blood gas was 95%. However, the value of anti-nuclear antibody (ANA), PPD and ESR were negative, induration 5mm and 12mm,

Corresponding author: Agin K, MD. Department of Internal Medicine, Loghman Hakim Hospital, Shahid Beheshti University of Medical Sciences, Tehran, Iran.

E-mail: khosrow.agin@yahoo.com

respectively. Standard treatment of asthma performed.

She was born with asphyxia for which oxygen therapy prescribed for two days. She has an allergic dermatitis history. She is studying in university and living in a university dormitory under stressful condition recently one year. She had a history of dyspnea and exertional palpitation last six months before admission. A generalized decrease of vesicular sounds all over the lungs and intermittent stridor were noticed in the recent physical examination within a chest clinic. Vocal cord dysfunction suggested the diagnosis in the medical record with following spirometry parametric records;

FEV1: means 0.4 lit (pred 2.9 lit, pred13.6%)

FVC: means 0.5 lit (pred 3.4 lit, pred 14.9%)

FEV1/FVC ratio: 80%

FEV1/VC: 6%

FEV1 in post bronchodilator spirometry (15 minutes after 4 puffs of salbutamol 100 mcg per dose) was 0.5 lit and no response after bronchodilator was detected.

Asthma attack was again occurring during the admission period in the ward. Inspiratory stridor presented for several minutes associated with severe generalized wheezing. Bronchoscopy procedure was scheduled for upper airway evaluation after the stability of the patient. The larynx space was a normal shape without laryngomalacia, movement of vocal cords was synchronized and no abnormality detected. The incomplete ring of tissue (web) suddenly demonstrated beyond the vocal cord movement. The decided was not to evaluate the lower airway in the first phase. The patient showed severe airway irritability.

Chest CT scan without contrast was normal. Three-dimensional spiral CT Scan indicated two short-segment web-like subglottic trachea webs. They were taken placed 12 mm and 30 mm distance from true vocal cords with incomplete circles. Distal trachea, main bronchi, and lobar bronchi are intact without the stenosis. Also, no intraluminal tracheal mass was detected. Echocardiography was performed with no

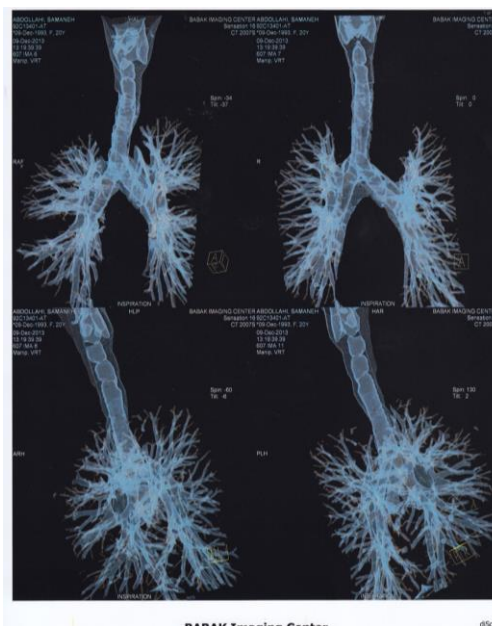

Fig. 1. Picture showed tree-dimensional chest CT.

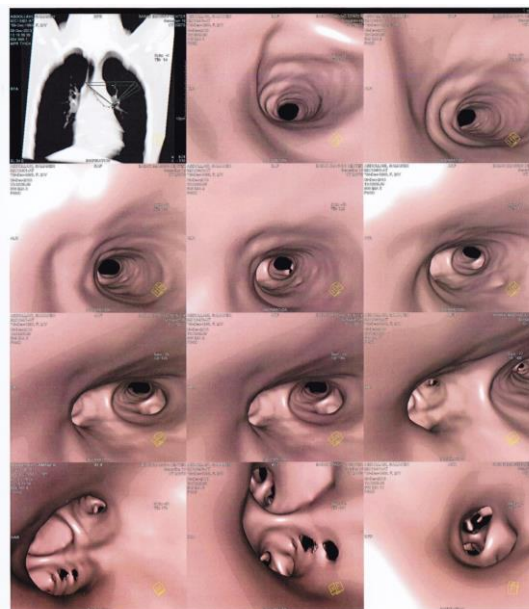


Fig. 2. Picture disclose virtual bronchoscopy in patient with tracheal web.

abnormality, and the pulmonary arterial pressure was 25 mmHg.

She was referred to an ENT surgery service. The follow-up visit carried out three, six and 12 months post-surgery. Excised TW was successfully carried out. Stridor as the main feature of the disease completely disappeared, and hospitalization decreased. The patient performance was excellent, and medical consumption diminished for controlling asthma.



Fig. 3. Picture presents conventional CT scan of case.

3. Discussion:

The congenital tracheal web (TW) is a rare anomaly, usually misdiagnosed as an asthma-like symptom or obstructive tracheal pattern (1-3). TW is a tissue layer that covered tracheal lumen. The web usually is incomplete and is not associated with tracheal cartilage abnormality or deformity. It is presented as congenital or acquired (1-3) forms and coincidental finding during clinical evaluation (4). TW incidence has not been reported in adults as yet, and a few cases reported on the database searching (3-7). Tracheal webs are known as a late complication of the endotracheal intubation and post-tracheostomy in the adults' population. Children incidence was 1 in 10000 births and also characterized as a rare cases (4).

Bronchoscopy and CT scan reconstruction are a reliable and sensitive method of evaluation TW in suspected cases (8, 9). Sensitivity, specificity, and accuracy reported 93%, 100%, and 94% respectively. Figure 1, 2, and 3 showed the position of tracheal webs in different imagines.

Our case had two incomplete web rings in the proximity of tracheal lumen. Web rings' position, lead to the stenosis symptom such as stridor and prominent dyspnea in the

acute attack state of asthma. The recent clinical feature demonstrates functional tracheal narrowing. It may be intensified clinical manifestation of airway obstruction symptoms and raised morbidity and mortality rate during exacerbation disease. It may be assumed that if the patient was not suffering from asthma disease, the diagnosis of TW has not been occurring at the early age.

4. Conclusion:

The tracheal web is a rare disease in the adult population, and diagnosis is incidental.

5. Acknowledgement:

The author appreciates from the patient for allowing to publication disease data.

6. References:

1. Lee JE, Chang MY, Kim KH, Jung YH. Post-intubation tracheoesophageal fistula with posterior glottic web. *Clin Exp Otorhinolaryngol.* 2011;4(2):105-8.
2. Ozdulger A, Birbicer H, Duce MN. Tracheal web: presentation of a case with uncommon features. *J Bronchology Interv Pulmonol.* 2009 Jan;16(1):46-8.
3. Nakamura Y, Kurasako N, Iwaki T, Fukushima T, Ishizu T, Tanaka T, Kosogabe Y, Tokioka H. [Unexpected difficult intubation caused by a laryngeal web]. *Masui.* 2000;49(11):1278-80.
4. Nguyen NK. Unexpected tracheal web encountered during difficult intubation in the operating room. *Proc (Bayl Univ Med Cent).* 2006;19(3):224-5.
5. Yin Y, Zhang L. Successful diagnosis and treatment of congenital tracheal web using a fiberoptic bronchoscope. *Saudi Med J.* 2010;31(10):1166-8.
6. Virmani S, Uppal R, Kiro K, Bhandari H, Dutta D, Singh N, et al. Successful double lumen tube insertion in a patient with unanticipated laryngeal and tracheal web. *Ann Card Anaesth.* 2011;14(3):211-3.
7. Yamamoto S, Tetsuka K, Sato Y, Endo S. Unsuspected tracheal web inhibits endotracheal intubation: report of a case. *J Anesth.* 2010;24(1):132-3.
8. Legasto AC, Haller JO, Giusti RJ. Tracheal web. *Pediatric radiology.* 2004;34(3):256-8.
9. Whyte RI, Quint LE, Kazerooni EA, Cascade PN, Iannettoni MD, Orringer MB. Helical computed tomography for the evaluation of

tracheal stenosis. *Annl Thoracis Surgery.* 1995;60(1):27–31.