

Stab Injury with Tailoring Scissor Causing Inferior Gluteal Artery Pseudo Aneurysm: a Rare Case Report

Haseen MA^{1*}, Mahmud AA¹, Arshad M², Haneef-Beg M¹

¹ Department of Cardiothoracic Surgery, JNMCH, AMU, Aligarh, India

² Department of Surgery, JNMCH, AMU, Aligarh, India

ARTICLE INFO

Article Type:
Case Report

Article History:
Received: 15 July 2015
Revised: 29 July 2015
Accepted: 13 Aug 2015

Keywords:
Inferior gluteal artery
Pseudoaneurysm
Tailoring scissor

ABSTRACT

Background: Gluteal artery pseudo aneurysm (GAP) is a rare entity, as gluteal arteries are well protected under muscles and fat of gluteal region. Gluteal artery aneurysms constitute less than 1% of all aneurysms and most of them are pseudo aneurysms. The common etiologies of GAP are blunt or penetrating trauma to gluteal region, infection, fractures of the pelvis or iatrogenic injury during surgical procedures on the pelvis or hips to intramuscular injection. The usual presentation is a pulsatile gluteal mass often confused with a gluteal abscess presenting 1-2 months after injury. However, at times it can cause symptoms due to compression of pelvic structures.

Case Report: Our patient was a young boy who had injury to his right gluteal region with a tailoring scissor during a scuffle. He presented to casualty in shock with packing of wound done outside. After resuscitation his Computed tomographic angiography (CT angiography) revealed a pseudoaneurysm of inferior gluteal artery. He was immediately taken up for surgery a transperitoneal ligation of internal iliac artery of the involved side was done along with exploration of the gluteal wound.

Conclusion: These patients of Gluteal artery aneurysms can be managed with both open and endovascular techniques. Our patient was unique in the respect that no GAP has been reported after stab injury with a tailoring scissor and ours is first case report in English literature. We want that the surgeons should keep in mind the possibility of GAP while dealing with even trivial injuries of gluteal region.

Copyright©2015 Forensic Medicine and Toxicology Department. All rights reserved.

► *Implication for health policy/practice/research/medical education:* Stab Injury with Tailoring Scissor and Inferior Gluteal Artery Pseudo Aneurysm

► *Please cite this paper as:* Haseen MA, Mahmud AA, Arshad M, Haneef-Beg M. Stab Injury with Tailoring Scissor Causing Inferior Gluteal Artery Pseudo Aneurysm: a Rare Case Report. International Journal of Medical Toxicology and Forensic Medicine. 2015; 5(4): 218-21.

1. Introduction:

Gluteal artery pseudo aneurysm (GAP) is a rare entity, as gluteal arteries are well

Corresponding author: Haseen MA, MD. Assistant Professor, Department of Cardiothoracic Surgery, JNMCH, AMU, Aligarh, India
E-mail: azamjnm@gmail.com

protected under muscles and fat of gluteal region. The exact incidence is unknown, however isolated aneurysms of the gluteal artery constitute less than 1% of all aneurysms and most of them are pseudo aneurysms (1). Superior gluteal artery (SGA) injury and aneurysms are more common than the inferior gluteal artery (2). There are

several causes leading to formation of gluteal artery pseudo aneurysms (GAP) ranging from blunt or penetrating trauma to gluteal region, infection, fractures of the pelvis or iatrogenic injury during surgical procedures on the pelvis or hips to intramuscular injection (3-5). A few other rare causes like atherosclerosis, polyarteritis nodosa and persistent sciatic artery have also been mentioned in literature (6). The usual presentation is a pulsatile gluteal mass often confused with a gluteal abscess presenting 1-2 months after injury. However, at times it can reach a diameter of 50 to 60 mm and cause symptoms due to compression of pelvic structures like venous obstruction, neurologic compression with radicular pain or numbness, and urologic symptoms with the possibility of renal failure and intestinal compression (7). These patients can be managed with both open and endovascular techniques (8). We present a case of inferior gluteal artery pseudo aneurysm occurring after stab to gluteal region with a tailoring scissor, with active bleeding which was managed with a transperitoneal approach.

2. Case Report:

A brutal murder with hundreds of wounds A 14 year old male presented to our emergency with history of stab to the right gluteal region with a scissor (figure 1) 3 days ago. The boy presented in shock and was resuscitated; there was history of active bleeding from the wound at the time of injury which was managed with packing of the wound. Since the dressing was repeatedly getting soaked, he was referred to our hospital. A CT angiogram was performed which demonstrated a contrast filled structure in direct communication with the inferior gluteal artery 4.2x3.6x3.2 cm (Figure 2, 3). Since the child was hemodynamically unstable and non-availability of endovascular interventional facilities at our center, the patient was taken up for surgery and a transperitoneal approach was used to explore the artery. As the patient's condition was unstable the right internal iliac artery was ligated in to, and search for the individual branches was not made. There was no apparent bowel or other



Fig. 1. It shows the tailoring scissor with sharp edges and long prongs.

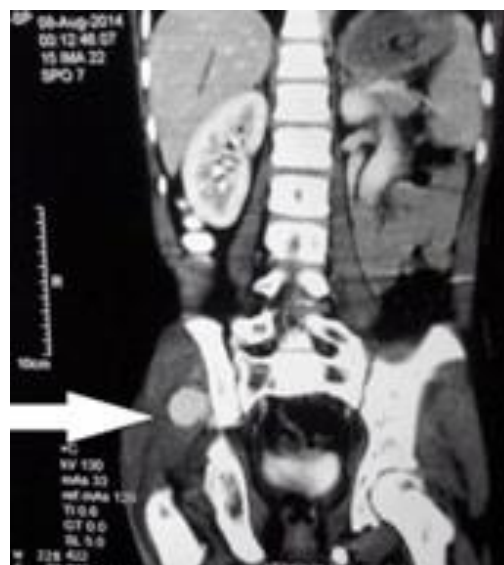


Fig. 2. White arrow shows contrast filled Pseudo-aneurysm of the right inferior gluteal artery.

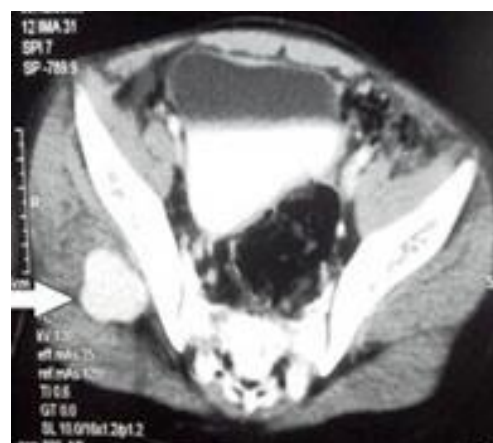

Fig. 3. White arrow points to the pseudo-aneurysm of the inferior artery in coronal section.

visceral injury. Exploration through the gluteal stab wound site was also carried out as there was active ooze from it hemostasis was achieved and the wound was closed in two layers. Post operatively the patient

showed steady improvement and was discharged after 1 week in satisfactory condition.

3. Discussion:

Arterial aneurysms have two types; true or actual arterial wall dilatation wherein the swelling consists of all the three layers of an artery, and false (pseudo) condensed communicating. Perarterial fibrous tissue arising after traumatic disruption of the arterial wall and consists only of a fibrous wall that surrounds the hematoma (9). Gluteal artery pseudo aneurysms (GAP) have varied presentations from an asymptomatic pulsatile mass, to symptoms of sciatic nerve compression and massive bleeding due to accidental or iatrogenic puncture of the aneurysm (10). Our patient presented with active bleeding following a stab injury by tailoring scissor which did not subside even after packing.

Usually the first investigation is an arterial Doppler; however the investigation of choice is a CT angiogram. MR angiography can also be used but does not have any added advantage over CT angiograms. Angiography although being the gold standard investigation is usually reserved for stable patients or those in whom angiographic embolization of the aneurysm is planned (10), our case was actively bleeding. We directly opted for a CT angiogram to confirm the site of bleeding and plan management. Open surgery has been the standard of care for Gluteal artery pseudoaneurysms (GAP) for many years, however this approach is now being challenged by endovascular techniques (7, 8, 10). For aneurysms that are very large or involving the part of gluteal artery proximal to the sciatic foramen there is a need to control the iliac artery by a transperitoneal approach, while an entirely extra pelvic aneurysm can be managed by posterior buttock approach⁹. Surgery is effective in treating the aneurysm and removing thrombus to decrease pressure symptoms; but it has its drawbacks like difficulty of exposure, invasiveness and risk of iatrogenic injuries and infection (11, 12).

Standard surgical therapy for gluteal artery aneurysms involves a trans peritoneal or retroperitoneal approach for proximal control coupled with direct endoaneurysmorrhaphy via a gluteal incision. Although this technique prevents the refilling of the sac by collateral vessels and completely resolves compressive symptoms, several reports of surgical treatment of iliac aneurysm showed an increased mortality risk, with various rates from 0 to 10% (13). Some authors have also proposed isolated surgical ligation of the internal iliac artery via an extraperitoneal approach as the only treatment needed, however studies show that ligation of the internal iliac artery resulted in only a 50% decrease in efferent flow because of extensive collateral pathways between the gluteal, lumbar, sacral, and rectal arteries (14). Endovascular coil embolization is an attractive option for treatment as it is less invasive, more specific and avoids damage to surrounding retroperitoneal nerves and structures but a hematoma around the artery causing compression to the surrounding structures cannot be cleared. Endovascular treatment is especially recommended in certain group of patients of GAP who are asymptomatic, have diameter of less than 50mm or in high-risk patients (15).

In addition to embolization, endovascular therapy using stent grafting as well as direct thrombin injection has been suggested by some authors as a treatment option (8, 11, 16). Although no major complications have occurred, there are few reports of coil dislodgement and migration. This can be reduced by the use of the newer longer and more pliable coils (9). In addition to embolization, direct thrombin injection has been suggested by some authors as a treatment option (11). Thrombin injection is routinely practiced in the treatment of femoral artery pseudo-aneurysms complicating catheterization (16). Thrombin injection was found more successful in acute superficial aneurysms with narrow necks. In rare cases, thrombin reflux into the circulation with undesired serious thrombosis has been reported (17).

Although individual ligation or reconstruction of the offending vessel is preferred (18), in our case due to hemodynamic instability of the patient and non-availability, direct ligation of the right internal iliac artery was done through a trans peritoneal approach and further hemostasis was achieved via gluteal incision. The patient recovered well and is in our follow up with no complaints.

5. Conclusion:

Gluteal artery aneurysms although a rare entity should be kept in mind while treating patients of acute or chronic trauma presenting with active bleed or a pulsatile gluteal mass. Although endovascular embolization techniques being less invasive are showing promising results in the management of these conditions, open surgical treatment still has a place in management especially in the haemodynamically unstable patient and large aneurysms with compression symptoms. CT, US, and MRI play a useful role in early diagnosis of these lesions and allow prompt treatment. In conclusion gluteal artery pseudo-aneurysms are a challenge both for the surgeon and the interventional radiologist to treat.

References

- Mouawad NJ, Haurani MJ, Mason T, Satiani B. Delayed presentation and management of blunt traumatic inferior gluteal artery pseudo-aneurysm with associated arteriovenous fistula. *Vasc Endovascular Surg*. 2013 Oct;47(7):573-6.
- Smyth NP, Rizzoli HV, Ordman CW, Khoury JN, Chiocca JC. Gluteal aneurysm. *Arch Surg*. 1965;91(6):1014-20.
- Maled I, Velez R, Lopez R, Batalla L, Caja VL. Pseudoaneurysm of the superior gluteal artery during iliosacral screw fixation. *Acta Orthop Belg*. 2007;73:544-7.
- Fujimura N, Obara H, Matsumoto K, Kitagawa Y. Mycotic aneurysm of the superior gluteal artery in a patient with bacterial endocarditis: Case report and review of the literature. *Vascular*. 2011;19:47-50.
- Saad PF, Saad KR, Armstrong DO, Soares BF, Almeida PD, Filho AR. Inferior gluteal artery pseudo-aneurysm related to intramuscular injection. *Int J Surg Case Rep*. 2015;6:629-32.
- Schorn B, Reitmeier F, Falk V, Oestmann JW, Dalichau H, Mohr FW. True aneurysm of the superior gluteal artery: case report and review of the literature. *J Vasc Surg*. 1995;21(5):851-4.
- Ge PS, Ng G, Ishaque BM, Gelabert H, de Virgilio C. Iatrogenic pseudoaneurysm of the superior gluteal artery presenting as pelvic mass with foot drop and sciatica: Case report and review of literature. *Vasc Endovascular Surg*. 2010;44:64-8.
- Roblin P, Alexiou T, Sabharwal T, Reidy J, Ross DA. Successful stent graft placement for the treatment of a superior gluteal artery aneurysm in a patient following complex pelvic surgery. *Br J Radiol*. 2007;80:7-10.
- Singh V, Maini L. Inferior gluteal artery pseudoaneurysm Mimicking a gluteal abscess- a rare but dangerous presentation. *JMGIMS*. 2008;13(1):58-61.
- Sawsan T, Asim D, Maali T. Superior Gluteal Artery Pseudoaneurysm Presenting as a Gluteal Mass: Case Report and Review of Literature. *J Clin Imaging Sci*. 2013;3:49.
- Rubinstein C, Edean ED, Minion DJ, Sorial EE, O'Keefe SD. Thrombin Injection for the Treatment of Mycotic Gluteal Aneurysm. *Vasc Endovascular Surg*. 2012;46:77-9.
- Vasseur MA, Doisy VC, Prat AG, Stankowiak C. Coil embolization of a gluteal false aneurysm in a patient with Marfan syndrome. *J Vasc Surg*. 1998;27(1):177-9.
- Nachbur BH, Inderbitzi RG, Bär W. Isolated iliac aneurysms. *Eur J Vasc Surg*. 1991;5(4):375-81.
- Burchell RC. Physiology of internal iliac artery ligation. *J Obstet Gynaecol Br Commonw*. 1968;75(6):642-51.
- dé Medici L, Bucci F, Nesi F, Rabitti G. Embolization of isolated hypogastric artery aneurysm: a case report and a review of the literature. *Cardiovasc Intervent Radiol*. 2006;29(5):893-6.
- Haseen MA, Mohd F, Beg-Mohd H, Naiyyer A, Saifullah K. Femoral artery Pseudoaneurysm following trivial trauma : a rare case scenario. *Indian J Thorac Cardiovasc Surg*; 2015;31(1):34-7.
- Mohler ER, Mitchell ME, Carpenter JP, Strandness DE J, Jaff MR, Beckman JA, Gerhard-Herman M. Therapeutic thrombin injection of pseudo-aneurysms: a multicentre experience. *Vasc Med*. 2001;6(4):241-410.
- Greco F, Popa R, Bulgariu T, Motoc I, Ursulescu C, Grigoras I. Double Surgical Approach For Extrapelvic Pseudoaneurysm of Inferior Gluteal Artery. *IJS/7/2/12691*.