

Hepatotoxicity Due To Mushroom Poisoning: A Case Report

Baniasad N¹, Oghabian Z^{2*}, Mehrpour O³

¹ Department of Internal Medical, Gastroenterologist, Afzalipour Hospital, Kerman University of Medical Sciences, Kerman, Iran

² Department of Clinical Toxicology, Forensic Medicine and Clinical Toxicologist, Kerman University of Medical Sciences, Kerman, Iran

³ Department of Clinical Toxicology, Birjand University of Medical Sciences, Birjand, Iran

ARTICLE INFO

Article Type:
Case Report

Article History:
Received: 16 Aug 2013
Revised: 16 Sep 2013
Accepted: 1 Feb 2014

Keywords:
Amanita
Mushroom Poisoning
High-Dose Penicillin
N-AcetylCysteine
Silymarin

ABSTRACT

Background: Although the majority of mushroom ingestions are benign, some result in significant toxicity and death. Of greatest concern is the hepatotoxic amatoxin-containing mushroom, which may be fatal even small ingestions. Identification of amatoxin poisoning can prove to be difficult due to delay in onset of symptoms and difficulty with identification of mushrooms.

Case Report: We present one case of mushroom ingestion in Kerman, province what according to clinical course and laboratory finding, we believe to be an amanita species, treated with multiple dose of activated charcoal, N-acetylcysteine, high-dose penicillin and liver Gol (silymarin).

Conclusion: We present the successful treatment a patient who ingested hepato-toxicity induced mushrooms, further, this case is evidence of a mushroom variety responsible for toxicity never previously implicated in the southeastern Iran.

Copyright©2014 Forensic Medicine and Toxicology Department. All rights reserved.

► *Implication for health policy/practice/research/medical education:*
Hepatotoxicity Due To Mushroom Poisoning

► *Please cite this paper as:* Baniasad N, Oghabian Z, Mehrpour O. *Hepatotoxicity Due To Mushroom Poisoning: A Case report. International Journal of Medical Toxicology and Forensic Medicine.* 2014; 4(2): 68-73.

1. Introduction:

Of the possibly 10000 species of mushrooms world wide, only so to 100 are known to be toxic (1).

Although the majority of mushrooms ingestions are benign, some result in significant toxicity and death (2). Analysis

Corresponding author: Oghabian Z, MD. Department of Clinical Toxicology, Forensic Medicine and Clinical Toxicologist, Kerman University of Medical Sciences, Kerman, Iran

E-mail: zoghabian@yahoo.com

of exposures reported to poison control centers in the United States indicates that the precise species of mushrooms is identified in only 3.4% of all exposures (3). The cyclopeptide-containing mushrooms are responsible for more than 90% of all deaths due to mushrooms poisoning in the western world (1). Of greatest concern are the hepatotoxic amatoxin-containing mushrooms, which maybe fatal after even small ingestions. Amatoxin poisoning may be difficult to diagnose due to delayed onset of

symptoms (2). we present successful treatment of one case of mushroom poisoning that according to clinical course and laboratory finding, suggested that must be amatoxin containing–mushroom.

2. Case Report:

A 66 years old woman, who live in region near Kerman city and without any past medical histories presented to Kerman Afzalipour hospital with complaints of nausea vomiting, sever watery diarrhea, weakness and moderate abdominal pain after ingestion of mushrooms she reportedly picked the mushrooms which was growing along the river in her home . She fried the mushrooms and ingested it with egg. The mushroom was described as coupled and having white colored cap. She ate the mushroom at approximately 9:00 PM.

The following day at approximately 7:00 am (10h later), she started developing nausea vomiting, sever watery diarrhea and RUQ pain.

she presented to Kerman Afzalipour hospital at approximately 10:00 pm .the patient`s initial vital signs were, temperature 36.6°C orally pulse 110 beats/min, blood pressure 120/80mm/Hg respiratory rate 26 breaths/min and oxygen saturation 95% on ambient air.

her initial aspartate aminotransferase (AST) was 97 IU/L (normal range 5-40 IU/L), alanine aminotransferase (ALT) was 56 IU/L (normal range 5-40 IU/L), and international normalized ratio (INR) was 1.5 (normal range 0.8-1.2), in the complete blood cell count leukocytosis and in ABG a mild metabolic acidosis was noted. On physical examination, the patient had right upper quadrant tenderness to palpation. Neither had guarding nor rebound.

The rest of physical examination was otherwise normal. Fluid and electrolyte resuscitation was performed and 12h later the patient had no gastrointestinal complain except RUQ pain, serial laboratory data we noted rising in AST and ALT (Table 1, Fig. 1).

according to clinical course and laboratory data we identified probably Amatoxin-containing mushrooms poisoning and the following treatment regimen was started: 60gr activated charcoal (AC) and then multiple dose activated charcoal (MDAC) with 30gr (0.5gr/kg) (AC) continued every 4 hours for 24h.

N-Acetylcysteine (NAC) at 150 mg/kg loading dose intravenous (i.v.) and then the NAC continued at 50mg/kg dose over 9h, followed by 100mg/kg over 16h. NAC continued in following day at 150 mg/kg 1 day dose until decreasing liver aminotransferase.

High-dose penicillin G (10000000 units/kg/day/Iv) for 48h and was continued at 5000000 units/kg/day/IV, until decreasing liver aminotransferase (day 5).

Liver Gol (70 mg/bid/dose) and vit. K (10 mg/day) were continued orally during hospitalization. Abdominal sonography was normal. the patient`s peak AST was 753 IU/L and ALT was 1326 IU/L approximately 36-48h after ingestion (table 1, fig.1) the patient`s transaminase levels eventually began trending down ward approximately 72h after mushrooms ingestion.

the patient was discharged on hospital day 6 with AST 80 IU/L and ALT 398IU/L. seven day follow up (14-day after ingestion revealed AST 20 IU/L and ALT 57 IU/L.

A follow up telephone conversation 1 month after discharge revealed that the patient was asymptomatic, with no evidence of ongoing toxicity or sequelae.

3. Discussion:

Amatoxin poisoning maybe is difficult to diagnose due to the delayed onset of symptoms (2).

Amatoxin-containing mushrooms cause >95% of mushrooms–ingestion deaths (4).

In a retrospective study of mushrooms poisoning in Iran, from 1992 to 2002, of the 72421 poisoning cases admitted to Loghman-Hakim hospital poison center 37

Table 1: Laboratory Findings

Laboratory tests	12h	24h	36h	Day2	Day3	Day4	Day5	Day6	Day14
WBC (K/ μ L)	15.200	15.600	13.800	-	6.300	7000	-	7.700	-
Hb (g/dl)	14.9	13.6	13.3	-	12	12.4	-	11.1	-
Plt (k/ μ l)	470	455	316	-	281	289	-	309	-
Ast (Iu/L)	97	252	753	600	224	115	58	80	20
Alt (Iu/L)	56	203	1246	1326	1132	892	489	398	57
Bili (total,Mg/dl)	0.9	0.5	0.8	0.7	0.7	0.5	0.4	0.6	0.3
Bilirubin ,Mg/dl (Direct	0.3	0.2	0.2	0.3	0.3	0.2	0.2	0.2	0.1
PT (second)	16.5	14.5	21.5	>38	14.1	17.5	13	14.8	12
PTT (second)	38	31	52	>100	43	34	30	4.1	35
INR	1.5	1.2	2.3	>5.6	1.1	1.6	1	1.2	1
BUN	78	83	45	22	40	15	13	23	20
Cr	1.8	1.8	1.1	1	1	1.1	1.1	1.1	0.8
PH	7.31	7.33	7.38	7.43	7.43	7.42	7.38	7.44	7.43
HCO ₃	15.7	17.3	17.2	16.8	21.2	24.0	22.6	22.1	24
Bs	144	139	-	100	-	114	-	117	100
Alb	-	-	-	3.4	-	-	2.9	-	3.7
Total protein	-	-	-	6.5	-	-	5.4	-	6.4

cases poisoned by consumption of toxic mushrooms (5).

In 2011 in Arak, a 6-years-girl with *Amanita phalloides* intoxication misdiagnosed as acute appendicitis and expired (6).

A study during 1989-1994 in Tabriz describes 34 cases with *Amanita phalloides* mushrooms poisoning (7).

In 2002 in Shiraz, a 26y/o man soldier with GI complaints after ingestion come mushrooms, developed hepatic failure and died (8).

In a report in 2011 a Vietnamese family living in the Pacific Northwest after ingestion wild mushrooms, one of them died and two developed hepatic injury (9).

In 1992 in North America, 92 individuals died after inadvertently ingestion poisonous *amanita* species (10).

For a patient with a history of toxic mushrooms ingestion, the clinical picture may help determine to which group the mushroom belonged, pending definitive identification. In majority of cases, the true identity of offending mushroom is unknown (1).

The cyclopeptide-containing mushrooms are found mainly in species from three genera: *Amanita*, *Galerina* and *lepiota* (1).

The vast majority of serious poisoning and fatalities in this group of mushrooms result from *Amanita*, particularly *Amanita phalloides* (1).

Ingestion of deadly *Amanita* most commonly occurs after misidentification of the mushrooms by foragers, although the possibility of criminal or terrorist use of toxins isolated from *Amanita* species has also been suggested (11).

The cyclopeptide toxins consist primarily of amatoxins, which contain eight amino acids and the seven residue phallotoxins and virotoxins (1).

Amatoxins are not only extremely potent hepatotoxins but are also actively absorbed from the GI tract. α -amanitin is the principal toxin in this group.

Nucleoli of liver cells disintegrate soon after exposure to α -amanitin, resulting in interference with transcription of DNA by inhibiting RNA polymerase II. Because the primary action of amatoxins is inhibition of DNA transcription, tissues that are highly dependent on protein synthesis

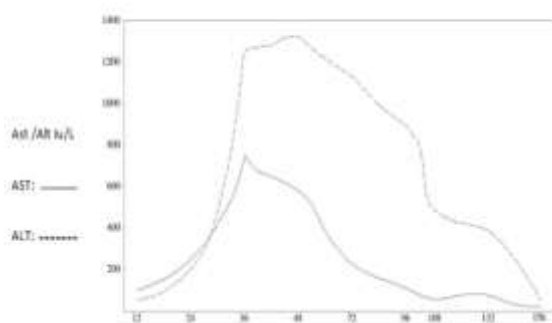


Fig. 1. AST and ALT results.

(namely, the GI tract and liver) are most sensitive to this poisoning (1).

Circulating amatoxins are not metabolized but excreted by the biliary system and the kidneys. Enterohepatic recirculation and biliary excretion of amatoxins are significant.

The cyclopeptides are not denatured by boiling and hence cooking deadly amanita mushrooms does not render them non-toxic. It is estimated that approximately 0.1mg/kg of oral mushroom may be lethal to an adult (12).

Clinical presentation:

The classic clinical presentation of amanita poisoning can be divided into three stages. Patients do not have GI symptoms for at least 6 hours after ingestion, and then they develop colicky abdominal pain, vomiting and severe diarrhea (stage 1).

The onset of symptoms may occur from 6 to 24 hours after ingestion. The diarrhea may contain blood and mucus and may be so severe that it has been termed cholera-like.

Even without treatment, patients may apparently recover (stage 2).

Although their hepatic enzyme levels may be raising two to 4 days after ingestion, patients may suffer fulminant hepatitis, cardiac and renal failure (stage 3).

Pancreatitis, disseminated intravascular coagulation, convulsions and death may then occur in the subsequent 2 to 4 days (1).

4. Diagnosis:

The diagnosis of cyclopeptide mushroom poisoning is made largely from a positive history of ingestion coupled with suggestive physical findings (e.g, acute gastroenteritis, and toxic hepatitis). Optimally, the mushroom (obtained from meal leftovers or from visiting the site of foraging) could be identified by an experienced mycologist, but this is rarely possible.

Circulating amatoxins can be detected for hours after ingestion (13).

Most of the ingested α -amanitin is excreted renally and urine levels tend to be higher than serum levels, although amatoxins can be detected by very sensitive radio immunoassay or high-pressure liquid chromatographic methods these assays are not usually clinically available (1).

Management options for patients with ingestions or toxicity are varied and controversial.

General after stabilization and airway management, intravenous fluids and anti-emetics are likely required because most patients present with nausea and vomiting. Patients who present with vomiting within 6h are more likely to have ingested a more benign mushroom, however, it can never be assumed that patients presenting with nausea and vomiting before 6h have not ingested a lethal mushroom, because co-ingestion of both lethal and non-lethal mushrooms can occur (2).

Multiple dose activated charcoals (MDAC): patients may be administered AC as amatoxins are enterohepatically circulated.

Patients presenting early in the course of illness who have not yet developed hepatic injury may also benefit from repeat dose AC (2).

N-acetylcysteine (NAC) .NAC has been advocated on the theoretical basis that it reduces radical-induced injury and restores redox capacity in injured cells (2).

It may also be beneficial in preventing liver injury via free radical or oxygen-

scavenging capabilities after ingestion (14).

A report of 11 patients with apparent poisonous *A phalloides* poisoning treated with infusion of N-acetylcysteine (NAC) reported survival in all, with only one patient requiring liver transplantation (15). Also, due to NAC's benign side effect profile, the possible benefits are generally believed to justify administration (15).

Penicillin

Penicillin G may have a time- and dose-dependent protective effect by either displacing α -amanitin from albumin, blocking its uptake from hepatocytes, binding to RNA polymerase (14).

Penicillin in doses ranging from 300000 to 1000000units/kg/day is thought to inhibit amatoxin up take by hepatocytes (17).

High-dose penicillin was found protective in retrospective animal and human studies. It should be used with caution due to the rare risk of anaphylaxis (18).

Silymarin

In Iran, it is available in form of liver Gol tablet. Silymarin is the most frequently used complementary and alternative medicine for liver disease in the United States (19).

It is proposed to be hepato protective by promoting hepatocyte growth, and inhibiting hepatic oxidation and inflammation (19).

One large retrospective study involving 2108 patients poisoned with amatoxin-containing mushrooms concluded that silybin monotherapy was an effective treatment modality (20).

Clinical trial amounts of silymarin range 420-480 mg per day (21).

Cimetidine

Cimetidine has been advocated for the treatment of amatoxin-containing mushrooms. The rationale for the use of cimetidine was the similarity in clinical course and history (centrilobular necrosis) of amanita poisoning with acetaminophen (APAP) hepatotoxicity (22).

Relative to historical controls, there was a decrease in mortality (not statistically significant) and a more rapid return to

normal transaminase levels, implying a decrease in ongoing hepatocellular injury in human studies (23).

No prospective trials however, have evaluated the use of cimetidine (2).

Hemodialysis

Hemodialysis has never been proven beneficial in case of amanita poisoning. For example, no amatoxin clearance was demonstrated 23 h post ingestion of *Amanita phalloides* in 2 patients (24).

Plasmapheresis may be of some benefit (25).

However liver transplant may eventually be necessary in the setting of severe hepatotoxicity, encephalopathy, and hemodynamic compromise. If mushrooms can be presumptively identified as containing am toxin, then the information can be used to justify early aggressive patient outcome and mortality, which may have helped in the successful outcome of our patient.

5. Conclusion:

We report the successful treatment of a mushroom poisoned patient in Kerman (which according to clinical course and laboratory finding, suggested that must be amatoxin-containing mushroom) with NAC, high-dose penicillin, MDAC, liver Gol.

Finally, this is the first time Amanita-containing mushrooms poisoning in Kerman.

References

1. Michael W. Shannon, Stephen W. Borron, Michael J. Burns, Haddad and Winchester's clinical management of poisoning and drug over dose; 4th ed: saunders, an imprint of Elsevier inc. 2007;455-61.
2. Ward J, Kapadia K, Brush E, Steven D. Salhanick MD. Amatoxin Poisoning: Case Reports and review of current therapies. the Journal of Emergency Medicine. 2012;1:1-6.
3. Trestrail H. Mushroom poisoning in the united states—an analysis of 1989 united states poison center data. Clin Toxicol. 1991;29:459-465.

4. Magdalane J, Ostrowska A, Podhorska M. Early morphological and functional alterations in canine hepatocytes. *Arch toxicol.* 2009;83:55-60.
5. Pajoumand A, Shadnia S, Efricheh H, Mmandegary A, Hassanianmoghadam H, Abdollahi M. A retrospective study of mushroom poisoning in Iran. *Hum exp toxicol.* 2005;24(12):609-13.
6. Amini M, Ahmadabadi A, Kazemifar AM, Solhi H, Jand Y, Phalloides A. intoxication Mis diagnosed as acute appendicitis: a case report, *Iranian Journal of Toxicology.* 2011;5(14):527-530.
7. Varshochi M, Naghili B. Mushroom poisoning in northwest of Iran. *Iranian Journal of Clinical Infections Disease.* 2007;2(4):164-175.
8. Ghodsi K. A 26 years old soldier with hepatic failure due to mushroom poisoning, *Shiraz E-Medical Journal.* 2002;3(2):37-44.
9. Keith L, Robert G, Hendrickson B, Zane k. *Amanita phalloides* poisoning. *Clinical Toxicology.* 2011;49:128-129.
10. Hall IR, Stevenson SL, Buchanan PK, Yun W, Cole ALJ. *Collecting wild mushrooms. In Edible and poisonous mushrooms of the world.* Cambridge. UK. Timber Press. 2003;43-118.
11. Burd A, Siggt, Fischbein C. *Amanita Virosa* poisoning: agent of terrorists or criminal activity? *Vet Hum Toxicol.* 2003;45:226.
12. Spoke DG, Rumack BH. *Handbook of mushroom poisoning: diagnosis and Treatment.* Boca, FL, CRC Press. 1994.
13. Benjamin Dr. *mushrooms: poisons and panaceas.* New York, WH Freeman, 1995
14. Piotrow S, Gomulkiewicz I, Sozanski A, Szelag T, Dzigiel P. Influence of commonly used clinical antidotes on antioxidant systems in human hepatocyte culture intoxicated with alph-amanitin. *Hum EXP Toxicol.* 2011;30:38-43.
15. Montanini S, Sinardi D, Pratico C. Use of acetyl cysteine as the life-saving antidote in *Amanita phalloides* (death cap) poisoning. *Arzneimittel for schung.* 1999;99:1044-1047.
16. Robert S, Hoffman S, Howland M, Neal A, Lewis R. Gold F. *Gold frank's manual of toxicologic emergencies 8thed: mc Graw- Hill companies.* 2007;876.
17. Floersheim GL. Experimental basis for the therapy of *Amanita phalloides* poisoning [german]. *Schweiz med Wochen Schr.* 1978;108:185-97.
18. Lestschert K, Faul stich H, Keller D. Molecular characterization and inhibition of amanitin uptake human hepatocytes. *Toxicol Sci.* 2006; 91:140-90.
19. National center for complementary and alternative medicine milk thistle. Available at:<http://nccam.nih.gov/health/milkthistle/atagance.htm>. Accessed February 14 2011.
20. Enjalbert F, Rapior S, Nouquier-soule J, Gaillon S, Amouroax N, Cabot C. Treatment of amatoxin poisoning : 20 years retrospective analysis. *J Toxicol* 2002;20:715-57.
21. Gordon A, Hobb A. Bowden DS. Effects of silybum marianum on serum hepatitis C virus RND alanine aminotrans ferase levels and well-being in patients with chronic hepatitis C. *J Gastro Enterol Hepatol.* 2006;21:275-80
22. Schneider SM, Borochovit D. Hepato toxicity in mice: a potential model for the treatment of *Amanita phalloides* poisoning. *ANN Emerg med.* 1987;16:1136-40.
23. Salhanick SD, Wax PM, Schneider SM. In response to tong TC. comparative treatment of alpha-amanitin poisoning. With N-Acetylcesteine, benzyl penicillin, cimetidine, thiotic acid, and silybin in a murine model. *ANN Emerg Med.* 2008; 52:184-5.
24. Mullins M, Horowitz B. The futility of hemo perfusion and hemodialysis in *Amanita phalloides* poisoning. *Vet Hum Toxicol.* 2000; 42:40-1.
25. Jander S, Bischoff J, Woodcock BG. Plasmapheresis in the treatment of *Amanita phalloides* poisoning: []: areview and recommend dations. *The Apher.* 2000;4:308-12.