

Metopic Suture – Incidence and Morphology in South Indian Human Adult Skulls

Santhosh CS^{1*}, Vishwanathan KG¹, Gupta A¹, Siddesh RC¹

¹ Department of Forensic Medicine, JJM, Medical College, Davangere-4, India

ARTICLE INFO

Article Type:
Original Article

Article History:
Received: 16 Aug 2013
Revised: 26 Nov 2013
Accepted: 10 Dec 2013

Keywords:
Frontal Bone
Metopic Suture
Metopism
Skull

ABSTRACT

Background: In the present study, the objectives were to determine the incidence of persistence of metopic sutures, their shape and extent in south Indian human adult skulls.

Methods: The study was conducted on 100 human adult dry skulls which belong to the museum of the department of Forensic medicine & toxicology and the department of Anatomy, JJM Medical College, Davangere, Karnataka. The metopic sutures were classified as complete and incomplete types. The incomplete was divided into linear, 'V' shaped and 'U' shaped, which were further divided into three groups as present in the lower part of the frontal bone, in the upper part, and in the middle part.

Results: From our observations, the metopic suture was present in 13 (13%) cases. The complete metopic suture was seen in 6 skulls (6%) and incomplete one in 7 (7%). Among the incomplete ones, linear was found in 5 (5%), 'V' shaped in 1 (1%) and 'U' shaped type in 1 (1%) cases. In 7 (7%), cases it was observed in the lower part of frontal bone, but no suture remnant was found in the upper and lower part of frontal bone.

Conclusion: Due to the paucity in the availability of the skulls, a lesser number of sample size was taken in our study. But a good analysis can be done with a larger sample size, to give a constructive data.

Copyright©2014 Forensic Medicine and Toxicology Department. All rights reserved.

► *Implication for health policy/practice/research/medical education:* Metopic Suture – Incidence and Morphology in South Indian Human Adult Skulls

► *Please cite this paper as:* Santhosh CS, Vishwanathan KG, Gupta A, Siddesh RC. *Metopic Suture – Incidence and Morphology in South Indian Human Adult Skulls. International Journal of Medical Toxicology and Forensic Medicine.* 2014; 4(1): 6-10.

1. Introduction:

Metopic suture is a suture between the two halves of the frontal bone, in the midline, from the anterior aspect of the anterior fontanelle to the nasion (1). Metopic suture

normally starts to close in the second year of life and is usually completely obliterated within short duration of time. In some skulls, there may be a partial or complete failure of this obliteration. When the metopic suture persists as a complete suture extending from the nasion to the anterior angle of the bregma, this condition is known as metopism (2). If the suture is not present throughout and occupies a

Corresponding author: Santhosh CS, Assistant Professor, Department of Forensic Medicine, JJM, Medical College, Davangere-4, India
E-mail: drsan_99@rediffmail.com

small area between these two points, they are considered as incomplete metopic sutures (3).

The obliteration of metopic suture is highly controversial and studied by various researchers. According to Romaneset *et al* (4) the metopic suture closes by the fifth or sixth year. Piersol *et al* (5) concluded that the metopic suture disappears by the end of the fourth year, leaving a faint trace at the lower end but Keith *et al* (6) mentions that the metopic suture disappears at the end of the first year, or in the beginning of the second year of life. Warwick & Williams (7) observed that metopic suture is usually obliterated by the eighth year.

According to Del Soletal (8), metopism can be due to abnormal growth of cranial

atavism, hydrocephalus, sexual influence, stenocrotaphia, plagiocephaly, scaphocephaly, mechanical causes and hormonal dysfunction.

It is essential to know about metopic suture failing which it can be easily misunderstood as fracture of frontal bone or even for the sagittal suture in radiological images (8, 9). It is also important for paleodemography and forensic medicine (10). In the present study, the objectives were to determine the incidence of metopic sutures and their extent and shape in south Indian human adult skulls.

2. Materials and Methods:

This study was conducted on 100 dry

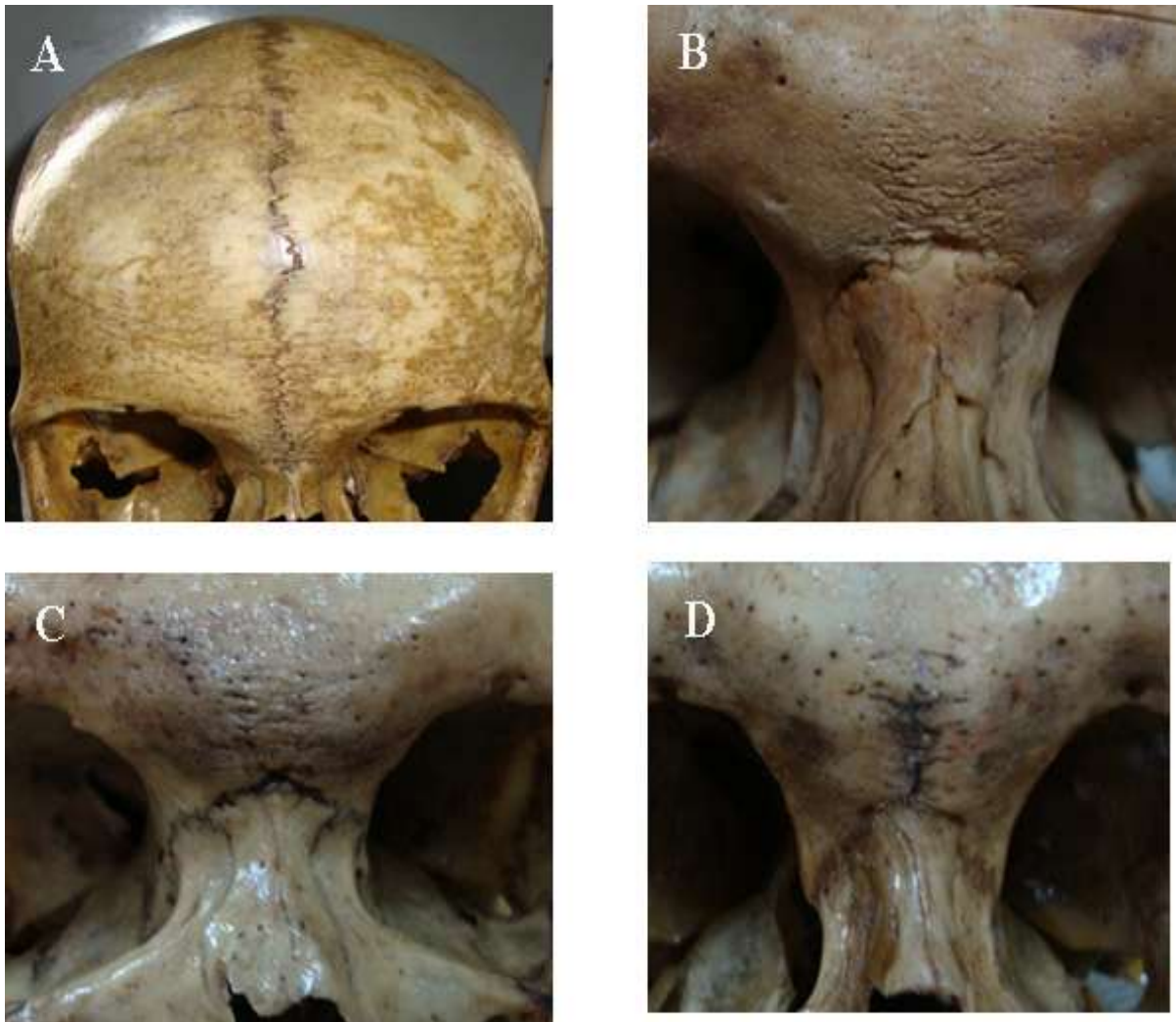


Fig. 1. A. Complete metopic suture; B. 'U' shaped metopic suture; C. 'V' shaped metopic suture; D. Incomplete metopic suture in lower part of frontal bone.

bones, growth retardation, heredity,

Table 1: Incidence of metopic suture and metopism sex wise in the present study.

Sex	Metopic suture (%)	Metopism (%)
Male (63%)	5	2
Female (37%)	8	4

Table 2: Incidence of the metopic suture in the present study.

Type of suture	Number	Percentage (%)
Complete metopic suture (metopism)	6	6
Incomplete	7	7

south Indian human skulls in the museum of the department of Forensic medicine and toxicology and the department of Anatomy, JJM Medical College, Davangere, Karnataka. The skulls with signs of diseases, visible abnormalities and damaged skulls were excluded from the study. The skulls were macroscopically inspected for the presence of the metopic suture and these skulls were divided into three groups as normal skulls without any metopic suture, complete metopic suture and with incomplete metopic suture. A suture which is found completely between the bregma and nasion is termed as the complete metopic suture or metopism. If it extends to a smaller distance either from the bregma or from the nasion, it is termed as incomplete type. The incomplete metopic suture was divided into linear, 'V' shaped and 'U' shaped types. Incomplete metopic suture was further divided into three groups as present in the lower part of the frontal bone, in the upper part, and in the middle part. The incidences of complete and incomplete metopic suture were calculated and the data obtained were compared with those from earlier studies.

3. Results:

In our study sixty three (63%) of the skulls were of male sex and thirty seven (37%) of female sex (Table 1). Eighty seven (87%) of the skulls had neither complete nor incomplete metopic suture. Metopic suture either in the form of complete or incomplete was found to be present in thirteen skulls (13%). Complete metopic suture (metopism) was found in six skulls (6%), and incomplete suture was observed in seven (7%) skulls (Table 2). Three different types of incomplete metopic

sutures namely linear, 'U' shaped, 'V' shaped, were identified. Linear incomplete metopic suture was found in five (5%) skulls, 'U' shaped in one (1%) skull and 'V' shaped in one (1%) skull (Table 3). Incomplete metopic suture was observed in the lower part of frontal bone in seven (7%) skulls, but no suture remnant was found in the upper and lower part of frontal bone (Table 3). Metopic suture either in the form of complete or incomplete was found in five (5%) of the male skulls and eight (8%) of the female skulls, whereas metopism was found in four (4%) female skulls and in two (2%) male skulls (Table 1).

4. Discussion:

Bryce *et al* (11) reported metopism is present in 5.1 % of Mongolian skulls, 8.7 % of European skulls, 9.5 % of Scottish skulls, 1.2 % of Negroes and 1% of Australian skulls. The incidence of metopism is about 10% in Whites and Mongoloids and only 2 % in Negroids. According to Breathnach¹² the incidence of metopic suture varies from 4-5 % in Yellow races, 7-10% in Europeans, and 1% in African skulls. Romanes *et al* (4) reported incidence of metopism in Europeans is up to 8%. M.L. Ajmani *et al* (9) observed the incidence of 3.40% metopism in Nigerians.

Among Indian skulls Das *et al* (13) reported the incidence of metopic suture as 24.67% and metopism as 3.31 %. Agarwal *et al* (14) reported metopic suture in 38.17% and metopism in 2.66%. Fakhruddin and Bhalerao (15) observed metopism in 2%. Dixit and Shukla (16)

Table 3: Incidence of the metopic suture in the present study.

Types of Incomplete metopic suture	Number	Percentage (%)
Linear	5	5
'U' Shaped	1	1
'V' Shaped	1	1
In lower part of frontal bone	7	7
In upper part of frontal bone	0	0
In middle part of frontal bone	0	0

reported the incidence of metopism in 2.53% in skulls from Uttar Pradesh. Shanta Chandrasekaran (17) observed metopism in 5%. Inderjit and Shah (18) reported metopic suture in 32.5% and metopism in 5% in Punjabi skulls. Yadav *et al* (19) reported metopic suture in 18.04% and metopism in 3.5% in north Indian skulls. Chakravarthy and Venumadhav (20) observed metopic suture in 45% and metopism in 6.25% in south Indian adult skulls.

In the present study, the incidence of metopism was found to be 6% which is similar to the study reported by Inderjit and Shah (18) in Punjabi skulls (5%), Shanta Chandrasekaran (17) in South Indian skulls (5%) and Bryce *et al* (11) in Mongolian skulls (5.10%) and Chakravarthy & Venumadhav²⁰ in south Indian skulls (6.25%), but lesser than the incidence reported by Yadav *et al* (19) in north Indian skulls (14.6%).

In the present study, the incidence of incomplete metopic suture was found to be 7% which is similar to the study conducted by Yadav *et al* (19) (14.6%) and Das *et al* (13) (17.57%). But is in contrast to the study conducted by M.L. Ajmani *et al* (9) (31.57%), Agarwal *et al* (14) (35.51%), Chakravarthy and Venumadhav (20) (38.75%) and Shanta Chandrasekaran (17) (40%). In our study we found linear incomplete metopic suture in 5% of the skulls, 'U' shaped and 'V' shaped in 1% cases each which is similar to the study conducted by Das *et al* (13), but is in contrast to the study conducted by M. L. Ajmani *et al* (9), Agarwal *et al* (14), Shanta Chandrasekaran (17), Inderjit and

Shah (18) and Chakravarthy and Venumadhav (20).

Incomplete metopic suture was observed in the lower part of frontal bone in 7 cases (7%), whereas none of the incomplete metopic suture was observed in the upper and middle part of frontal bone. Further, the incidence of incomplete metopic suture in the lower part of frontal bone was found higher as compared to the upper and middle part, which is in agreement with previous studies by Agarwal *et al* (14) reported metopic suture in lower part in 35.27% skulls, while in upper and middle parts in 0.8% cases each, Das *et al* (13) reported metopic suture in lower part in 20.96% skulls, in upper part in 0.28% and none in middle part, and Yadav *et al* (19) reported metopic suture in lower part in 14.02% skulls, in upper part in 0.39% and in middle parts in 0.19% cases. In our study, the incidence of metopism was slightly higher in the female population.

5. Conclusion:

The present study has shown the incidence of metopic suture in south Indian adult skulls as 13% and of metopism as 6%. The most common incomplete metopic suture was linear type which was 5% and located most commonly in the lower part of the frontal bone. On comparing with the results of earlier research worker in India, the incidence of metopism was found higher in skulls from south India. Persistence of Metopic suture is a useful guide in the identification of a person. Sometimes it may be easily misdiagnosed as fracture of frontal bone or even sagittal suture in radiological images. It is important for forensic experts,

neurosurgeons, orthopedic surgeons, oromaxillofacial surgeons, ophthalmologists, ENT surgeons and others to know about metopism.

Due to the paucity in the availability of the skulls, a lesser number of sample size was taken in our study. But a good analysis can be done with a larger sample size, to give a constructive data.

References

1. Weinzweig J, Kirschner RE, Farley A, Reiss P, Hunter J, Whitaker LA. Metopic synostosis: Defining the temporal sequence of normal suture fusion and differentiating it from synostosis on the basis of computed tomography images. *Plast Reconstr Surg.* 2003;112:1211–1218.
2. Jones FW, Buchanan's Manual of Anatomy, 7th ed. Bailliere, Tindall and Cox, London.1946;7(6):226-229.
3. Bademci G, Kendi T, Agalar F. Persistent metopic suture can mimic the skull fractures in the emergency setting? *Neurocirugia.* 2007;18:238-240.
4. Romanes GJ. Cunningham's Textbook of Anatomy, 11th ed. London: Oxford University Press.1972. p 133.
5. Piersol GA. Human Anatomy, 5th ed. Philadelphia: Lippincott. 1916.
6. Keith A. Human Embryology and Morphology, 6th ed. London: Edward Arnold, 1948.
7. Warwick R, Williams PL. Gray's Anatomy, 36th ed., London: Longmans. 1980. p. 334.
8. Del Sol M, Binignat O, Bolini PDA, Prates JC. Metopismo no individuo brasileiro. *Rev. Paul. Med.* 1989; 107(2):105-7.
9. Ajmani ML, Mittal RK, Jain SP. Incidence of the metopic suture in adult Nigerian Skulls *J Anat.* 1983;137(1):177-83.
10. Hauser G, Mnazi G, Vienna A & De Stefano G F. Size and shape of human cranial sutures – a new scoring method. *Am. J. Anat.* 1991;190:231-44.
11. Bryce TH. Osteology and Arthrology. In Quain's Elements of Anatomy. 1915;4(11):177-180.
12. Breathnach AS. Frazer's Anatomy of the Human Skeleton, 6th ed. London: Churchill 1958.p 178.
13. Das AC, Saxena RC, Beg M. Incidence of metopic suture in U.P. subjects. *Journal of the Anatomical Society of India.* 1973. 22:140.
14. Agarwal SK, Malhotra VK, Tewari SP. Incidence of the metopic suture in adult Indian crania. *Acta anatomica.* 1979;105: 469-474.
15. Fakhruddin S, Bhalerao UK. Interparietal Bone in Three pieces- A case report. *J. Ant. Soc. India.*1967;16:146-147.
16. Dixit CS, Shukla PL. Metopic suture in Human Crania. *J. Anat. Soc. India.* 1968;17:47.
17. Shanta Chandrasekaran, Deepti Shastri. A Study on Metopic Suture. *International Journal of Basic Medical Science.* 2011;1:379-382.
18. Shah MA. Incidence of frontal or metopic suture amongst Punjabi adults. *Indian Medical Gazette.* 1948;83:507.
19. Yadav A, Kumar V, Srivastava RK. Study of Metopic suture in the adult human skulls of north India, *J. Anat. Soc. India.* 2010;59(2) 232-236.
20. Chakravarthi KK, Venumadhav N. Morphological study of Metopic suture in adult South Indian skulls, *Int J Med Health Sci.* 2012;1(2):7-12.