

## Cause of Murder or Normal Variation, Which One is True?

Teimoory M<sup>1\*</sup>, Ghadipasha M<sup>2</sup>, Memarian A<sup>1</sup>, Bastani B<sup>3</sup>

<sup>1</sup> Department of Forensic Medicine and Toxicology. Tehran University of Medical Sciences, Tehran, Iran

<sup>2</sup> Legal Medicine Research Center, Legal Medicine Organization, Tehran, Iran

<sup>3</sup> Department of Forensic Medicine and Toxicology, Shahid Beheshti University of Medical Sciences, Tehran, Iran

---

### ARTICLE INFO

*Article Type:*  
Case Report

---

*Article History:*

Received: 9 April 2013

Revised: 28 April 2013

Accepted: 21 May 2013

---

*Keywords:*

Parietal Foramen

Normal variation

Murder

---

### ABSTRACT

**Background:** Parietal hole is formed as a result of defect or delay in the ossifying one third of the posterior parietal in the fifth month of fetal in genetic transfer of mutated gene dominant autosomal genetic. Artery, vein, meningia or brain cortex is exited through it, as for as the equal with its size. Parietal foramen is located in syndromic frame.

**Case Presentation:** The case is Iranian 34 years old woman, that was found in dead state in the motel. The positive findings in examination:

- Abrasion in skin of left upper posterior area of parietal.
- Scars of cosmetic surgery and numerous tattoos.
- Purple bruises in the arms.

The positive findings in necropsy:

- A hematoma under the right and posterior site of parietal skin in 2×2 cm, under parietal skin abrasion.
- A hole that it was in the posterior of right parietal bone, 1 mm in diameter, near the sagittal suture. It was extended to the inner surface of skull.
- Very mild desquamation in dura mater with very mild bleeding about 2 cc above arachnoid (under dural desquamation).
- A hematoma with 1×1 cm, between the cervical muscles
- A 3×3 cm hematoma under the skin of upper and anterior of chest wall.

The serologic, Toxicologic and pathologic sample were negative.

**Conclusion:** As for as wearing in the left posterior parietal and hematoma under the skin in this area and finding a holes in mentioned area, at first, it seemed that the lesion is created by a sharp object, hard edges or shot. But in closer examinations there was no rupture on scalp and edge of the hole was perfectly sharp and smooth. Hence in order to prevent confusion in similar cases, the physician is familiar with these variations.

---

Copyright©2013 Forensic Medicine and Toxicology Department. All rights reserved.

---

► *Implication for health policy/practice/research/medical education:*

Cause of Murder or Normal Variation, Which One is True?

---

► Please cite this paper as: Teimoory M, Ghadipasha M, Memarian A, Bastani B. Cause of Murder or Normal Variation, Which One is True. *International Journal of Medical Toxicology and Forensic Medicine*. 2013; 3(3): 103-105.

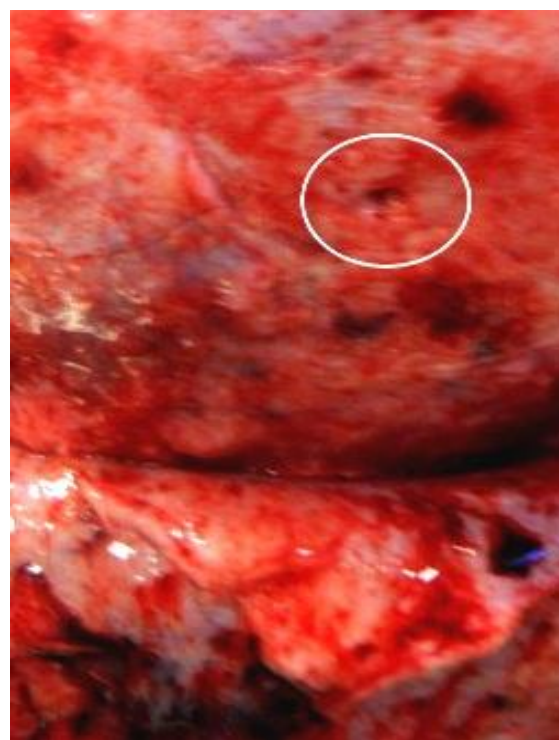
### 1. Introduction:

Parietal hole is formed as a result of defect or delay in the ossifying one third of the posterior parietal in the fifth month of fetal in genetic transfer of mutated gene dominant autosomal genetic (2, 3). It has different dimensions and artery, vein, meninges or brain cortex is exited through it, as far as the equal with its size (1.3). Parietal foramen is located in syndromic frame. It could contain the following types: Clavicle hypoplasia, several exostosis, normal intelligence, dysmorphia in face-as long forehead and long palate and dental disorders and eyelid narrowed gap and bowed down and broad and short thumbs (2).

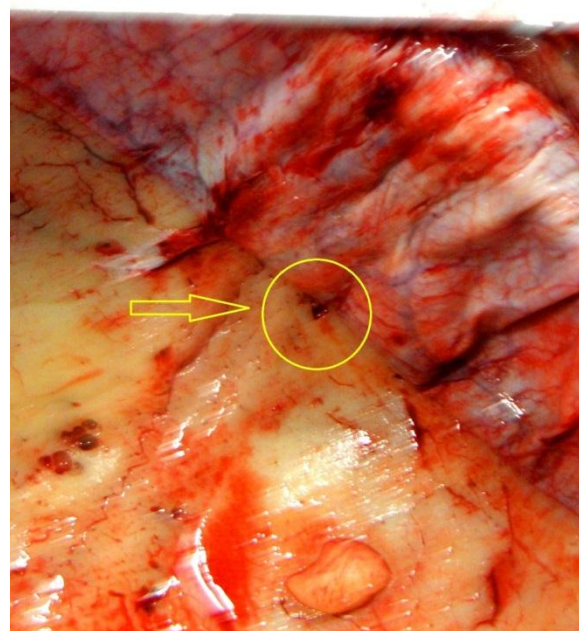
### 2. Case presentation:

The case is Iranian 34 years old woman with height 165 cm, weight 65 kg, home dressed that was found in dead state in the motel. In a survey conducted, the autopsy in anatomy dissection at the first 12 hours after death, when examining, lividity in the lower surface of body and general rigor mortis were found. There was no positive finding in physical examination of the head and face, mouth, nose, conjunctiva, around the mouth and eyelids. After shaving the hair, abrasion in skin of left upper posterior area of parietal was seen. There was no positive point in neck such as: fracture, bruises, dislocation and.... Multiple scars of old cosmetic surgery was seen on breast, abdomen and numerous tattoos on suprapubic and left arm, in the shape of moon and star, cross and heart. Hymen was in female mood with no recent trauma in the genital and anal area. Purple bruises were observed in the arms. There

*Corresponding author:* Teimoory M, MD. Department of Forensic Medicine and Toxicology. Tehran University of Medical Sciences, Tehran, Iran. E-mail: maryamteimoory87@yahoo.com



**Fig. 1.** Parietal Foramen(external view)



**Fig. 2.** Parietal Foramen(inner view).

was no unusual finding in upper and lower extremities. The body got under necropsy

after physical examination and its positive aspects are as follows in summary:

1- A fresh and circular shape hematoma under the right and posterior site of parietal skin in 2×2 cm size that it was under superficial parietal skin abrasion (pic 1).

2- A hole that it was in the posterior of right parietal bone, 1 mm in diameter, near the sagittal suture (pic 1). It was extended to the inner surface of skull (pic 2). After removing cranial vault, very mild desquamation in dura mater surface with very mild bleeding about 2 cc above arachnoid (under dural desquamation) was seen. There were no unusual findings such as fracture, contusion, sub arachnoid hemorrhage and... in brain tissue and skull.

3- A hematoma with 1×1 cm size, between the cervical muscles, anterior muscles of larynx and left muscles of hyoid bone without any fracture, dislocation of cartilages and bone in cervical area.

4- A 3×3 cm hematoma under the skin of upper and anterior of chest wall, on the upper part of sternum and chest wall muscles.

There was no positive point in serologic samples of anus, vagina and toxicological and pathological sample in this autopsy.

### 3. Discussion:

As for as wearing in the left posterior parietal and hematoma under the skin in this area and finding a holes in mentioned area, at first, it seemed that the lesion is

created because of the hit by a sharp object or hard edges or shot. But in a closer examinations by authors in the scalp, it was determined that no rupture is on scalp, also edge of the hole in parietal area are perfectly sharp and smooth. So thorough exact and close examination, we can reject any possible differential diagnoses. Now, if instead of scalp surface wear, exactly matches the hole in the skull, there was rupture in above mentioned area, by a less experienced physician examination of the body, in determining the cause of death could create many problems and to mislead the judge. Hence in order to prevent confusion in similar cases, the body examination physician is familiar with these variations.

### References

1. Mann R, Manabe J. Relationship of the parietal foramen and complexity of the human sagittal suture. *Int J. Morphol.* 2009;27(2):553-564.
2. Maroginnis L, Taylor I, Davies S. Enlarged parietal foramina caused by mutations in the homeobox genes ALX4 and MSX2: from genotype to phenotype. *Eur J Hum Genet.* 2006;14(2):151-158.
3. Valente M, Valente K. Malformation of cortical and vascular development in one family with parietal foramina determined by an ALX4 homeobox mutation. *AJNR.* 2004;25:1836-1839.
4. Sing P, Raibagkar C. Study of variation in typical foramina of dry human skull .*NJIRM.* 2011;2(2):1-5.