



Electrocardiography in Post-heart Transplant

Neda Toofaninejad^{1,*}, 

¹ Department of Cardiology, Qom University of Medical Sciences, Qom, Iran

*Corresponding author: Neda Toofaninejad. Department of Cardiology, Qom University of Medical Sciences, Qom, Iran. Tel: +98-2536122000, E-mail: toofanind@yahoo.com

DOI: 10.21859/ijcp-405

Submitted: 14-10-2018

Accepted: 30-10-2018

Keywords:

Electrocardiography
Transplant
Heart

Abstract

The current study described the electrocardiography case of a 22-year-old male, a few months after heart transplantation that demonstrated two sets of QRS leading to understand the technique of the transplantation.

© 2018. International Journal of Cardiovascular Practice.

INTRODUCTION

Since the inception of the heart many centers performed cardiac transplantation worldwide. Regular follow-up appointments and tests, including echocardiograms, electrocardiograms and heart biopsies are indicated in recipient [1]. The electrocardiogram (ECG) of heart transplant recipients is well documented. This paper described the ECG of a 22-year-old man, a few months after heart transplantation.

CASE PRESENTATION

A 22-year-old male referred to Cardiology Clinic for medical checkup. He previously underwent a heart transplant eight months before referring to the clinic due to end-stage idiopathic dilated cardiomyopathy. Physical examination demonstrated a regular pulse of about 115 bpm and blood pressure of 110/70 mmHg. [Figure 1](#) shows the 12-lead electrocardiography (ECG) and long-lead.

The ECG showed two sets of QRS complexes with different shapes; a narrow one with a rate of 115 beats/minute, which originated from the donor heart and the wider QRS rhythm complexes with a slower rate, and different axis in right precordial leads that originated from the native heart. Both types of QRSs proceeded a P wave. Fusion beats of both hearts was observed in the long-lead. Actually, it was a superimposed rhythm of the native and donor hearts after heterotrophic heart transplantation.

DISCUSSION

The first human heart transplant was performed by Christiaan Barnard in 1967. There are two surgical procedures for heart transplantation, orthotopic heart

transplantation (OHT) and heterotopic heart transplantation (HHT) [1].

OHT is the more common and standard technique in which the native heart is replaced with the donor heart. Due to retained posterior wall of the recipient right atrium including the native sinoatrial node, two sets of P waves with different rate may be detected on surface ECG, but only the donor heart P waves can conduct to the ventricles (dual sinus nodes). However, in some cases, due to small amplitude of the P wave of the recipient atrial remnants, only one P wave can be observed. In HHT, which is less commonly employed, the native heart is left in place and the donor heart is positioned beside the recipient heart, usually in right side of the chest, and the surface ECG shows superimposed rhythms of the native and donor hearts as in the currently presented case. Separation of the two hearts in their rhythm may cause double rhythm in double heart. Potenza et al. reported ventricular fibrillation of the native heart and sinus rhythm of the donor heart in a patient with heterotopic transplantation [2].

HHT was a more useful technique before improvement in immunosuppression regimes and mechanical circulatory support, as it helped to maintain circulation in the cases of acute graft failure [3]. Now it is rarely used and limited to selected patients including cases with irreversible pulmonary hypertension and patients with marked donor-recipient-size mismatch [3-5]. Disadvantages of this technique include prolonged duration and complexity of operation, atelectasis due to compression of the lower lobe of right lung by the donor's heart, increased rate of thromboembolism, recurrence of angina, arrhythmia, difficulty in endomyocardial biopsies, and endocarditis [4, 5].

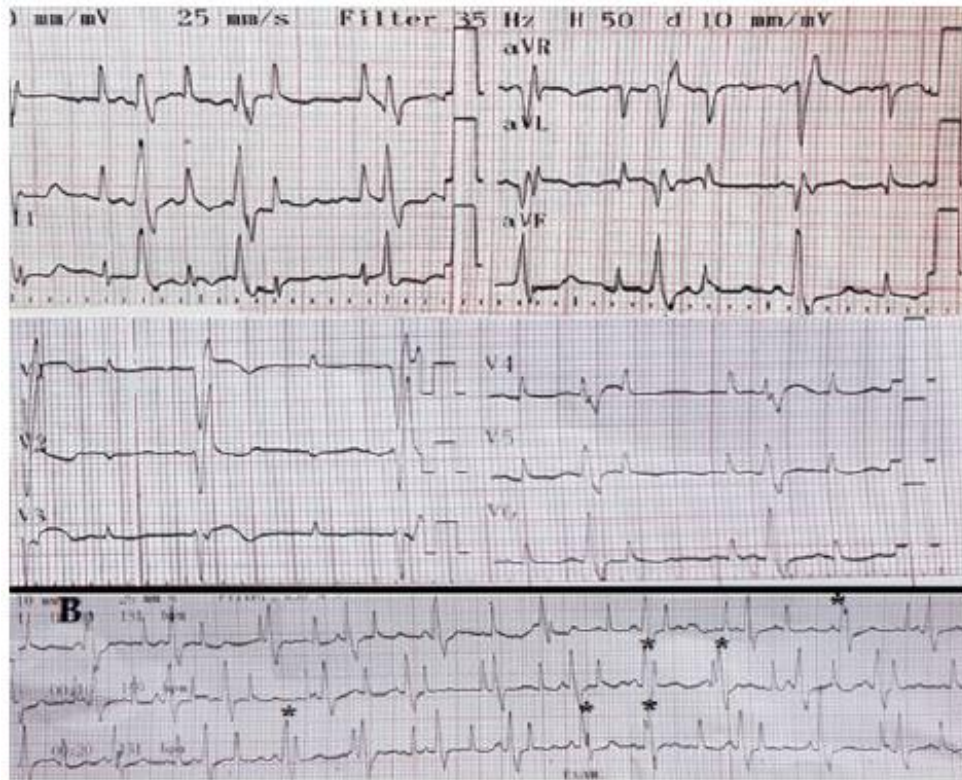


Figure 1. A, Standard 12-lead Electrocardiography, Narrow QRS Originated from the Donor Heart and the Wider QRS Originated from the Native Heart. B, long-lead II, Fusion Beats of Both Hearts can be Observed in the Long-lead (*).

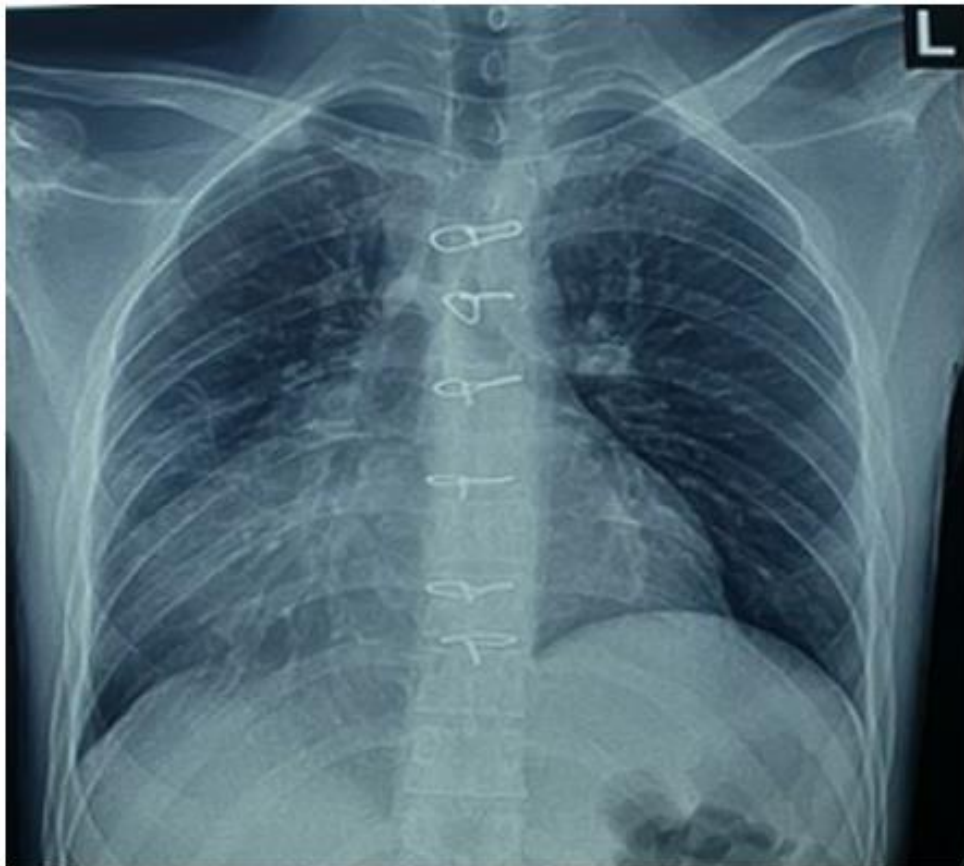

Figure2. The Chest X-Ray also confirmed Coexistence of Donor and Recipient Heart QRS sets in the Patient

Conflicts of Interest

The author report no financial relationships or conflicts of interest.

REFERENCES

1. Newcomb AE, Esmore DS, Rosenfeldt FL, Richardson M, Marasco SF. Heterotopic heart transplantation: an expanding role in the twenty-first century? *Ann Thorac Surg.* 2004;78(4):1345-50; discussion 50-1. doi: [10.1016/j.athoracsur.2004.03.071](https://doi.org/10.1016/j.athoracsur.2004.03.071) pmid: [15464497](https://pubmed.ncbi.nlm.nih.gov/15464497/)
2. Potenza D, Vigna C, Massaro R, Russo A, Amico C, Cianfrone N, et al. Double rhythm in double heart. *J Cardiovasc Med (Hagerstown).* 2008;9(6):625-7. doi: [10.2459/JCM.0b013e3282f25e9f](https://doi.org/10.2459/JCM.0b013e3282f25e9f) pmid: [18475133](https://pubmed.ncbi.nlm.nih.gov/18475133/)
3. Nakatani T, Frazier OH, Lammermeier DE, Macris MP, Radovancevic B. Heterotopic heart transplantation: a reliable option for a select group of high-risk patients. *J Heart Transplant.* 1989;8(1):40-7. pmid: [2647930](https://pubmed.ncbi.nlm.nih.gov/2647930/)
4. Flecher E, Fouquet O, Ruggieri VG, Chabanne C, Lelong B, Leguerrier A. Heterotopic heart transplantation: where do we stand? *Eur J Cardiothorac Surg.* 2013;44(2):201-6. doi: [10.1093/ejcts/ezt136](https://doi.org/10.1093/ejcts/ezt136) pmid: [23487534](https://pubmed.ncbi.nlm.nih.gov/23487534/)
5. Kadner A, Chen RH, Adams DH. Heterotopic heart transplantation: experimental development and clinical experience. *Eur J Cardiothorac Surg.* 2000;17(4):474-81. pmid: [10773573](https://pubmed.ncbi.nlm.nih.gov/10773573/)