

## Case Report

# Imported Malaria in an Iraqi Immigrant to Iran: Relevance for the Maintenance of Elimination Status

Zahra Arab-Mazar<sup>1</sup>, Sara Rahmati Roodsari<sup>2</sup>, Zahra Mirabedyni<sup>1</sup>, Leila Haghighi<sup>3,4</sup>, Mohsen Rahimi<sup>5,6,7\*</sup>

<sup>1</sup> Department of Medical Parasitology and Mycology, School of Public Health, Tehran University of Medical Sciences, Tehran, Iran

<sup>2</sup> Shahid Beheshti University of Medical Sciences, Tehran, Iran

<sup>3</sup> Department of Parasitology and Mycology, School of Medicine, Iran University of Medical Sciences, Tehran, Iran

<sup>4</sup> Department of Pathology, Baqiyatallah University of Medical Sciences, Baqiyatallah Hospital, Tehran, Iran

<sup>5</sup> Department of Parasitology and Mycology, School of Medicine, Shahid Beheshti University of Medical Sciences, Tehran, Iran

<sup>6</sup> Department of Parasitology and Mycology, School of Medicine, Student Research Committee, Shahid Beheshti University of Medical Sciences, Tehran, Iran

<sup>7</sup> Research Center for Prevention of Oral and Dental Diseases, Baqiyatallah University of Medical Sciences, Tehran, Iran

Received: 07 October, 2019; Accepted: 24 December, 2019

## Abstract

**Background:** Effective malaria control strategies require an accurate understanding of the epidemiology of locally transmitted *Plasmodium* species. Emerging evidence indicates that migrants from malaria endemic regions are at risk of delayed presentation of *Plasmodium* spp. and malaria infection.

**Cases Report:** We reported a case of *P. vivax* malaria occurring after arrival in Iran. Patient was originally from Iraq. A 48-year-old male patient who was hospitalized with fever attacks, chills, and headache after arriving from Iraq to Tehran.

**Conclusion:** In this patient, new prevention and screening strategies should be studied and blood safety policies adapted. Thus, ultimate elimination of malaria in Iran will require national malaria control program to adopt policy and practice aimed at all human species of malaria since neighbor country are still face to problem to control of malaria.

**Keywords:** Immigration, Imported malaria, *Plasmodium vivax*, Traveler

\*Corresponding Author: Mohsen Rahimi, Department of Parasitology and Mycology, School of Medicine, Shahid Beheshti University of Medical Sciences, Tehran, Iran. Postal code: 19857-17443. Tel/Fax: (+98) 21-22439962. Mobile phone number: (+98) 912-1036089. Email: Mohsen1rahimi@yahoo.com

Please cite this article as: Arab-Mazar Z, Rahmati Roodsari S, Mirabedyni Z, Haghighi L, Rahimi M. Imported Malaria in an Iraqi Immigrant to Iran: Relevance for the Maintenance of Elimination Status. Novel Biomed. 2020;8(2):98-100.

## Introduction

Malaria is one of the most important parasitic diseases and health issues in some countries, especially the tropical and subtropical countries of the world. Malaria's symptoms are usually include fever, fatigue, vomiting, and headache. In severe cases, it can cause symptoms such as skin rash, seizures, coma, or death. According to the world

health organization, about 207 million people have clinical symptoms of the blood parasite, of which 627,000 have died<sup>1-3</sup>. Results of studies in Iran showed that 89% of malaria infections are caused by *Plasmodium vivax* during 2008-2009. 10% *Falciparum* species and 10% had both infections. Due to the presence of malaria endemic areas in Iran such as southeastern provinces of Iran (Sistan and Baluchistan), south (Hormozgan) and northwest

(Ardabil), many efforts have recently been made to eradicate and control this disease. Although the incidence has declined, there are new reports of infection with this parasite<sup>4,5</sup>.

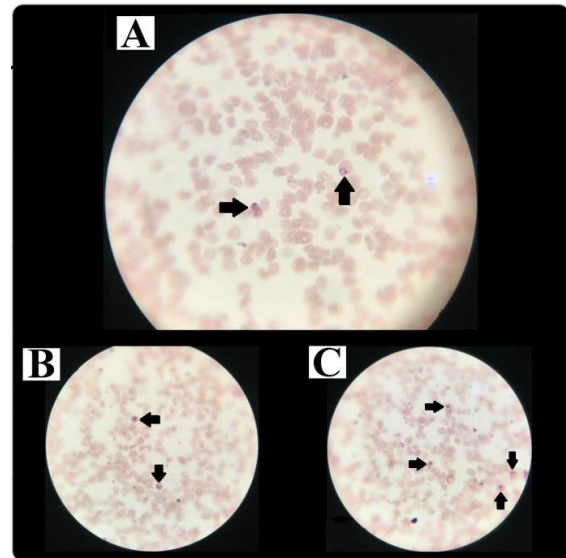
However, the purpose of this case report was to remind clinical symptoms, diagnostic methods, and treatment of patients. Laboratory monitoring and testing of passengers traveling from malaria-prone areas to the country is also underway.

## Case Report

A 48-year-old Iraqi male who had developed fever and chills for about three weeks and was severely weak and lethargic before being admitted to Loghman Hakim Hospital in Tehran. The patient also complained of nausea and abdominal pain (myalgia). The period of fever in the patient was repeated intermittently every three days and the duration of fever and chill lasted for three days.

The patient also had vomiting and decreased appetite. He had a history of similar symptoms in Iraq last year, where he had been receiving drug treatment. The patient's vital signs at the beginning of admission were as follows: diastolic blood pressure was 130 mm/Hg and systolic blood pressure was 80 mm/Hg. The heart rate was 96 times per minute. Patients had a fever of 39.5°C. Conjunctivitis and sclerosis were negative in other clinical examinations. Abnormal symptoms were not found in cardiac, lung, and abdominal examinations. Finally, the patient's blood and urine samples were collected for routine testing and sent to the hospital laboratory. The results were as follows: Hemoglobin 12.1 g/dL, WBC 6600/mm<sup>3</sup>, Platelets of blood from 28000 to 73000/mm<sup>3</sup>, Lactate dehydrogenase (LDH) 362 units per liter (U/L), Creatinine (Cr) 1.2 mg/dL, Urea 19 mg/dL, Prothrombin time (PT) 11.3 seconds, Partial thromboplastin time (PTT) 32 seconds, Erythrocyte sedimentation rate (ESR) was variable at an average of 40 mm/h.

Ultrasound images showed liver and spleen size of 165 and 105 mm, respectively. The result of the patient's thin blood smear test after staining with Wright's stain indicated a parasitic trophozoite inside the RBC with Schüffner's dots and large parasitic erythrocytes containing mature schizonts indicating *Plasmodium vivax* (Figure 1A-C).



**Figure 1. Microscopic images of *Plasmodium vivax* rings and amoeboid trophozoites (black arrows) in a thin blood smear (×100).**

Due to the serious condition, it was impossible to perform the pathologic procedures. Finally, the patient was treated with artesunate and doxycycline. After treatment, fever, nausea and numbness were resolved, and platelet count and WBC returned to normal, and the patient was discharged with normal vital signs.

## Discussion

The city of Najaf is located in Iraq. There are reports of malaria in Iraq every year, which has dropped dramatically in recent years<sup>1</sup>. Most cases of malaria have been reported from the northern Iraqi provinces<sup>2</sup>. Due to the high number of travelers in all seasons of the year and the climate change that causes the abundance of *Anopheles* mosquitoes high heat and reduced rainfall are among the causes of malaria eradication in Iraq<sup>3,4</sup>.

Most species of *plasmodium* reported in Iraq include *P. vivax*, which is the same in Iran.

In Iran, there are also a few cases of malaria reported annually, often as a single or imported malaria. Immigrant infected people cause a parasite cycle. Failure to see a physician and lack of hygiene can cause infection and prevent eradication of the disease<sup>5,6</sup>.

## Conclusion

In this patient, new prevention and screening strategies should be studied and blood safety policies adapted. Thus, ultimate elimination of malaria in Iran will require national malaria control program to adopt policy and practice aimed at all human species of malaria since neighbouring countries are still face to problem to control of malaria.

## References

1. World Health Organization World Malaria Report 2015, WHO, Geneva. 2016.
2. Saheb EJ. The prevalence of parasitic protozoan diseases in Iraq, 2016. *Karbala International Journal of Modern Science*. 2017;4(1):21-5.
3. Alwan A. Health in Iraq, the Current Situation, Our Vision for the Future and Areas of Work. 2004.
4. Mosa IS, Mahdi SG, Saheb EJ, Abdul-Karim MI, Nawar Khistawi A. An Epidemiology Study of Some Protozoan Parasitic Diseases in Iraq from 2011 Till 2015. *Journal of Al-Nahrain University*. 2017;20(3):115-20.
5. Nkuo-Akenji T, Ntonifor NN, Ndukum MB, Kimbi HK, Abongwa EL, Nkwescheu A, Anong DN, Songmbe M, Boyo MG, Ndamukong KN, Titanji VPK. Environmental factors affecting malaria parasite prevalence in rural Bolifamba, South-West Cameroon. *African Journal of Health Sciences*. 2006;13(1-2):40-6.
6. Youssefi MR, Rahimi MT. Prevalence of malaria infection in Sarbaz, Sistan and Bluchistan province. *Asian pacific journal of tropical biomedicine*. 2011;1(6):491-2.