

Case Report

Varicella Pneumonia: a Case Report in an Immunocompetent Patient

Mahshid Heidari¹, AmirHossein Moghtader Mojdehi², Sahar Babaali^{3*}

¹Department of Infectious Disease, Vali-e-Asr Hospital, Medical University of Zanjan, Zanjan, Iran

²Department of Infectious Disease, Vali-e-Asr Hospital, Zanjan, Iran

³General Practitioner, Medical University of Zanjan, Zanjan, Iran

Received: 06 July 2018 ; Accepted: 26 September 2018

Abstract

Background: Varicella (chicken pox) is a highly contagious disease caused by the Varicella-Zoster Virus. Varicella pneumonia is a rare presentation of pneumonia, which is seen in immunocompromised adults.

Cases Report: Here we reported a 13-year-old immunocompetent boy who was admitted with fever and acute respiratory symptoms.

Conclusion: Varicella pneumonia occurring particularly in immunocompromised patients; however, it should not be misdiagnosed in immunocompetent patients.

Keywords: Varicella pneumonia, immunocompetent

*Corresponding Author: Seyedeh Sahar Babaali MD. Medical University of Zanjan, Zanjan, Iran Email: dr.saharbabaali@gmail.com

Please cite this article as: Heidari M, Moghtader Mojdehi AH, Babaali S. Varicella pneumonia: a case report in an immunocompetent patient. *Novel Biomed.* 2018;6(4):196-8.

Introduction

Varicella zoster virus (VZV) is the cause of chicken pox. Although it is common in children, it is rarely seen in adults^{1,2}. Chicken pox in young adults results in serious complications such as pneumonia. Although varicella pneumonia is mostly reported in immunocompromised patients, those with a healthy immune system are not spared^{1,3}. Here we presented an immunocompetent patient with varicella pneumonia who was admitted to hospital with fever and a mild respiratory failure.

Case Report

A 13-year-old high school student presented to the hospital with a low-grade persistent fever for almost

10 days, dizziness and productive cough. Except chicken pox within the last month, he was otherwise a healthy individual. On examination, he was febrile (auxiliary temperature= 37.7°C). He had dyspnea and his respiratory rate was 22. His O₂ saturation was 93% while taking nasal oxygen. He had tachycardia with HR=110 beats/min. We auscultated bilateral decrease in pulmonary sounds. Polymorphic rash with vesicular and crusty lesions were noted mostly on the back (Figure 1).

Laboratory studies did not show any lymphocytosis or leucocytosis. However, serum titre of VZV immunoglobulin M (IgM) was positive. We found no evidence of infection in microbiological sputum examination. His data was negative for Human Immunodeficiency Virus. To prove patient immunocompetency we evaluated the complete profile

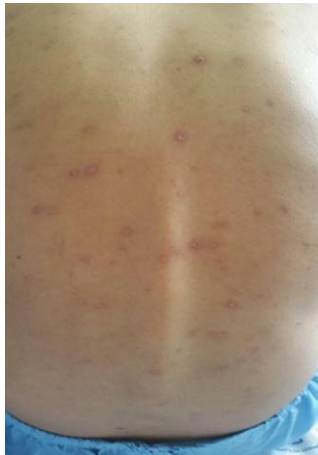

Figure 1. Polymorphic pruritic rash with macular, vesicles and crusty lesions.

of immunoglobulin, which was totally in normal range. The plain chest X-ray showed a consolidation in the middle part of the anterior lobe of the left lung. It was confirmed by the thoracic CT scan findings. Other findings of the thoracic CT scan were diffuse parenchymal infiltration and the ground glass view in the anterior lobe of the left lung (figure 2).

Together with the signs and symptoms, we suspected varicella pneumonia and stated the treatment accordingly. He was both under air-borne and contact isolation. He took nasal oxygen 5L/min. He weighed 60 kg; therefore, IV Acyclovir 600 mg/kg was injected every 4 hours except for the night. We started anti-biotic-therapy to cover his pneumonia. Ciprofloxacin and Vancomycin were both injected IV with 1 gram every 12h dosage. In addition,

Azithromycin tablet 500 mgr every 12h was given to our patient. The patient's respiratory function progressively improved and was discharged after 10 days of hospitalization.

Discussion

The most common complication of VZV in adults is varicella pneumonia; a severe complication which is alternatively fatal. It may occur within 6 days after the primary infection^{4,5}. Clinical presentations could be any of the following: cough, dyspnea, tachypnea, fever, cyanosis and sometimes pleuritic chest pain and hemoptysis^{1,6}. Physical findings are often minimal and chest radiographies typically reveal nodular or interstitial pneumonitis^{7,8}. Our patient had several of these risk factors (young adult, male sex, greater than 100 skin lesions). Physical examination may reveal nothing important while on plain chest X-ray interstitial pneumonitis is seen. The lung CT scan of our patient was remarkable for the ground glass attenuation and some focal diffused consolidations with pleural effusion. Previous studies on patients with varicella pneumonia failed to support our findings where they mostly reported diffused nodules alongside ground glass view without pleural effusion or lymphadenopathy⁹. Since we suspected varicella pneumonia we started Acyclovir which is a well-known treatment for the related disease¹⁰. It is declared that patients with a healthy background are prone to recover completely while unhealthy patients

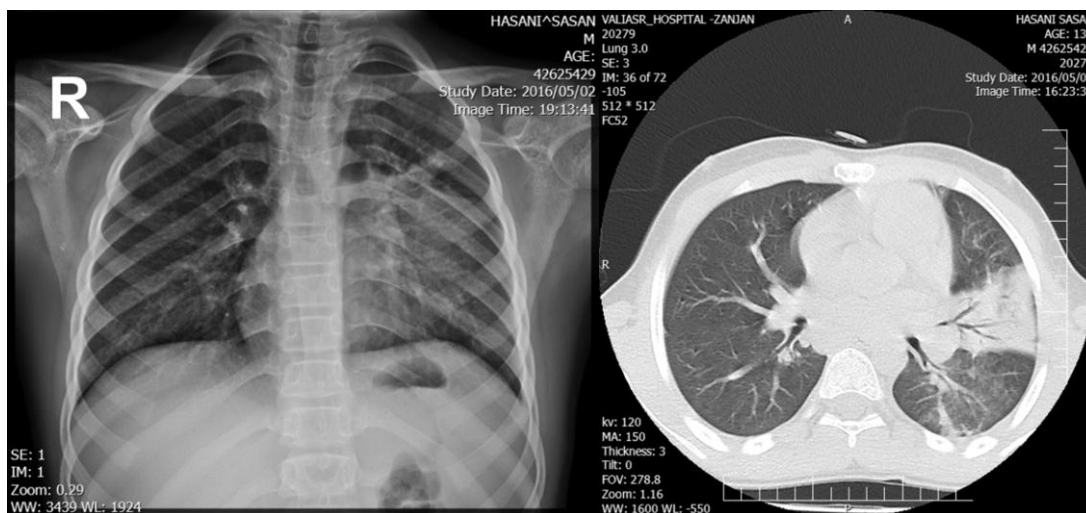


Figure 2. Consolidation in the left lung with the ground glass view, the air-bronchogram in the middle part of the anterior lobe of left lung.

may grow into acute respiratory syndrome¹¹. Our patient's respiratory failure occurred 7 days after his primary chicken pox disease. Although he was a healthy individual, his CT scan findings showed significant changes. However, the outcomes were favourable.

Conclusion

Varicella pneumonia is a severe complication of varicella infection, which mostly occurs in adults. Occurring particularly in immunocompromised patients, it should not be misdiagnosed in immunocompetent patients.

References

1. Kaaniche FM, Chaari A, Ammar R, Bahloul M, Bouaziz M. Varicella pneumonia in an immunocompetent adult: A case report. *Trends in Anaesthesia and Critical Care*. 2015;5(5):146-8.
2. Helmuth IG, Broccia MD, Glenthøj JP, et al. Children Hospitalized With Varicella in Denmark: Sensitivity of the National Patient Register. *The Pediatric Infectious Disease Journal*. 2017;36(1):31-5.
3. Corrigan R, Carter R, Raza M. Use of steroids for management of varicella pneumonia. *BMJ case reports*. 2015;2015:bcr2015210866.
4. Gasparetto EL, Warszawiak D, Tazoniero P, Escuissato DL, Marchiori E. Varicella pneumonia in immunocompetent adults: report of two cases, with emphasis on high-resolution computed tomography findings. *Brazilian Journal of Infectious Diseases*. 2005;9(3):262-5.
5. Anwar SK, Masoodi I, Alfaifi A, Hussain S, Sirwal IA. Combining corticosteroids and acyclovir in the management of varicella pneumonia: a prospective study. *Antiviral therapy*. 2014;19:221-4.
6. Mohsen A, McKendrick M. Varicella pneumonia in adults. *European Respiratory Journal*. 2003;21(5):886-91.
7. Mohsen A, Peck R, Mason Z, Mattock L, McKendrick M. Lung function tests and risk factors for pneumonia in adults with chickenpox. *Thorax*. 2001;56(10):796-9.
8. Ariyasu R, Nakagawa K, Ikegami N, et al. Varicella Reinfection with Unilateral Varicella Pneumonia. *Internal Medicine*. 2016;55(21):3143-5.
9. Alanezi M. Varicella pneumonia in adults: 13 years' experience with review of literature. *Annals of thoracic medicine*. 2007;2(4):163.
10. Petrun B, Williams V, Brice S. Disseminated varicella-zoster virus in an immunocompetent adult. *Dermatology online journal*. 2015;21(3).
11. Reynolds J, McDonald G, Alton H, Gordon S. Pneumonia in the immunocompetent patient. *The British journal of radiology*. 2014.