

Original Article

Effects of Exposure to Sub-Lethal Concentrations of Copper on Hematological and Histopathological Alterations in Common Carp, *Cyprinus Carpio*

Azam Afaghi¹, Samad Zare²¹Department of Biology, Sofian Branch, Islamic Azad University, Sofian, Iran²Science Faculty, Department of Biology, Urmia University, Urmia, Iran**Article Information**

Received: 2020-02-02

Revised: 2020-03-04

Accepted: 2020-03-09

Correspondence

Azam Afaghi

Email: azam.afaghi@gmail.com

Cite this article as:

Afaghi A, Zare S. Effects of Exposure to Sub-Lethal Concentrations of Copper on Hematological and Histopathological Alterations in Common Carp, *Cyprinus Carpio*. Archives of Advances in Biosciences 2020;11(1)

Abstract

Introduction: The present study investigated the toxic effects of copper sulfate on hematological factors, bioaccumulation levels of copper, and histopathology of gill and kidney tissues of Common carp.

Materials and Methods: For this purpose, 90 fish were exposed to different sub-lethal levels of copper sulfate (0.16 and 0.53 mg/L) for 21 days. After 21 days, blood samples were taken. Hematological factors such as hematocrit (Hct), hemoglobin (Hb), red blood cells (RBC), and white blood cells (WBC) were measured in blood samples. Bioaccumulation levels of copper in gill and kidney tissues were determined by wet chemical digestion and atomic absorption apparatus. The data were analyzed by one-way ANOVA and Duncan test, and compared in significant levels of $P < 0.05$. Gill and kidney samples were collected from each group and lesions were analyzed by light microscopy.

Results: The results showed a dose-dependent decrease in hemoglobin, hematocrit, red blood cells and white blood cell count. Copper accumulation in gill and kidney tissues of fishes exposed to sub-lethal copper increased significantly compared with the control group ($P < 0.05$). Histopathologic studies showed a series of changes in gill tissue, including primary lamellar edema, hyperplasia, severe secondary lamellar fusion, and clubbing. Cellular swelling in the tubules and glomeruli, tubular necrosis and formation of hyaline cysts were the main kidney histopathological changes

Conclusion: These results suggest that hematological parameters and gill and kidney changes following metal accumulation in these tissues can be used as sensitive biomarkers to determine the toxicity of sub-lethal concentrations of heavy metals.

Keywords: Common carp, Copper sulfate, Hematological factors, Gill, Kidney

1. Introduction

Copper is an essential micronutrient for the healthy growth and reproduction of all plants and animals. This element plays an important role in cell physiology, feeding and metabolism of vertebrates [1]. Although the essential role of the copper in several enzymatic processes has been cleared [2], this heavy metal can exert adverse toxicological effects, when present in high

concentrations in water [3]. Also, fossil fuels, urban oily chemical fertilizers and application of this element as algae and fungicides have caused significant amounts of this element to enter the aqueous environment [4]. Copper is absorbed through the gill and digestive tract of fish and mainly accumulates in different tissues such as gill, liver, kidney and inner tissues [3]. Gills of fish are used for breathing, gas

exchanges, osmotic regulation and release of nitrogenous lesions. Gills are in direct contact with the outside environment and pollutants. Then, they are the most critical site for copper uptake [5]. The high concentrations of copper sulfate damage the gill epithelium, hematopoietic tissues, kidney, spleen and liver of fish [6]. Subsequently, it changes the blood parameters [5] and osmoregulation [7]. Immunosuppression is also observed in exposure to heavy metals, because monocytes and neutrophils are sensitive to heavy metals [8]. Fish is used widely to assess the quality of the water ecosystem and evaluation of blood factors [3], and histological changes have been investigated as the health biomarkers of fish exposed to pollutants [9]. Hemolysis and anemia in catfish, *Clarias lazera*, exposed to copper has been observed [10]. Many types of research, have reported histopathological changes in different organs (liver, gill, kidney, lungs, etc.) of the fishes exposed to the sub-lethal concentrations of pollutants [11, 12]. Fish can be used widely for food preparation in Iran [13] and a good model for studying the responses of the fish, which are exposed to different environmental pollutants. In this study, the blood factors, copper accumulation rate and histopathological changes in gill and kidney tissues of the common carp (*Cyprinus Carpio*) exposed to the sub-lethal concentrations of copper sulfate for 21 days were examined.

2. Materials and Methods

2.1. Animals

Common carp (*Cyprinus Carpio*) fishes were prepared with a weighted average of 50 ± 200 g. The fishes were placed in the 200 liter tanks filled with aeration water.

2.2. The Physical and Chemical Indexes of Water

Oxygen solution 7.25 ± 3 mg/l, Salinity 1.7g/l, total hardness 526 mg/L, pH = 8,

optical period: 12D/12L and water temperature was 17 ± 1 °c.

2.3. Experimental Groups

In this study, we have a control group and two experimental groups that exposed to two sub-lethal concentrations of copper (0.16 and 0.53 mg/l) for 21 days. Of course, each group was repeated three times.

Copper, in the form of copper sulfate ($\text{CuSO}_4 \cdot 5 \text{H}_2\text{O}$), was weighed and added to the water, and every day to prove the concentration of copper in water, the water is changed.

2.4. Hematological Factors Study

After 21 days, the fish were taken off the water and anesthetized by hitting the head. Blood samples were taken from the caudal vein of fish with a sterile syringe containing heparin solution. The number of red blood cells (RBC) and white blood cells (WBC) were counted under light microscopy using the neobar lam and special solutions (Hayemis solutions for red and Marcano solution for white blood cells) [14]. Blood hemoglobin was determined by the hemoglobin kit and the method of using a spectrophotometer with a wavelength of 540 nm [15]. The percentage of hematocrit was measured by the micro-hematocrit method using heparinized micro-hematocrit capillary tubes and micro-hematocrit centrifuge [6].

2.5. Determination of Copper Concentration

To measure the accumulation of copper in gill and kidney tissues, after separating the tissues from the body, they were inserted in the oven for 48 hours at a temperature of 105 °c to dry, and then were powdered. Of each sample, a gram was weighted with an electrical scale. Digestion of samples was performed by nitric acid and perchloric acid. The atomic spectrometer of Shimadzu Atomic absorption/flame emission spectrophotometer AA-670 was

used to measure of copper in these samples [17].

2.6. Statistical Analysis

For analyzing data, SPSS software was used. The results are indicated as Mean \pm SEM. One-way ANOVA followed by Duncan's test analysis was used to assess the differences between groups. $P < 0.05$ was considered as statistically significance. Chart was also mapped using Microsoft Excel 2016.

2.7. Histopathological Examination

Gill and kidney samples were taken for histopathologic researches in plastic containers containing formalin 10% to fix. Then sectioning was performed at five μ m and staining was done with hematoxylin and eosin. Samples observed by microscope optical and histopathologic images were prepared for histological studies [18].

3. Results

The results of the statistical analysis (one-way ANOVA) showed that there was a significant difference ($P < 0.05$) in the accumulation of copper metal in gill and kidney tissues of experimental groups compared with the control group (table 1 and figure 1). RBC and Hb levels in experimental groups, significantly decreased ($P < 0.05$) (table 2). The decrease

in Hct and WBC were also observed in two experimental groups compared to the control group (table 2). Histopathological changes of gill tissues in different experimental groups are shown in figures 3-5. Healthy gill Tissues (Figure. 2) are related to the control group. Gills of the fish of the experimental group showed a series of pathological changes. The most important changes in the gill of fish exposed to the dose of 0.16 mg/l included primary lamellar edema, infiltration of inflammatory cells inside the filament, the separation of epithelial cells from the secondary lamellar membrane and fusion of the secondary Lamellar (Figure 3). In the gills of the experimental group (0.53 mg/L), hypertrophy and hyperplasia of chloride cells, severe necrotic changes of secondary Lamellar (Figure. 4), the sharp fusion of secondary lamellar and clubbing of secondary lamellar (Figure. 5) has been observed. Histology of kidney tissue of the control group showed a typical structure of renal cortical tissue (Figure 6). After exposure to 0.16 mg/l for 21 days, cell swelling in the tubules and glomerular, bleeding and infiltration of inflammatory cells in the interstitial tissue were observed (Figure 7). Increasing exposure dose (0.53 mg/L) degraded tubular tissue (Figure 8) and hyaline cysts were formed (figure9).

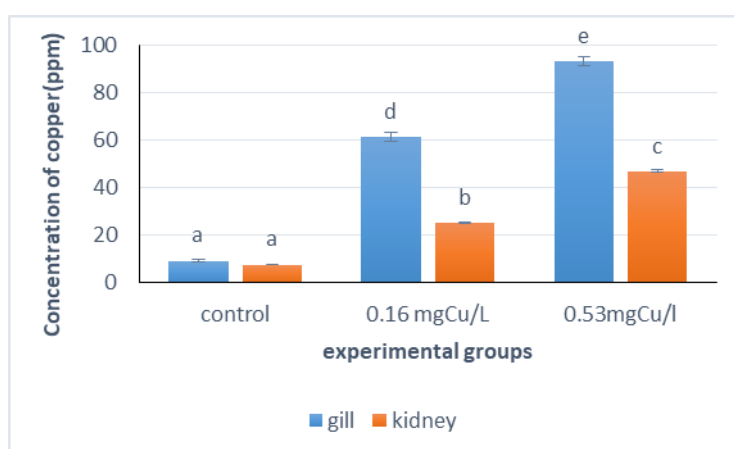


Figure 1. The average concentration of copper (mean \pm SEM) in gill and kidney tissues of common carp. Letters on the column are related to Duncan's test results. The absence of a similar letter between two columns means a significant difference in the level of 0.05

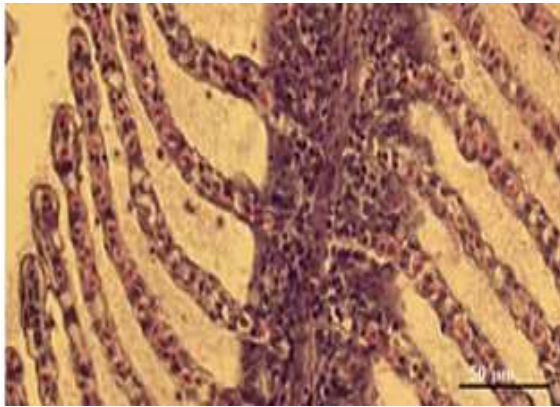


Figure 2. Gill of control group (magnification 400)

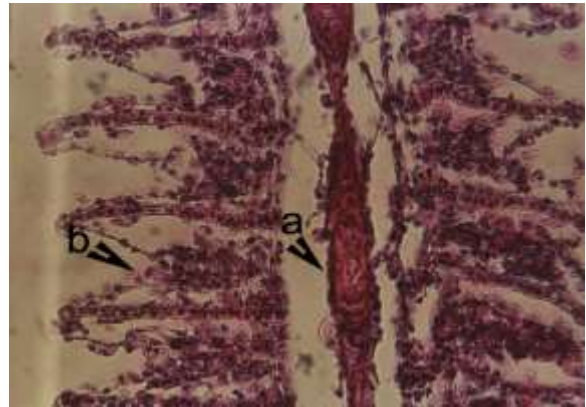


Figure 3. a: primary edema, b: separation of epithelial cells from the secondary lamellar membrane and fusion of the secondary Lamellar (magnification 400)

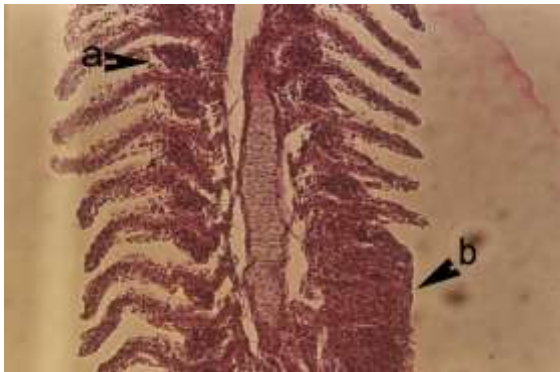


Figure 4. a: hypertrophy and hyperplasia of chloride cell b: necrosis of secondary Lamellar (magnification 400)

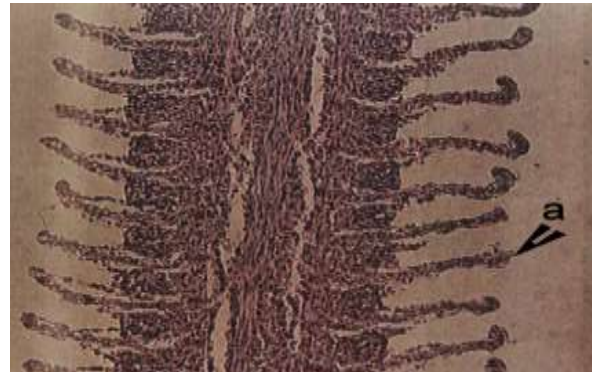


Figure 5. a: clubbing of the secondary lamellar (magnification 400)

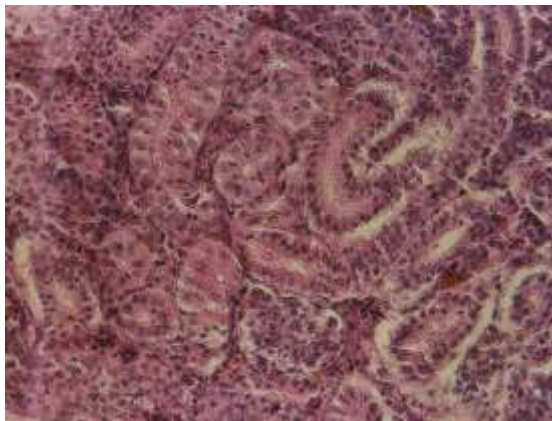


Figure 6. Kidney tissue of control group (magnification 400)

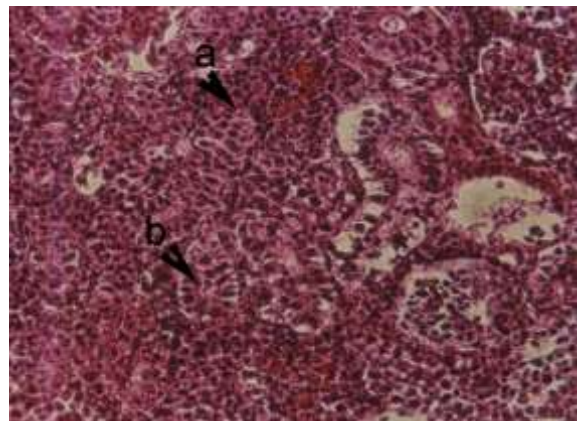


Figure 7. a: tubular tissue degradation, b: glomerular swelling (magnification 400)

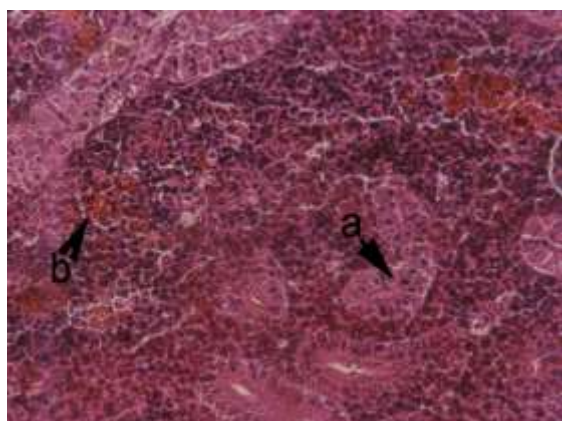


Figure 8. a: cell swelling in the tubules and glomerular, b: Bleeding and the influence of inflammatory cells in the interstitial tissue (magnification 400)

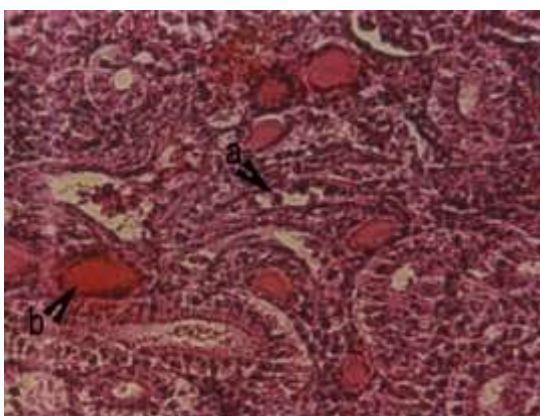


Figure 9. a: tubular necrosis, b: formation of hyaline cysts (magnification 400)

4. Discussion

Gills are the main route of entry of metals into the body of the fish due to direct exposure to toxins in the aquatic environment and thus they store the largest amount of metal in the body [19]. However, liver and kidneys are important organs for the accumulation and storage of heavy metals in fish [20]. The results of this study show that copper accumulation in gill and kidney tissues of experimental groups were significantly increased compared to the control group focusses metal accumulation in this tissue was different. Also, the accumulation rate increased with the dose increase. Hematologic parameters are sensitive markers in evaluating the metabolism of fish exposed to metals stress [21]. Therefore, these are widely measured in toxicology and environmental studies as indicators of physiological changes. Decrease in RBC, Hb and Hct are commonly associated with factors such as degradation of gill tissue, disturbance in osmoregulation by metals and destruction of red blood cells [22]. Ko et al. 2019 reported that metals directly affect hematopoietic cells in the kidney and spleen, increasing their membrane permeability and damaging them, reducing the number of erythrocytes and causing anemia [23]. Joshi and colleagues in 2002 have suggested that exposure to heavy metals due to damaging

iron intestinal absorption system has decreased RBC and Hb concentration [24]. These changes lead to reduced oxygen consumption in the fish and ultimately, their death. In a study conducted by Srivastava and his colleague in 2011, hemoglobin, hematocrit, blood cell count and some of white blood cells in common carp exposed to zinc significantly decreased [25]. Similar results have been reported in common carp exposed to the sub-lethal copper sulfate [3]. Gill is usually the first target tissue for waterborne contaminants and prolonged exposure results in the absorption of these pollutants through the gills, producing visible damage effects in this tissue [26]. The study of fish gill tissue in the experimental groups indicates the presence of lesions in this tissue, including edema, necrosis, secondary filament adhesion, clubbing and the loss of secondary lamellar.

Similar results have been reported in the gill tissue of carp and rainbow trout exposed to copper sulfate [27, 28]. The proliferation of the chloride cells and necrosis in the exposed fish to heavy metals were reported by several researchers [29-31]. The increased permeability of the gill vessels causes the edema in the Lamellar [9]. Edema, epithelial detachment of gill and adherence of lamellar are the defense mechanisms of exposed fish to reduce the gill surface area and increase the diffusion distance between blood and environmental

pollutant [27]. These mechanisms have a harm effect on the breathing of the fish [32]. The proliferation of mucus cells and hypertrophy, which leads to increased mucus secretion, are protective defensive responses to cover absorbent surface [33], which reduce gas exchanges [26]. Through increasing the duration of exposure and an increasing dose of poisoning agent, epithelium thoroughly separates and necrosis of gill tissues is performed. In kidney tissues of all experimental groups, there were also some damages including the reduction of the lumen size of tubules due to the swelling of the epithelial cells of tubule, dilation of glomeruli, necrosis of tubules, interstitial nephritis, the infiltration of inflammatory cells such as lymphocyte and macrophages in interstitial tissue, bleeding and in severe cases, hyaline cysts were found inside the tubules. Changes in kidney tissue of carp were reported in other species of exposed fish to heavy metals [34, 35], which are in accordance with this study. Research done by Patel & Bahadur (2011), investigates the impact of copper metal on gill and kidney tissues of *Catla Catla*, which are also consistent with the results of the present study [36]. Kidney plays an important role in the secretion and detoxification of harmful compounds in the body [37]. Therefore, heavy metals cause the degradation of kidney tissue through producing free radicals and lipid peroxidation of the membrane [38]. Necrosis tubules and degradation of the kidney in this research indicate that the kidney is severely damaged after exposure to copper.

5. Conclusion

Based on the results achieved in this study, it is concluded that metal accumulation in fish depends on the concentration of metal and the type of organ. Overall, when exposed, the gill accumulates copper strongly, compared to the kidney tissue of *Cyprinus carpio*.

Hematological parameters indicated that copper acts as a stressor leading to changes in some blood parameters and accumulation in important tissues. Histological changes of the gills and kidneys are related to the different copper concentrations. Moreover, gill and kidney alterations may serve as a sensitive biomarker for the toxicity of sub-lethal concentrations of metals as well as the other pollutants as a result of heavy metal exposition of the fish.

Conflict of interest

The authors declare no conflict of interest.

References

1. Handy RD. Chronic effects of copper exposure versus endocrine toxicity: two sides of the same toxicological process? *Comparative Biochemistry and Physiology Part A: Molecular & Integrative Physiology*. 2003;135(1):25-38.
2. Shao X-p, Liu W-b, Xu W-n, Xia W, Jiang Y-y. Effects of dietary copper sources and levels on performance, copper status, plasma antioxidant activities and relative copper bioavailability in *Carassius auratus gibelio*. *Aquaculture*. 2010;308(1-2):60-5.
3. Thangam Y, Jayaprakash S, Perumayee M. Effect of copper toxicity on hematological parameters to fresh water fish *Cyprinus carpio* (common carp). *Journal of Environmental Science, Toxicology and Food Technology*. 2014;8(9):50-60.
4. Cruz L, Roberts C, Reiley M, Santore R, Paquin P, Chapman G, et al. Aquatic life ambient freshwater quality criteria-Copper. United States Environmental Protection Agency. 2007.
5. Figueiredo-Fernandes A, Ferreira-Cardoso JV, Garcia-Santos S, Monteiro SM, Carrola J, Matos P, et al. Histopathological changes in liver and gill epithelium of Nile tilapia, *Oreochromis niloticus*, exposed to waterborne copper. *Pesquisa Veterinária Brasileira*. 2007;27(3):103-9.
6. Mazon A, Monteiro E, Pinheiro G, Fernandez M. Hematological and physiological changes induced by short-term exposure to copper in the freshwater fish, *Prochilodus scrofa*. *Brazilian Journal of Biology*. 2002;62(4A):621-31.
7. Singh D, Nath K, Trivedi S, Sharma Y. Impact of copper on haematological profile of

- freshwater fish, *Channa punctatus*. *Journal of Environmental biology*. 2008;29(2):253.
8. Witeska M, Wakulska M. The effects of heavy metals on common carp white blood cells in vitro. *Alternatives to Laboratory Animals*. 2007;35(1):87-92.
 9. Olurin KB, Mbaka GO, Agbato OA. Histopathological effect of sub-lethal concentration of aluminum phosphide (phostoxin) on *Clarias gariepinus* juveniles. *Pesquisa Veterinária Brasileira*. 2016;36(7):574-80.
 10. El-Domiaty N. Stress response of juvenile *Clarias lazera* elicited by copper. *Comparative Biochemistry and Physiology Part C: Comparative Pharmacology*. 1987;88(2):259-62.
 11. Stentiford G, Longshaw M, Lyons B, Jones G, Green M, Feist S. Histopathological biomarkers in estuarine fish species for the assessment of biological effects of contaminants. *Marine Environmental Research*. 2003;55(2):137-59.
 12. Rabitto I, Costa JA, De Assis HS, Pelletier E, Akaishi F, Anjos A, et al. Effects of dietary Pb (II) and tributyltin on neotropical fish, *Hoplias malabaricus*: histopathological and biochemical findings. *Ecotoxicology and environmental safety*. 2005;60(2):147-56.
 13. Salehi H. An analysis of the consumer market for carp and carp products in Iran. *Iranian journal of fisheries sciences*. 2006;5(2):83-110.
 14. Rusia V, Sood SK. Routine hematological tests. *Medical laboratory technology*. 1992;1:252-8.
 15. Drabkin DL. Spectrophotometric studies XIV. The crystallographic and optical properties of the hemoglobin of man in comparison with those of other species. *Journal of biological chemistry*. 1946;164(2):703-23.
 16. Snieszko SF. *Microhematocrit as a tool in fishery research and management*: US Department of Interior, Fish and Wildlife Service, Bureau of Sport ...; 1960.
 17. Ward G, Parrish P. *Manual of methods in aquatic environment research*: Food & Agriculture Org.; 1982.
 18. Mbaka G, Ogonnia S, Awoyemi F. Acute and sub-acute toxicity studies of ethanol seed extract of *Raphia hookeri* on Swiss albino rats. *Brit J Pharm Res*. 2014;4:1196-208.
 19. Kamunde C, Grosell M, Higgs D, Wood CM. Copper metabolism in actively growing rainbow trout (*Oncorhynchus mykiss*): interactions between dietary and waterborne copper uptake. *Journal of Experimental Biology*. 2002;205(2):279-90.
 20. Giguère A, Campbell PG, Hare L, McDonald DG, Rasmussen JB. Influence of lake chemistry and fish age on cadmium, copper, and zinc concentrations in various organs of indigenous yellow perch (*Perca flavescens*). *Canadian Journal of Fisheries and Aquatic Sciences*. 2004;61(9):1702-16.
 21. Vinodhini R, Narayanan M. The impact of toxic heavy metals on the hematological parameters in common carp (*Cyprinus carpio* L.). *Journal of Environmental Health Science & Engineering*. 2009;6(1):23-8.
 22. Saravanan M, Kumar KP, Ramesh M. Haematological and biochemical responses of freshwater teleost fish *Cyprinus carpio* (Actinopterygii: Cypriniformes) during acute and chronic sublethal exposure to lindane. *Pesticide Biochemistry and Physiology*. 2011;100(3):206-11.
 23. Ko H-D, Park H-J, Kang J-C. Change of growth performance, hematological parameters, and plasma component by hexavalent chromium exposure in starry flounder, *Platichthys stellatus*. *Fisheries and Aquatic Sciences*. 2019;22(1):9.
 24. Joshi P, Bose M, Harish D. Haematological changes in the blood of *Clarias batrachus* exposed to mercuric chloride. *Journal of Ecotoxicology & Environmental Monitoring*. 2002;12(2):119-22.
 25. Srivastava R, Punia P. Effect of heavy metal on biochemical and hematological parameters in *Cyprinus carpio* and its use as a bioindicators of pollution stress. *Journal of Ecophysiology and Occupational Health*. 2018.-21:(2-1)11;1
 26. ATABATI A, KEYKHOSRAVI A, ASKARI-HESNI M, VATANDOOST J, MOTAMEDI M. Effects of Copper Sulfate on gill histopathology of grass carp (*Ctenopharyngodon idella*). *Iranian Journal of Ichthyology*. 2015;2(1):35-42.
 27. van Heerden D, Vosloo A, Nikinmaa M. Effects of short-term copper exposure on gill structure, metallothionein and hypoxia-inducible factor-1 α (HIF-1 α) levels in rainbow trout (*Oncorhynchus mykiss*). *Aquatic Toxicology*. 2004;69(3):271-80.
 28. De Boeck G, Vlaeminck A, Balm PH, Lock RA, De Wachter B, Blust R. Morphological and metabolic changes in common carp, *Cyprinus*

carpio, during short-term copper exposure: Interactions between Cu²⁺ and plasma cortisol elevation. *Environmental Toxicology and Chemistry: An International Journal*. 81.-374:(2)20;2001

29. Pane EF, Haque A, Wood CM. Mechanistic analysis of acute, Ni-induced respiratory toxicity in the rainbow trout (*Oncorhynchus mykiss*): an exclusively branchial phenomenon. *Aquatic Toxicology*. 2004;69(1):11-24.

30. Rajeshkumar S, Mini J, Munuswamy N. Effects of heavy metals on antioxidants and expression of HSP70 in different tissues of Milk fish (*Chanos chanos*) of Kaattupalli Island, Chennai, India. *Ecotoxicology and Environmental Safety*. 2013;98:8-18.

31. Hassaninezhad L, Safahieh A, Salamat N, Savari A, Majd NE. Assessment of gill pathological responses in the tropical fish yellowfin seabream of Persian Gulf under mercury exposure. *Toxicology reports*. 2014;1:621-8.

32. Morgan M, Tovell P. The structure of the gill of the trout, *Salmo gairdneri* (Richardson). *Zeitschrift für Zellforschung und mikroskopische Anatomie*. 1973;142(2):147-62.

33. Abalaka SE. Heavy metals bioaccumulation and histopathological changes in *Auchenoglanis occidentalis* fish from Tiga dam, Nigeria. *Journal of Environmental Health Science and Engineering*. 2015;13(1):67.

34. Kaoud H, El-Dahshan A. Bioaccumulation and histopathological alterations of the heavy metals in *Oreochromis niloticus* fish. *Nature and science*. 2010;8(4):147-56.

35. Al-Balawi HFA, Al-Akel AS, Al-Misned F, Suliman EAM, Al-Ghanim KA, Mahboob S, et al. Effects of sub-lethal exposure of lead acetate on histopathology of gills, liver, kidney and muscle and its accumulation in these organs of *Clarias gariepinus*. *Brazilian Archives of Biology and Technology*. 2013;56(2):293-302.

36. Patel J, Bahadur A. Histopathological manifestations of sub lethal toxicity of copper ions in *Catla catla*. *American-Eurasian Journal of Toxicological Sciences (AEJTS)*. 2011;3(1):1-5.

37. Mustafa S, Al-Faragi J, Salman N, Al-Rudainy A. Histopathological alterations in gills, liver and kidney of common carp, *Cyprinus carpio* exposed to lead Acetate. *Adv Anim Vet Sci*. 2017;5(9):371-6.

38. Regoli F. Lysosomal responses as a sensitive stress index in biomonitoring heavy

metal pollution. *Marine Ecology Progress Series*. 1992:63-9.