

## The effect of hyperthyroidism on the levels of liver enzymes in adult male Wistar rats

Alireza Azizi Saraji<sup>1</sup>, Mohammad Doroudian<sup>2</sup>, Mahdiah Soezi<sup>3</sup>, Akram Eydi<sup>4</sup>, Parisa Barzegar Amiri Olia<sup>4</sup>, Hamedeh Bagheri<sup>4\*</sup>

<sup>1</sup>Department of Veterinary Laboratory of Sciences, Young Researchers club, Science and Research Branch, Islamic Azad University, Tehran, Iran.

<sup>2</sup>Young Researchers club, Central Tehran Branch, Islamic Azad University, Tehran, Iran.

<sup>3</sup>Animal&Marine Biotechnology Department, National Institute of Genetic Engineering and Biotechnology (NIGEB), Tehran, Iran

<sup>4</sup>Department of Biology, Faculty of Basic Sciences, Science and Research Branch, Islamic Azad University, Tehran, Iran

\*Corresponding Author: email address: alireza\_azizi8924@yahoo.com (H. Bagheri)

### ABSTRACT

Thyrotoxicosis is a condition in which tissues are stimulated by increased secretion of thyroid hormone. The most common cause is diffuse toxic goiter and toxic multi-nodular goiter. For more reviews on this disease, the effects of hyperthyroidism on liver enzyme levels were studied. A total of 30 adult male Wistar rats weighing about 190 g were purchased from the Pasteur Institute of Iran. In this study, rats were divided into control group, the group receiving vitamin E, the group receiving levothyroxine, the group receiving levothyroxine treated with vitamin E; blood was taken from all groups over a period of 10 days after injection, and measurement of thyroid hormones and liver tests was made. The findings obtained in this study show that Isolated systolic hypertension (ISH) hormone levels in rats treated with levothyroxine, Treatment with vitamin E may reduce serum levels of ISH , Hormone levels of T4 in the rats treated with levothyroxine were increased compared to normal rates. Treatment with vitamin E reduces serum levels of T4 compared to the first hyper group. T4 hormone levels in rats treated with levothyroxine were reduced compared to normal rates. Treatment with vitamin E may reduce serum levels of T4 compared with the first hyper group. Asparagine Transferase (AST) enzyme levels in rats treated with levothyroxine were increased compared, Treatment with vitamin E may reduce serum levels of AST , Alanine transferase (ALT) enzyme levels in rats treated with levothyroxine were increased , Treatment with vitamin E may increase serum levels of ALT , alkaline phosphatase (ALP) enzyme levels in rats treated with levothyroxine has been increased compared with normal rates. Treatment with vitamin E resulted in serum levels of ALT not to be increased compared with the first group. According to the results of hyperthyroidism and levels of liver enzymes, it can be concluded that hyperthyroidism induced by levothyroxine can increase the levels of hormones T3, T4 and Thyroid Stimulating Hormone (TSH), and then increase the levels of liver enzymes. Treatment of empirical samples with vitamin E is likely to reduce liver damages and prevent the increased levels of liver enzymes compared to empirical samples of hyperthyroidism which have been treated with vitamin E.

**Keywords:** liver enzymes; hyperthyroidism; rat; levothyroxine

### INTRODUCTION

Hyperthyroidism or thyrotoxicosis is a condition in which tissues are stimulated by an increased secretion of thyroid hormone. The most common cause of hyperthyroidism is diffuse toxic goiter and toxic multi-nodular goiter. Other causes are toxic adenoma, single and sometimes multiple adenomas of follicular cells, whose secretion and activity is dependent on isolated systolic hypertension (ISH).

Increased metabolism in response to hyperthyroidism can cause oxidative damage to certain organs, including liver, heart and muscles. Thyroid function can be regulated by two hyperthyroid and interthyroid mechanisms. Thyroiditis, which increase in T3 and T4 during an inflammatory process and a transient hyperthyroidism, that along with a return to the stage of euthyroidism and finally hypothyroidism, is due to the destruction of the tumor caused by the frequent recurrence of

inflammation. Due to an unknown cause, T3 of thyrotoxicosis reduces the increased normal levels of T3 and T4. Iodine-induced hyperthyroidism resulting from the prescription of supplementary iodine in people endemic goiter can lead to thyroid hormone [1].

In most cases, changes in the thyroid gland are similar to the cases that have arisen due to an increase in Thyroid Stimulating Hormone (TSH); however, the ISH concentration in almost all patients is less (no more) than normal, and sometimes the secretion of ISH reaches zero. [1] In addition, almost in all these patients, there are other substances which act like ISH. These materials, which are immunoglobulin antibodies, are connected to the membrane receptors of ISH. They cause the sequential activation of the cyclic adenosine monophosphate (cAMP) system of the cells, and can cause hyperthyroidism. These antibodies are called thyroid-stimulating immunoglobulins (TSI). TSI has the prolonged (12 h) stimulatory effect on the thyroid gland, but the stimulating effect of ISH is little more than one hour. TSI causes excessive secretion of thyroid hormone, and thyroid hormone also inhibits secretion of ISH from the anterior pituitary. Antibodies responsible for hyperthyroidism are probably due to the emergence of autoimmunity against thyroid tissue. Probably in a period of one's past life, thyroid cell antigens are released in large amounts of these cells, and produce antibodies against thyroid gland itself. [1] Graves' disease is usually seen in other names such as diffuse goiter, hyperthyroidism, infiltrative ophthalmopathy, and infiltrative dermopathy) [2]. Symptoms of hyperthyroidism may include increased irritability, intolerance to heat, increased sweating, mild to severe reduction and sometimes up to 79 Kg, varying degrees of diarrhea, muscle weakness, nervousness, extreme fatigue with inability to sleep, shaking hands [1]. The most accurate test for routine diagnosis of hyperthyroidism is a direct measurement of free T4 and T3 concentration of plasma using a radio immunoassay method [1]. The fastest way to treat hyperthyroidism is removing much of the thyroid gland by surgery [1-2]. Increased metabolism in response to hyperthyroidism can cause oxidative damage to certain organs, including liver, heart and muscles [3]. Despite numerous clinical studies about the relationship of hyperthyroidism with liver function, little empirical research has been made in this area.

Considering that conditions of empirical studies are much more controlled, this study indicates the extent of the effect of liver dysfunctions during short-term hyperthyroidism on the liver enzyme levels.

## MATERIALS AND METHODS

A total of 30 adult male Wistar rats weighing approximately 150 g was purchased from the Pasteur Institute of Iran, and were classified into groups of seven. Then, they were kept in separate cages and suitable conditions with temperatures of  $22 \pm 2^\circ\text{C}$  and a light-dark cycle of 12 h of light and 12 h of darkness (LD 12:12) and relative humidity of 70-50 percent. After the rats reached a weight range of about 200-250 g, the test was started. In this study, rats were divided into control group, the group receiving vitamin E, the group receiving levothyroxine, the group receiving levothyroxine treated with vitamin E. Firstly, levothyroxine drug was used to induce hyperthyroidism. After this drug is injected intraperitoneally for 10 days, it causes an animal model of hyperthyroidism disease. Rats in the control group received normal food and water only during this period. At the second stage, the drug of levothyroxine with the previous dose was used along with vitamin E. At this point, the control group received only vitamin E; and the other group received only the levothyroxine intraperitoneally. Blood was taken from all groups over a period of 10 days after injection, and measurement of thyroid hormones and liver tests was made (Diagrams 6 - 5 - 4) [1-2].

### *How to work with T3 Monobind kit Stages of tests T3 kit*

50  $\mu\text{l}$  of the standard sample were poured for the control into the wells. 100  $\mu\text{l}$  of conjugate solution of T3 were added to all wells. The plate gently was shaken for 20-30 seconds with the hand until conjugated solution was well mixed with serum. Then the surface of the wells was covered to avoid evaporation during incubation, the plate was incubated for 60 min at room temperature. The contents of the plate were emptied. 300  $\mu\text{l}$  of diluted washing solution Added to all wells and then drained them. This procedure was performed three times. 100  $\mu\text{l}$  of the prepared substrate solution (mixture of A and B) were added to all wells. The plate was incubated for 15 min at room temperature in a dark environment. 50  $\mu\text{l}$  of STOP solution were added to all wells, and the plate was gently shaken for 15-20 seconds with the hand on the

table surface. The plate was read at a wavelength of 790 nm (reference wavelength of 520 nm). OD of calibrators and curves in the brochure of the kit was given as an example; since incubation of the kit was done at room temperature, temperature and other parameters of the laboratory naturally affect on your optical density (OD) (Diagram 3).

#### **How to work with T4 Monobind kit Stages of tests T4 kit**

25 µl of the standard sample were poured for the control into the wells. 100 µl of conjugate solution of T4 were added to all wells. The plate was shaken gently for 20-30 seconds with the hand on the table surface until the conjugate solution was well mixed with serum. Then the surface of the wells was covered to avoid evaporation during incubation, the contents of the wells. The plate was incubated for 60 min at room temperature. The contents of the plate were emptied. 300 µl of diluted washing solution was added to all wells and then drained. The above procedure performed three times. 100 µl of the prepared substrate solution (mixture of A and B) were added to all wells. The plate was incubated for 15 min at room temperature in a dark environment. 50 µl of STOP solution were added to all wells, and the plate was gently shaken for 15-20 seconds with the hand on the table surface. The plate was read at a wavelength of 450 nm (reference wavelength of 620 nm). OD of calibrators and curves in the brochure of kit were given as examples; since incubation of the kit was done at room temperature, temperature and other parameters of the laboratory naturally affect on the OD (Diagram 3).

#### **How to work with TSH Monobind kit Stages of tests TSH kit**

50 µl of the standard sample were poured for the control into the wells. 100 µl of conjugate solution of TSH were added to all wells. The plate was shaken gently for 20-30 seconds with the hand on the table surface until the conjugate solution was well mixed with serum. Then the surface of the wells was covered to avoid evaporation during incubation, the contents of the wells. The plate was incubated for 60 min at room temperature. The contents of the plate were emptied. 300 µl of diluted washing solution was added to all wells and then drain them. The above procedure should be performed five times. 100 µl of the prepared substrate solution (mixture of A and B) were added to all wells. The plate was incubated for 15 min at room temperature in

a dark environment. 50 µl of STOP solution were added to all wells, and the plate was gently shaken for 15-20 seconds with the hand on the table surface. The plate was read at a wavelength of 450 nm (reference wavelength 620 nm). OD of calibrators and curves in the brochure of kit were given as examples; since incubation of the kit was done at room temperature, temperature and other parameters of the laboratory naturally affect on the OD (Diagram 3). After removal of the liver through surgery, its cross-section was placed in 10% formalin. According to conventional methods, the necessary sections were prepared, and were stained with hematoxylin and eosin (Figure 1.2.3).

## **RESULTS**

After measuring the serum level of aspartate aminotransferase (AST) and the serum level of Alanine Transferase (ALT) and the serum level of alkaline phosphatase (ALP), all data were statistically evaluated using one-way ANOVA and Tukey test.

Results were presented as Mean±S.E.M. The criterion for statistical inference is  $P < 0.005$  for 5 rats.

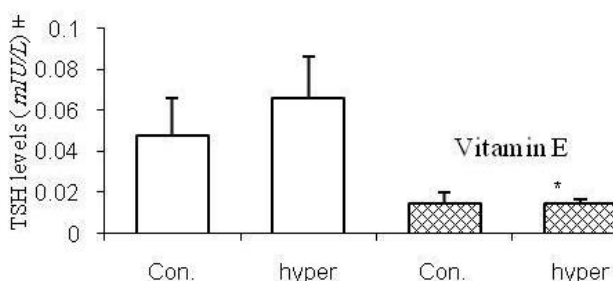


Diagram 1. Effect of 10-day injection of levothyroxine (with a dose of 0.01 mg per kg of the rats' weight) and vitamin E (1 cc) on TSH levels in male Wistar rats.

Con: control hyper: hyperthyroidism

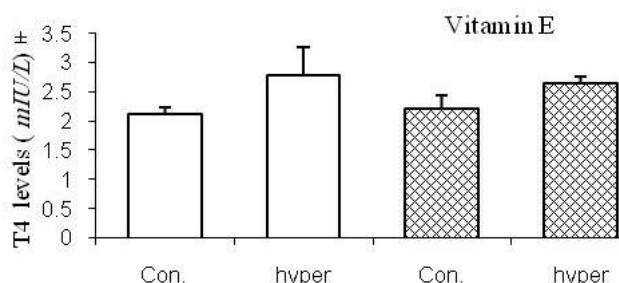


Diagram 2. Effect of 10-day injection of levothyroxine (with a dose of 0.01 mg per kg of the rats's weight) and vitamin E (1 cc) on T4 levels in male Wistar rats.

Con: control hyper: hyperthyroidism

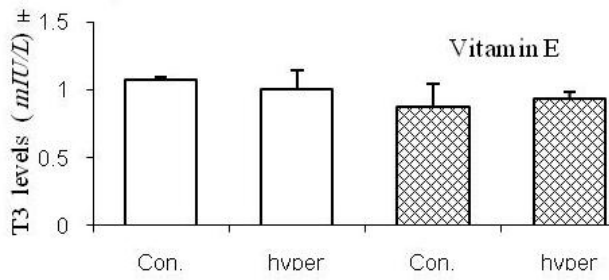


Diagram 3. Effect of 10-day injection of levothyroxine (with a dose of 0.01 mg per kg of the rats' weight) and vitamin E (1 cc) on T4 levels in male Wistar rats.  
Con: control hyper: hyperthyroidism

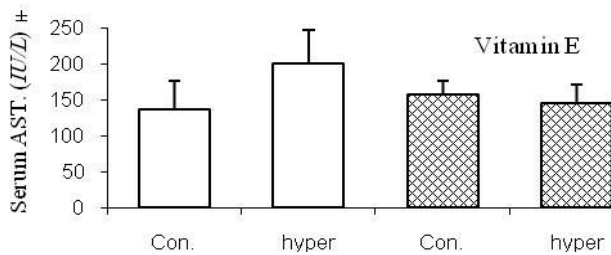


Diagram 4. Effect of 10-day injection of levothyroxine (with a dose of 0.01 mg per kg of the rats' weight) and vitamin E (1 cc) on AST enzyme levels in male Wistar rats.  
Con: control hyper: hyperthyroidism

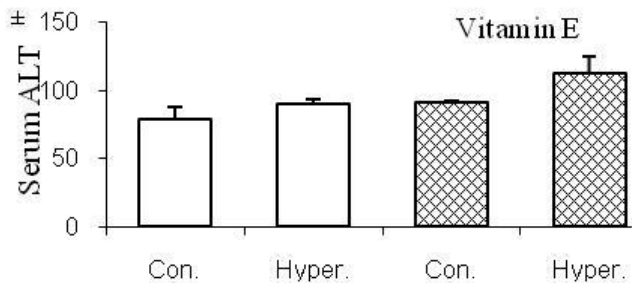


Diagram 5. Effect of 10-day injection of levothyroxine (with a dose of 0.01 mg per kg of the rats' weight) and vitamin E (1 cc) on ALT enzyme levels in male Wistar rats.  
Con: control hyper: hyperthyroidism

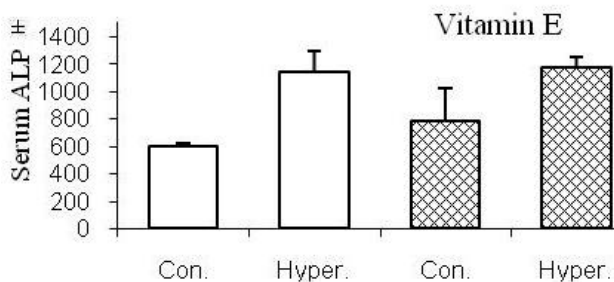


Diagram 6. Effect of 10-day injection of levothyroxine (with a dose of 0.01 mg per kg of the rats' weight) and vitamin E (1 cc) on ALT enzyme levels in male Wistar rats.  
Con: control hyper: hyperthyroidism

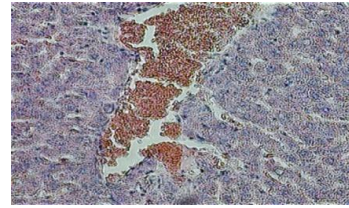


Figure 1. tissue section of the liver in a group that only received levothyroxine. Moderate inflammation in the port areas with mild fibrosis in the port area of inflammation and mild parenchymal edema as well as bile ducts.



Figure 2. tissue section of the liver in a group that received vitamin E with levothyroxine. Mild to moderate inflammation and fibrosis of port areas; an increase in the small bile areas Vacuolation of hepatocytes were not seen. Parenchymal veins were dilated and increased Kupffer cells were observed.




Figure 3. tissue section of the liver in a group that only received vitamin E. Moderate inflammation of the port area with mild to moderate fibrosis, as well as a mild inflammation of the parenchyma In addition, the veins were dilated in the sample.

**DISCUSSION**

Increased metabolism in response to hyperthyroidism can cause oxidative damage to certain organs, including liver, heart and muscles [3]. Weight loss despite increased appetite is a classic symptom of thyrotoxicosis that has been proven by laboratory and clinical studies.

Clinical studies also suggest the effect of hyperthyroidism on the function of liver enzymes. Most sensitive and most widely used liver enzymes are aminotransferases, the most important of which are Aspartate amino Transferase (AST) and Alanine Transferase (ALT). Paul D. Bartels et al. studied the gluconeogenesis and ketogenesis in the liver of rats in 1980, and found that thyroid hormone

changes gluconeogenesis and ketogenesis in the liver of rats injected; and possibly higher levels of thyroid hormones decrease gluconeogenesis and ketogenesis [4]. C. Landriscina and F. M. Ruggiero (1990) studied the formation of lipids in mitochondria and microsoma of liver in hyper thyroid rats. A significant reduction in cholesterol levels was observed in organelles of liver in hyperthyroid rat; lower cholesterol and phospholipid were observed in microsome [5]. Effects of antioxidant drugs on the potential dysfunctions caused by hyperthyroidism can be useful and instrumental, because it may suggest that antioxidant drugs can prevent damage to the liver in patients with hyperthyroidism – the aspect which is clinically very important. Thus, in the first step of the study, the effect of levothyroxine-induced hyperthyroidism on liver enzymes was studied. To this end, we intraperitoneally injected the levothyroxine drug for 10 days with a single dose. In 2007, A. Tanaka, T. Kawakani et al. observed levothyroxine-induced liver injury in patients with primary hypothyroidism, which had spent two months of treatment with the drug [6]. The study of Grasil.kraupp and g.lozano on the protective effects of vitamin E on liver in 2002 showed that the vitamin is a useful antioxidant that can help reduce liver fibrosis, biliary atresia and inflammation of liver parenchyma. In the second stage, the effects of antioxidant drugs (vitamin E, for example) on the activities of liver enzymes were evaluated in an animal model of hyperthyroidism disease, which was induced by levothyroxine. In this stage, in addition to the intra peritoneal injection of levothyroxine with the same previous dose of vitamin E, they were also treated by gavage. After a few days, blood was taken from ventricles of both groups, and the experimental results suggest high levels of thyroid hormones, including ALP, ALT and AST, as the result of levothyroxine injection in comparison with the control group. Also, examining the enzyme levels of liver in blood (including ALT, AST and ALP) indicates high levels of these enzymes in hyperthyroid rats compared with the control rats. Several studies have been conducted on the effects of thyroid hormones in the liver. Studies show that thyroxine and triiodotyronine hormones can affect many functions of the liver. Most of these effects may be mediated due to binding of thyroid hormones to nuclear receptors for thyroid hormone. After

binding of thyroid hormones to nuclear receptors, gene expression is affected. Some are active in their expression, and some are suppressed [7-8]. On the other hand, recent studies show that thyroid hormones can affect expression levels of thyroid receptors [9]. There are reports showing that thyroid hormones cause the phosphorylation and dephosphorylation of many cytosol proteins. Studies show that the activity of protein of kinase A (protein of kinase associated with cAMP in the liver of rats with hyperthyroidism) is one and a half times the rats with hypothyroidism [10]. Most studies have been conducted on the effect of thyroid hormones on the rate of metabolism [3]. This cellular damage usually occurs when the balance of oxidants and antioxidants in the body is disturbed, and the antioxidant system of the body is not able to neutralize these oxidants. In this case, the increase in oxidative stresses causes peroxidation of lipids, damage to proteins and DNA fragmentation [11]. In the year 1999, Nal-erden and avsen akalm studied the effects of propyl-thyracil, propranolol and vitamin E on lipid peroxidation and antioxidant states in patients with hyper thyroid. Previous studies have shown that substances such as melatonin can prevent liver damage induced by thyroid dysfunctions (such as increased peroxidation of lipids) by increasing the rate of elimination of free radicals and directly increasing antioxidant activity [11-12]. So to gain a similar experience with the aim of examining the effect of antioxidants in reducing liver injury in the second stage of the study, the experienced rats received a certain dose of vitamin E by gavage, while levothyroxine with the previous dose was intraperitoneally injected into them. After the treatment period and after a few days of rest, blood was also taken from the ventricle of this group. As it was said in the previous chapter, the results suggest that T3, T4, and TSH hormone levels in hyper rats treated with vitamin E were reduced compared to hyper rats. In addition, serum levels of AST in hyper rats treated with vitamin E were decreased compared to the first group i.e. hyper (with vitamin E); i.e. treatment with vitamin E prevents the increase in serum levels of AST. Serum levels of ALT in hyper rats treated with vitamin E were increased compared to the first hyper group; i.e. treatment with vitamin E may increase serum levels of ALT. Serum levels of

ALP in hyper rats treated with vitamin E were not increased compared to the first group. Studies show that thyroid hormones play an important role in the normal functioning of the digestive tract. There is abundant evidence in which thyrotoxicosis can cause abnormalities of liver function after examining slices of liver tissue from hyper thyroid samples [13-14]. V. Gnoni in 2000 observed cases of edema and inflammation of bile ducts and liver parenchyma as well as the cholestasis [15]. Liver damage that can be seen in hyperthyroidism has a wide range - from the mild abnormalities in function to liver ischemia [14-16]. As it is given in the section of Results with the figures for each case, changes in liver tissue in all three cases in this study (group receiving the levothyroxine drug, group receiving the drug of vitamin E and the group who received only vitamin E) were examined. Moderate inflammation and mild fibrosis in port areas, the increase in the small bile areas, as well as parenchymal inflammation and edema, and bile ducts were reduced in hyper thyroid rats. In the group receiving vitamin E with levothyroxine, mild inflammation and fibrosis in port areas as well as increased Kupffer cells were observed. Although parenchymal veins were dilated, parenchymal inflammation and edema were less. In a group that only received vitamin E, there was mild inflammation found in the port area and the parenchyma; and parenchymal veins were dilated. In the year 1987, Gavm Artel and assistants reported that in hyperthyroidism rats, the number of damaged

liver cells was decreased after 2-month intake of vitamin E [17]. Recent studies indicate that hyperthyroidism induces apoptosis in the liver of rats. In 2005, Ashok kumar et al. studied the induction of apoptosis in rat liver by hyper hypothyroidism via activation of the death pathway of mediated receptor). This study showed that hypothyroidism can induce cell death (by receptors such as neurotrophin receptor p75 of a member of the family of TNF receptors in rat liver). Recent studies indicate that in triiodothyronine-induced hyperthyroidism, internal pathway of apoptosis is activated by a direct effect of triiodothyronine hormones on mitochondria [18]. It is clear, according to the studies, that in triiodothyronine-induced hyperthyroidism, the extracellular factors inducing cell death (such as Tumor necrosis factor (TNF) and Fas) are increased, and can cause damage to liver cells through the activation of an external pathway of apoptosis. Therefore, according to the results of this experiment and the summarized results of similar experiments by other researchers in relation to the hyperthyroidism and levels of liver enzymes, it can be concluded that hyperthyroidism induced by levothyroxine can increase the levels of hormones T3, T4 and TSH, and then increase the levels of liver enzymes. Treatment of empirical samples with vitamin E is likely to reduce liver damages and prevent the increased levels of liver enzymes compared to empirical samples of hyperthyroidism which have been treated with vitamin E.

## REFERENCES

1. Guyton AC, Hall JE. Parathyroid Hormone. In: Textbook of Medical Physiology. 10th ed. USA: W.B. Saunders Co, 2000; 899-915.
2. Lazarus JH, Premawardhana LD. screening for thyroid disease in pregnancy. J Clin Pathol. 2005;58(5):449-52.
3. Venditti P, Di Meo S. Thyroid hormone-induced oxidative stress. Cell Mol Life Sci. 2006; 63(4): 414-34.
4. Bartels PD, Sestoft L. Thyroid hormone-induced changes in gluconeogenesis and ketogenesis in perfused rat liver. Biochim Biophys Acta. 1980; 17;633(1):56-67.
5. Ruggiero FM, Landriscina C, Gnoni GV, Quagliariello E. Lipid composition of liver mitochondria and microsomes in hyperthyroid rats. Lipids. 1984;19(3):171-8.
6. Kawakami T, Tanaka A, Negoro S, Morisawa Y, Mikami M, Hojo M, et al. Liver injury induced by levothyroxine in a patient with primary hypothyroidism. Intern Med. 2007; 46(14):1105-8.
7. Weinberger C, Thompson CC, Ong ES, Lebo R, Gruol DJ, Evans RM. The c-erb-A gene encodes a thyroid hormone receptor. Nature. 1986; 324: 641-6.
8. Williams GR. Cloning and characterization of two novel thyroid hormone receptor beta isoforms. Mol Cell Biol. 2000; 20(22): 8329-42.
9. Strait KA, Schwartz HL, Perez-Castillo A, Oppenheimer JH. Relationship of c-erbA mRNA content to tissue triiodothyronine nuclear binding capacity and function in developing and adult rats. J Biol Chem. 1990; 265(18): 10514-21.

10. Nakamura H, Leslie J. Thyroid hormone stimulation of phosphorylation and dephosphorylation of rat liver cytosolic proteins. *Endocrinology*. 1983; 112(2): 670-80.
11. Rapozzi V, Comelli M, Mavelli I, Sentjurc M, Schara M, Perissin L, et al. Melatonin and oxidative damage in rats liver induced by the prooxidant antitumor drug, adriamycin. *In Vivo*. 1999; 13(1): 45-50.
12. Reiter RJ, Tan DX, Mayo JC, Sainz RM, Leon J, et al. Melatonin as an antioxidant: biochemical mechanisms and pathophysiological implications in humans. *Acta Biochim Pol*. 2003(50); 50: 1129-46.
13. Kobayashi C, Sasaki H, Kosuge K, Miyakita Y, Hayakawa M, Suzuki A, et al. Severe starvation hypoglycemia and congestive heart failure induced by thyroid crisis, with accidentally induced severe liver dysfunction and disseminated intravascular coagulation. *Intern Med*. 2005; 44(3): 234-9.
14. Hasan MK, Tierney WM, Baker MZ. Severe cholestatic jaundice in hyperthyroidism after treatment with 131-iodine. *Am J Med Sci*. 2004; 328(6): 348-50.
15. Cury Y, Garcia LJ. The inflammatory response of hyperthyroid and hypothyroid rats. Role of adrenocortical steroids. *Agents Actions*. 1984; 15(3-4):377-85.
16. Sola J, Pardo-Mindan FJ, Zozaya J, Quiroga J, Sangro B, Prieto J. Liver changes in patients with hyperthyroidism. *Liver*. 1991; 11(4): 193-7.
17. Arteel GE. Oxidants and antioxidants in alcohol-induced liver disease. *Gastroenterology*. 2003; 124(3):778-90.
18. Upadhyay G, Singh R, Kumar A, Kumar S, Kapoor A, Godbole MM. Severe hyperthyroidism induces mitochondria-mediated apoptosis in rat liver. *Hepatology*. 2004; 39(4): 1120-30.