

FACTORS RELATED TO ABNORMAL NEUROIMAGING IN CHILDREN WITH FIRST UNPROVOKED SEIZURE

Azita TAVASSOLI MD¹,
Shahriar NOORMOHAMADI MD²

1. Assistant Professor of Pediatric Neurology, Tehran University of Medical Sciences, Tehran, Iran
2. General Pediatrician, Tehran, Iran

Corresponding Author:
A. Tavassoli MD
Ali-Asghar Children's Hospital, Tehran, Iran
Email: azita_tavassoli@yahoo.com

Received: 10-Dec-2010
Last Revised: 7-Feb_2011
Accepted: 12-Feb-2011

Abstract

Objective

The first attack of unprovoked seizure is more frequent than recurrent one and neuroimaging is one of the main parts of the evaluation of these attacks in order to demonstrate the cause and predict the prognosis. The aim of this study was to determine the incidence of abnormal neuroimaging and related factors in children with the first unprovoked seizure.

Materials & Methods

A 7-year retrospective chart review was done on all children who were visited at Ali-Asghar Children's Hospital with the first unprovoked seizure and underwent neuroimaging including brain computed tomography or magnetic resonance imaging. The diagnostic criteria for the first unprovoked seizure in this study were based on the absence of any immediate or acute cause for the first seizure such as fever, head trauma, hypoglycemia, hypocalcemia, electrolyte imbalance and etc. We compared the rate of abnormal neuroimaging in patients according to different clinical and electroencephalographic (EEG) parameters.

Results

One hundred and forty two patients (63 females, 79 males) were included in the study. Twenty eight patients (20%) had abnormal neuroimaging. CT scan and MRI were done in 63% and 37% of the patients, respectively. The most common abnormalities were cerebral dysgenesis (n=9) and cortical brain atrophy (n=6). Patients who were abnormal on neurologic examination had a higher rate of abnormal imaging in comparison with neurologically normal children (51% vs. 10%). Abnormal imaging was more frequent in children with an epileptiform activity in EEG compared to normal EEG (34% vs. 11%). Although not statistically significant, partial type of seizure, seizure recurrence within 24-hr and age 3-12 year were also associated with a higher rate of abnormal neuroimaging.

Conclusion

Neuroimaging should be considered in any child with the first episode of unprovoked seizure, especially those with an abnormal neurologic examination or abnormal EEG.

Keyword: Children; first unprovoked seizure; neuroimaging.

Introduction

The first unprovoked seizure is more frequent than recurrent epilepsy (1). Almost all of these seizures are focal or generalized convulsions because the patients with other minor types of seizure, such as myoclonic jerks or absence, are usually referred

only after multiple attacks (2). The first seizure could be provoked or unprovoked. Provoked seizure results from an immediately apparent cause such as fever, head trauma or hypoglycemia (3, 4). Recurrences of these seizures are less common (1) and only develop in the presence of an acute cause and therefore do not constitute epilepsy (4). In contrast, in unprovoked seizure, no immediate precipitating factor could be found. So, there is possibility of an underlying neurologic abnormality that may trigger recurrence of seizures or developing epilepsy (4,5). Unprovoked seizures have been classified as cryptogenic (no known cause in despite of abnormal neurologic examination or abnormal developmental state), remote symptomatic (resulting from brain injuries or lesions), or idiopathic (probably genetic) (4). The most common cause of the first seizure is new-onset epilepsy (6). EEG and neuroimaging are principal parts of diagnostic evaluation (1). Neuroimaging helps to reveal the abnormality resulting in seizure and to determine the prognosis (7). Studies evaluating the role of imaging in the first unprovoked seizure have shown different results (4). The practice parameter of the American Academy of Neurology has recommended imaging as a part of work-up in the first unprovoked seizure (8) but a second practice parameter for children with the first unprovoked seizure has recommended imaging as a practice option not as a standard (9). Another review recommends non-urgent imaging in the first unprovoked seizure in any child with an abnormal neurologic exam, abnormal EEG or in children under 1 year of age (10).

In this retrospective study, we reviewed the results of neuroimaging studies and factors related to abnormal imaging in children with the first unprovoked seizure.

Materials & Methods

In this retrospective study, at first, we reviewed hospital charts of all the patients who were admitted to Ali-Asghar Hospital between 2003 and 2009 with the final diagnosis of first unprovoked seizure. Then, medical records of the patients with this diagnosis who had both neuroimaging and EEG results in their records were selected. The diagnostic criteria for the first unprovoked seizure in this study were based on the absence of any immediate or acute cause for the first seizure such as fever, head trauma, hypoglycemia, hypocalcemia, electrolyte

imbalance, etc. Patients included 142 patients aged 1 month to 16 years. Data was collected on age, sex, seizure type, frequency of seizure in the same day, results of neurologic examination, EEG, and neuroimaging findings. Finally, data was analyzed to determine the prevalence of abnormal neuroimaging in patients with first unprovoked seizure. Also, the prevalence of abnormal neuroimaging was studied according to factors such as age, type of seizure, neurologic examination and EEG results. We used Fisher's exact test for data analysis.

The study was approved by the Ethics Committee of Iran University of Medical Sciences.

Results

The 142 children were comprised of 79 (56%) boys and 63 (44%) girls. About 61% of them were in the age group 3-12 year, 23% were less than 3 years and 16% were more than 12 years. Neuroimaging study including brain CT scan or MRI was performed in all patients and abnormalities were found in 28 patients (20%). Abnormalities consisted of cerebral dysgenesis including heterotopias, agenesis of corpus callosum and cortical dysplasia (n=9), brain atrophy (n=6), old infarcts (n=3), porencephalic cyst (n=2), peri ventricular leukomalacia (n=2), arachnoids cyst (n=1), focal calcifications (n=3), arrested hydrocephalus (n=1), possible mesial temporal sclerosis (n=1). 62% of children presented with generalized and 38% with partial type seizure. Neurologic examination was abnormal in 23% of patients. EEG abnormalities were seen in 37% of the patients. Children with abnormal neurologic examination demonstrated a higher chance of having abnormal imaging in comparison with neurologically normal children ($p < 0.05$).

In 27% of the patients, unprovoked seizure recurred within 24 hours. They only had a little higher rate of abnormal imaging that was not statistically significant. Also, seizure type and age group of the patients were not related to the higher rate of abnormal imaging. The prevalence of abnormal imaging according to different factors is shown in Table 1.

Table 1: Proportion of children with abnormal imaging in different subgroups of 142 children with first unprovoked seizure

		Number	Percent	Imaging abnormal		
				Number	Percent	P Value
All children		142	-	28	20	-
Neurologic Exam	Normal	109	77	11	10	0.0002
	Abnormal	33	23	17	51	
Seizure Type	Generalized	88	62	12	14	0.0915
	Partial	54	38	16	29	
EEG	Normal	89	63	10	11	0.011
	Abnormal	53	37	18	34	
Age	<3 Years	34	23	7	21	0.98
	3-12 Years	86	61	17	20	
	>12 Years	22	16	4	18	
Seizure Recurrence/24 hr	No Recurrence	104	73	20	19	0.82
	Recurrence	38	27	8	21	

Discussion

Neuroimaging abnormalities have been reported in up to one-third of all children with the first unprovoked seizure (11). Several studies have proposed that yield on MRI in children with first unprovoked seizure is about 20-30% and abnormalities requiring acute intervention are much fewer, approximately 1% (2). In our study, 20% of patients had abnormal imaging but none of them required an acute change in management. Patients with abnormal neurologic examination had a higher rate of abnormal imaging. These findings are similar to a prospective study in New York (8) as well as a retrospective study of the role of CT scan in children with first unprovoked seizure (7). In a study by Alou-Kasbi et al, the incidence of neuroimaging abnormality was higher (47%) (12) which could be in part due to using brain MRI more than CT scan which is more sensitive to detect abnormalities. The most common abnormality in our study was cerebral dysgenesis including cortical dysplasia that is similar to a study by Shinnar et al (8). Children with cortical dysplasia may have no clinical symptoms except for seizures (13). Finding abnormalities in imaging influences prognosis and is predictive of recurrence (8). Patients

with partial seizure only had a mildly increased rate of abnormal imaging, similar to some other studies (7,8), which may be in part due to benign focal epilepsies of childhood in some patients. Besides, the imaging modality used in most patients in our study was CT scan which is less sensitive in detection abnormalities. If MRI, especially with observing epilepsy protocol that includes thin cuts of the hippocampus and sequences for showing cortical dysplasia, had been used in all children, a higher rate of abnormalities could have been seen similar to the study conducted by Berg et al. which showed a statistically significant higher rate of imaging abnormalities in patients with partial seizure (14). Patient with abnormal EEG had a significantly higher rate of abnormal imaging such as other studies (8,12). Epileptiform EEG activity is one of the most significant factors that increases recurrence of seizure (1,2,4,13,15). Some epileptic syndromes that could be associated with imaging abnormalities are diagnosed by EEG (10). MRI abnormalities are usually associated with an abnormal EEG (16). Patients with recurrent seizure within 24 hours had a slightly increased rate of abnormal imaging that was not significant. In Shinnar's study, recurrence risk of seizure after one unprovoked

seizure was similar to its risk after two unprovoked seizures within 24 hours (8). Camfield, in his study on 490 children with epilepsy, suggested that when a patient had two unprovoked seizure occurring on the same day with recovery between them, these two seizures should propose the diagnosis of epilepsy (17). In evaluation of epileptic children, neuroimaging is mandatory to find the cause. Although some studies recommend brain MRI in children younger than one year (10), we noted that the rate of abnormal imaging was not significantly different in various age groups. In conclusion, most neuroimaging abnormalities found in the children with first unprovoked seizure do not require urgent intervention. However, in a significant proportion of patients, especially those with an abnormal

neurologic examination or abnormal EEG, imaging abnormalities may be seen which influence prognosis and decision for treatment. Our study also showed that even children with a normal neurologic examination may have abnormal imaging. We did not use a similar imaging technique for all of the patients; however, if MRI had been used in all patients, especially in patients with partial seizure, more abnormalities might have been detected.

Acknowledgment

We would like to thank medical record unit of Ali-Asghar Children’s Hospital for their cooperation in reviewing the records of the patients.

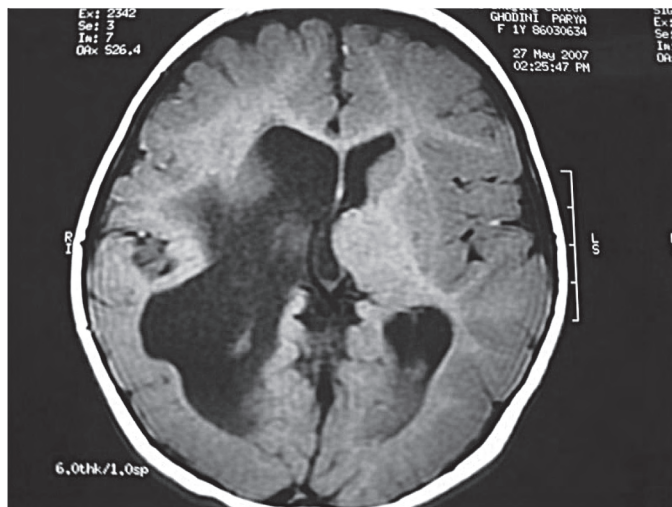


Fig 1. Axial T1 weighted image reveals right porencephalic cyst in 1-year patient with left hemiparesis

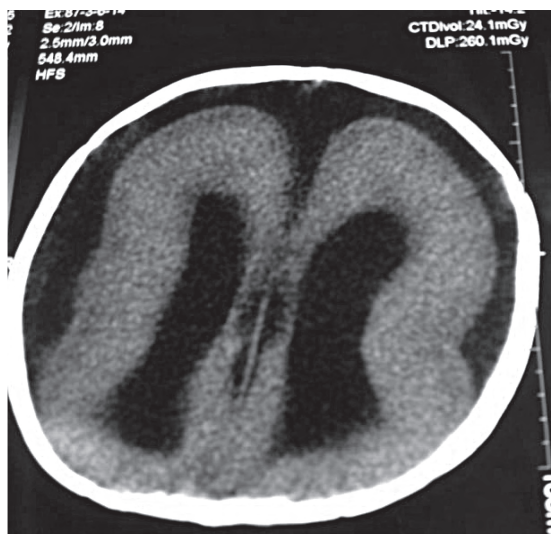

Fig 2. Axial T1 weighted image reveals lissencephaly in a 10-month infant with microcephaly and developmental delay

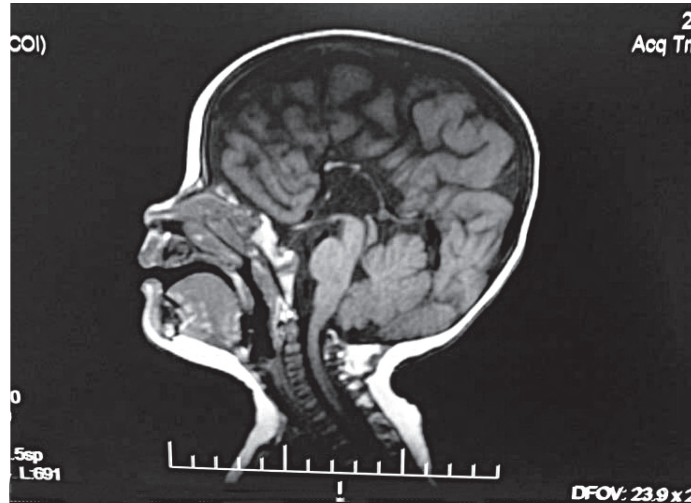

Fig3. Agenesis of corpus callosom in a patient with normal neurologic examination

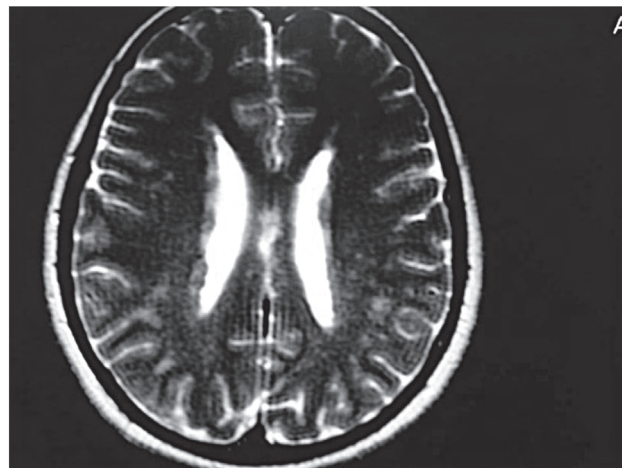


Fig 4. Axial T2 weighted image reveals periventricular subependymal nodularities due to heterotopias in a 12-month infant with developmental delay

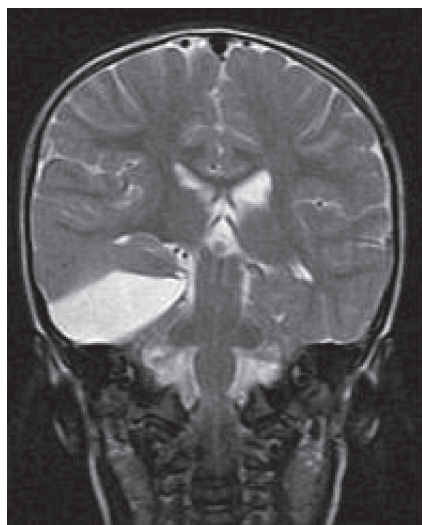


Fig 5. Right temporal arachnoid cyst in a patient with normal neurologic examination

References

1. Seneviratne U. Management of the first seizure: an evidence based approach. *Posgrad Med J* 2004 Dec; 85(1010):667-73.
2. Camfield P, Camfield C. Special consideration for a first seizure in childhood and adolescence. *Epilepsia* 2008; 49(suppl.1): 40-44.
3. Adams SM, Knowles P. Evaluation of a first seizure. *American Family Physician* 2007 May;75(9):1342-4.
4. Wiebe S, Tellez-Zenteno JF, Shapiro M. An evidence-based approach to the first seizure. *Epilepsia* 2008;49(suppl.1): 50-57.
5. Herman ST. Single unprovoked seizures. *Curr Treat Options Neural* 2004;6:243-255.
6. Jallon P, Loiseau P, Loiseau J. Newly diagnosed unprovoked epileptic seizure: presentation at diagnosis in CAROL study. *Epilepsia* 2001;42:464-75.
7. Maytal J, Krauss JM, Novak G. The role of brain computed tomography in evaluating children with new onset of seizures in the emergency department. *Epilepsia* 2000 Aug;41(8):950-4.
8. Shinnar Sh, O'Dell Ch, Mintick R, et al. Neuroimaging abnormalities in children with an apparent first unprovoked seizure. *Epilepsy research* 2001;43:261-264.
9. Hirtz D, Berg A, Bettis D. Practice parameter treatment of the quality standards subcommittee of the American Academy of Neurology. *Neurology* 2003;60:166-175.
10. Hirtz D, Ashwal S, Berg A. Practice parameter: Evaluating a first non febrile seizure in children. *Neurology* 2000;55:616.
11. Mathur Sh, Souther k, Sharma M. Significant findings on cranial CT scan after a first unprovoked seizure in children from north India. *Journal of Tropical Pediatrics* 2007; 53(6):428-430.
12. Aloui-Kasbi N, Azzabi O, Bousetta K. First seizure in children. Exploration strategy. *Tunis Med* 2004 Dec;82(120):1091-6.
13. Gunay M. Neuronal migration disorders presenting with mild clinical symptoms. *Pediatr Neurol.* 1996;14:153-154.
14. Berg AT, Testa FM, Levy SR. Neuroimaging in children with newly diagnosed epilepsy: a community-Based study. *Pediatrics* 2000;106:527-32.
15. Wendorff J. the diagnostic and therapeutic management in the first cerebral attack in childhood. *Przegl Lek* 2007;64(suppl.3):32-7.
16. Hsieh DT, Change T, Tsuchida TN. New-onset afebrile seizures in infants. *Neurology* 2010 Jan;74:150-156.
17. Camfield P, Camfield C. Epilepsy can be diagnosed when the first two seizures occur on the same day. *Epilepsia* 2000;41:1230-1233.