

# Case Report

## A CASE REPORT OF A 2.5-YEAR-OLD GIRL WITH ANGELMAN SYNDROME (AS)

**SALEHI OMRAN**  
**Mohammad Reza MD<sup>1</sup>,**  
**BAKSHANDEH BALI**  
**Mohammad Kazem MD<sup>2</sup>**

1. Associate Professor of Pediatric Neurology, Non-Communicable Pediatric Research Center, Babol University of Medical Sciences, Babol, Iran

2. Pediatrics Resident, Babol University of Medical Sciences, Babol, Iran

Corresponding Author:  
BAKSHANDEH BALI Mohammad  
Kazem MD  
Amir Kola Hospital, Babol, Iran  
Email: mkbakhshandeh@yahoo.com

Received: 04-Nov- 2009  
Last Revised: 01-Feb- 2010  
Accepted: 06-Feb- 2010

### Abstract

#### Objective

Angelman Syndrome (AS) is a genetically determined syndrome that has a unique behavioral phenotype. This syndrome is described as jerky ataxia and an unusual happy facial expression with pathological laughter. Severe mental retardation is a unique feature of the syndrome, together with microbrachycephaly and abnormal electroencephalographic findings with or without clinical seizures. The patients cannot speak or at most, they have a vocabulary consisting only of a few words. The genetic abnormality of AS has been located on chromosome 15q11-q13. Patients with AS mostly have deletions on the maternally derived allele (75–80%) while some of them show paternal uniparental disomy (~2%) or a rare imprinting mutation developmental disorder caused by deletion of the maternally-inherited chromosome 15q11–13. A 2.5-year-old girl is presented. Clinical suspicion of AS was raised at the age of 27 months when she presented with mental retardation and epilepsy, absence of speech, inability to gait and paroxysmal episodes of laughter. Moreover, she had facial dysmorphic features such as microbrachycephaly, mid-facial hypoplasia, macrostomia and a prominent mandible. Chromosomal analysis revealed 46 xx with the deletion of 15q chromosome (15q11q13-snrpn/ic) Our patient met the classical phenotype and genotype of AS.

**Keywords:** Angelman syndrome, microbrachycephaly, Happy facial Phenotype

### Introduction

In 1965, Harry Angelman, an English pediatrician, reported 3 children with a similar pattern of mental retardation, seizures, ataxia, easily provoked laughter, absent speech and dysmorphic facial features (1). He called them “puppet children” because of the superficial resemblance to puppets in view of their flat head, jerky movements, protruding tongue and bouts of laughter.

His observations were confirmed over the next decade by other clinicians, and a pejorative term called “happy puppet syndrome” was introduced, not only referring to their gait but also to their joyous facial expression and fits of inappropriate laughter(2). Williams and Frias proposed the term “Angelman’s syndrome”.

Over 450 AS individuals have now been reported including familial cases. The prevalence of AS is estimated to be around 1/10.000–1/20.000(3,4). AS is a clinical diagnosis that can be confirmed by either cytogenetic or DNA testing in about 80–85% of the cases. Patients with AS have a typical phenotype. Features of AS frequently become apparent at 1–4 years of age, the average age at diagnosis is 6 years and the syndrome is characterized by dysmorphic cranio-facial features (micro-brachycephaly, mid-facial hypoplasia, deep set eyes, macrostomia and prominent mandible), jerky ataxia and an unusual happy facial expression with pathological laughter and Severe mental retardation with or without clinical seizures (5-9).

We report a patient with Angelman syndrome and describe its different features to help our physicians to have a more vivid picture of this condition.

### Case report

The patient, a 2.5-year-old girl, was the first child of healthy first-cousin parents. She was born at term gestation by spontaneous vaginal delivery and weighed normal for gestational age. She had a positive family history of epilepsy and mental retardation in her aunt and her cousin.

Facial features included microcephaly (head circumference: 45.5 cm, below the 3<sup>rd</sup> percentile) with a wide mouth and protruded tongue, as well as mandibular prognathism. She had a happy disposition (already noted in infancy) with paroxysms of laughter (figure 1).

Generalized tonic clonic seizures were presented from the age of 7 days which were treated promptly with phenobarbital. Seizures continued until the anticonvulsant was changed to primidone and clobazam. Concomitant EEG findings were markedly abnormal with generalized spike and poly spike waves. At the time of the diagnosis (age of 27 months), the patient demonstrated a marked neuro-developmental delay with severely impaired communication and lack of any recognizable speech. She was able to sit, but could not walk independently. A performed CT scan at that age was normal. Chromosomal analyses with

karyotype (GTG) and fluorescent in situ hybridization (FISH) techniques revealed 46 xx with deletion of 15q chromosome (15q11q13-snrpn/ic) (Figure 2-3).

### Discussion

Our patient in this study was diagnosed at the age of 27 months with facial features including microcephaly and mental retardation. Other symptoms were absence of speech, inability to gait and paroxysmal episodes of laughter with a wide mouth, a protruded tongue and mandibular prognathism. She had a happy disposition with paroxysms of laughter (10-12).

In other studies, the features of AS frequently become apparent at 1-4 years of age with the average age at diagnosis being 6 years (10-12). The facial features evolve over the first 5 years of life. Typical features include brachycephaly and a head circumference below the 25th percentile (13). A horizontal occipital groove is found in 35% of the patients. The mouth is large, giving rise to widely spaced but otherwise normal teeth.

The chin is pointed and there is mandibular prognathism. The eyes are deep set and often blue. Strabismus is seen in about 40% of the patients (13). Severe visual problems are not common. Coarsening of facial features with increasing age has been reported, with marked mandibular prognathism, a pointed chin, macrostomia and a pronounced lower lip(14-16).

All patients have severe mental retardation and delayed motor milestones. Jerky movements become apparent during the first few months and motor delay is obvious by nine months of age. The jerky movements, tongue thrusting, mouthing, and hand-flapping when walking, are all characteristic. Reflexes are brisk and the gait is slow, ataxic and stiff-legged with the characteristic posture of raised arms with flexed wrists and elbows. Almost all patients are 'happy' and smile frequently. Their laughter is provoked by minimal stimuli and is occasionally inappropriate (13-15).

In this patient, seizure was present from the age of 7 days and was treated promptly with phenobarbital. Seizures continued until the anticonvulsant was changed to primidone and clobazam. Concomitant EEG findings were markedly abnormal with spike and

poly spike generalized waves.

Studies demonstrate that epileptic seizures occur in about 80% of the patients with AS. Age at onset varies from 1 month to 5 years (mean 2–3 years). The initial symptoms of epilepsy are febrile convulsions in infancy in about 40% of the patients (17-18).

In this patient, EEG findings were markedly abnormal with generalized spike and poly spike waves. There are specific EEG patterns in AS patients which may appear in isolation or in various combinations either in the same EEG recordings or at different times in the same patient (18-20).

Computerized tomography (CT scan) findings in two studies were normal or showed cerebral atrophy and ventricular dilatation in a minority of the patients (13-14). One report described an abnormally convoluted surface area of the cortex in the parietal lobe of the Sylvian fissure in the supramarginal gyrus, using specific techniques in MRI (Magnetic Resonance Imaging)(21).

There is no specific therapy for AS patients. Epileptic seizures often need AEDs (Anti Epileptic Drugs) and good results are achieved with Valproic Acid and Clonazepam. Physiotherapy is very important for AS patients to keep them mobile as long as possible and to minimize orthopedic interventions. The use of non-verbal communication is potentially useful for them, but attempts to train the use of signing to augment their speech may be unsuccessful due to their poor imitation skills and possible motor organizational difficulties (22).

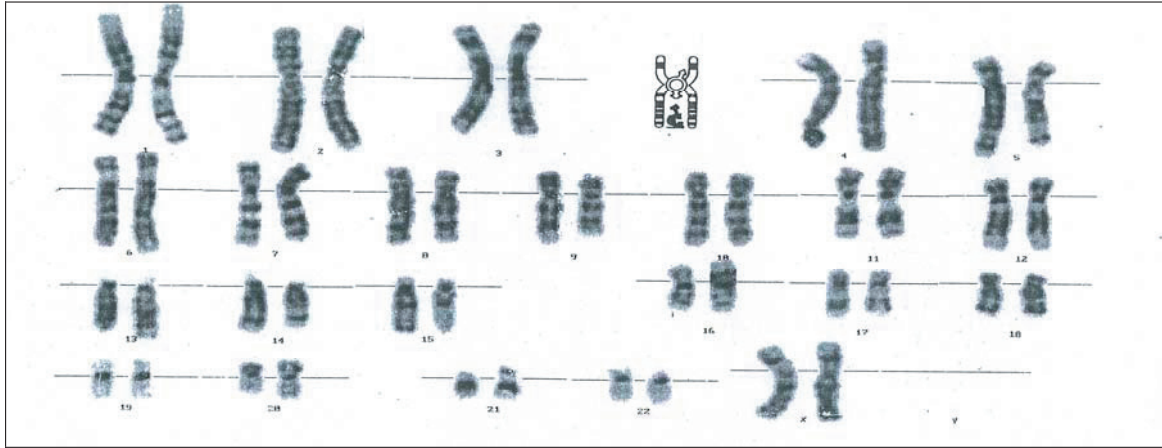
In conclusion, This study demonstrated a typical manifestation of Angelman syndrome with facial features, mental retardation, delayed motor and seizures with EEG findings.

#### Acknowledgment

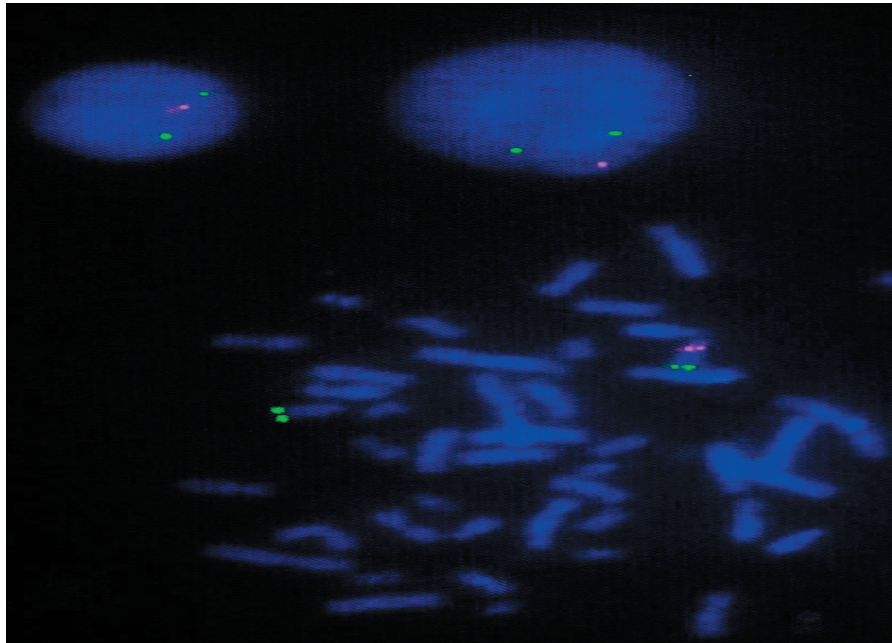
We are grateful to the pathology Center of Dr. Roxana Kariminejad which supported this study.



Fig 1. photos of the presented Case of AS.



**Fig 2.**chromosome study of the patient on the basis of GTG technique: Twenty metaphase spreads were studied on the basis of GTG technique at 450-500 band resolution, revealing 46 chromosomes with possible deletion in long arm of chromosome 15 at q11q13 band.



**Fig 3.**Chromosome study of the patient on the basis of fluorescent in situ hybridization: Fluorescent in situ hybridization was performed on metaphase spreads using the cytotell prader-willi/Angelman (SNRPN/IC)probe. Conclusion:46XX,ish del(15)(q11q13)(SNRPN/IC)Compatible with prader- willi / Angelman syndrome.

References

1. H. Angelman, 'Puppet' children. A report on three cases. *Dev Med Child Neurol* 1965;7:681–688.
2. Bower BD, Jeavons PM. The 'happy puppet' syndrome. *Arch Dis Childhood* 1967;42:298–302.
3. Clayton-Smith J, Laan L. Angelman syndrome: a review of the clinical and genetic aspects. *J Med Genet* 2003;40: 87–95.
4. Petersen MB, Brondom-Nielsen K, Hansen LK, Wulff K. Clinical, cytogenetic, and molecular diagnosis of Angelman syndrome: estimated prevalence rate in a Danish county. *Am J Med Genet* 1995; 60: 261–262.
5. Hou JW, Wang PJ, Wang TR. Angelman syndrome assessed by neurological and molecular cytogenetic investigations. *Pediatr Neurol* 1997;16: 17–22.
6. Lalande M, Minassian BA, DeLorey TM, Olsen RW. Parental imprinting and Angelman syndrome. *Adv Neurol* 1999;79: 421–429.
7. Lossie AC, Whitney MM, Amidon D, Dong HJ, Chen P, Theriaque D, et al. Distinct phenotypes distinguishes the molecular classes of Angelman syndrome. *J Med Genet* 2001;38: 834–845.
8. Mastroianni SD, Kontopoulos E. Split-cord malformation in a girl with Angelman syndrome: a mere coincidence? *Am J Med Genet* 2002;111:57–60.
9. Brockmann K, Böhm R, Bürger J. Exceptionally mild Angelman syndrome phenotype associated with an incomplete imprinting defect. *J Med Genet* 2002;39: e51.
10. Boyd S G, Harden A, Patton M A. The EEG in early diagnosis of the Angelman (happy puppet) syndrome. *Eur J Pediatr* 1988;147: 508–513.
11. Magenis RE, Brown MG, Lacy DA, Budden S, LaFranchi S. Is Angelman syndrome an alternative result of del(15)(q11–13)? *Am J Med Genet* 1987; 28:829–838.
12. Fryburg JS, Breg WR, Lindgren V. Diagnosis of Angelman syndrome in infants. *Am J Med Genet* 1991;38:58–64.
13. Clayton-Smith J, Laan L. Angelman syndrome: a review of the clinical and genetic aspects. *J Med Genet* 2003;40:87–95.
14. Buntinx IM, Hennekam RCM, Brouwer OF, Stroink H, Beuten J, Mangelschots K, Fryns JP. Clinical profile of Angelman syndrome at different ages. *Am J Med Genet* 1995;56:176–183.
15. Laan AEM, Den Boer Ath, Hennekam RCM, Renier WO. , Brouwer OF. Angelman syndrome in adulthood. *Am J Med Genet* 1996;66: 356–360.
16. Sandanam T, Beange H, Robson L, Woolnough B, Buchholz T, Smith A. Manifestations in institutionalised adults with Angelman syndrome due to deletion. *Am J Med Genet* 1997; 70:415–420.
17. Viani F, Romeo A, Viri M, Mastrangelo M, Lalatta F, Selicorni A, et al. Seizure and EEG patterns in Angelman's syndrome. *J Child Neurol* 1995;10:467–471.
18. Laan LAEM, Renier WO, Arts WFM, Buntinx IM, Vd Burgt IJAM, et al. Evolution of epilepsy and EEG findings in Angelman Syndrome. *Epilepsia* 1997;38:195–199.
19. Matsumoto A, Kumagai T, Miura K, Miyazah S, Hayakawa C, Yamanaka T. Epilepsy in Angelman syndrome associated with chromosome 15q deletion. *Epilepsia* 1992;33:1083–1090.
20. Mayo MM, Nelson, HRA Townsend. Three more 'happy puppets'. *Dev Med Child Neurol* 1973;15:63–74.
21. Leonard CM, Williams CA, Nicholls RD, Agee OF, Voeller KKS, Honeyman JC, et al. Angelman and Prader-Willi Syndrome: a magnetic resonance imaging study of differences in cerebral structure. *Am J Med Genet* 1993; 46:26–33.
22. Bürger D, Horn H, Tönnies H, Neitzel A Reis. Familial interstitial 570 kbp deletion of the UBE3A gene region causing Angelman syndrome but not Prader-Willi syndrome. *Am J Med Genet* 2002; 111:233–237.