

CASE REPORT

SEPTO-OPTIC DYSPLASIA WITH AN ANTERIOR ENCEPHALOCELE AND INTACT SEPTUM PELLUCIDUM: A CASE REPORT

Z. Razavi MD

Abstract

Objective

The diagnosis of de Morsier syndrome or septo-optic dysplasia is made on the basis of the diagnosis of optic nerve hypoplasia. Septo-optic dysplasia is defined by a variable combination of dysgenesis of midline brain structures including optic nerve hypoplasia and hypothalamic-pituitary dysfunction often associated with a wide variety of brain malformations of cortical development.

The importance of direct ophthalmoscopy of optic nerve abnormalities is stressed, as well as of magnetic resonance imaging, which has become a guideline in the classification of this syndrome.

This article reports a 19-year-old female with bilateral optic nerve hypoplasia, anterior encephalocele and intact septum pellucidum. She was diagnosed with diabetes insipidus, short stature and the history of seizure.

Keywords: De Morsier syndrome, Septo-optic dysplasia, Encephalocele, Short stature, Optic nerve hypoplasia

Introduction

In 1956, De Morsier (1) demonstrated that optic nerve hypoplasia was frequently associated with absence of the septum pellucidum and he termed this syndrome septo-optic dysplasia. Hoyt and Kaplan (2) reported patients with septo-optic dysplasia and hypopituitarism. After these reports, some authors described this syndrome with varying degrees of hypopituitarism (3). The most recently accepted consists of a variable combination of defects of midline brain structures, including: (1) Hypoplasia or absence of septum pellucidum (but also of corpus callosum); (2) Optic nerve hypoplasia or dysplasia; and (3) Pituitary-hypothalamic dysfunction (ranging from isolated deficit of pituitary hormones to pan-hypopituitarism) (4). Septo-optic dysplasia has been reported with encephalocele in a few articles (5). Here we report a patient, with septo-optic dysplasia and encephalocele, who presented initially with amenorrhea and short stature.

Case Report

A 19-year-old girl with an unremarkable birth history was referred to our endocrinology clinic with amenorrhea and short stature. She suffered from severe vision loss and pendular nystagmus due to bilateral optic nerve hypoplasia. Her parents were cousins with four younger healthy children. While pregnant with her, the mother experienced an uneventful pregnancy; no similar finding was observed in her first degree relatives. From the age of two, she complained of polydipsia and polyuria, for which no medical help had been sought. She had also reported

Associate Professor, Pediatric
Endocrinologist, Hamedan
University of Medical Sciences

Corresponding Author:

Z. Razavi MD

Ekbatan Hospital

Tel: +98 811 2520454

Email: razavizahra@yahoo.com.au

an episode of tonic-clonic seizure at the age of 13, with no recurrences. The patient had not used any medication except for during amenorrhea and had no history of head trauma or anosmia.

On physical examination, the girl was found to be responsive and have a normal intelligence quotient (IQ), but she had prominent short stature. She had 140 cm height (4.5 scores below the mean of standard deviation) and 45.5 kg weight (fifth percentile). Based on the Tanner classification, pubertal development in breast and genitalia were in the 4th stage and were normal.

Ophthalmologic examination revealed that visual acuity was 60/200 in both eyes; pupils were equal and did not reveal any relative afferent papillary defect. Extraocular motility was full. There was conjugate, horizontal pendular nystagmus. Indirect ophthalmoscopy revealed bilateral optic nerve hypoplasia. Chest, cardiac and abdominal examinations were normal.

Ultrasonographic evaluations of the ovaries, uterus and related appendices were normal except for a follicular ovary. Magnetic resonance imaging of the brain disclosed bilateral hypoplasia of the anterior visual pathways and chiasm. The septum pellucidum was intact. A huge anterior encephalocele were seen in the sphenothmoidal region (figure 1). We also encountered empty sella (figure 2).

Urine specific gravity was 1.005 and increased to 1.008 by water deprivation test but responded eventually to

the vasopressin test. Blood sugar, prolactin, kidney, liver and thyroid function tests were within the normal ranges. Also baseline and stimulated cortisol values were normal; LH, FSH and estradiol were 6.9 IU/L, 2.9 IU/L and 4.2 pg/ml respectively. Growth hormone stimulation test showed no response to clonidin (all values were over 10 ng/ml).

Finally, based on the MRI and ophthalmologic findings, diabetes insipidus, short stature and the history of seizure, a diagnosis of Septo-optic dysplasia was confirmed.

Discussion

Septo-optic dysplasia refers to a heterogeneous group of disorders that may include optic nerve and/or optic chiasma hypoplasia and the absence, or dysgenesis, of the septum pellucidum. The clinical features may include partial pituitary insufficiency (from panhypopituitarism to isolated GH, ACTH or ADH insufficiency), various degrees of psychomotor retardation, mild to severe visual impairment, thermoregulatory disturbances, conjugated hyperbilirubinemia and seizures (6).

The pathogenesis of septo-optic dysplasia is not yet fully understood. Two primary factors have been proposed, a genetic factor and alteration of intrauterine environment (7). Genetic factors include young maternal age, of which increased incidence is seen in first-born children and familial occurrences (8). Also mutations in HESX1 have been implicated in cases of septo-optic dysplasia

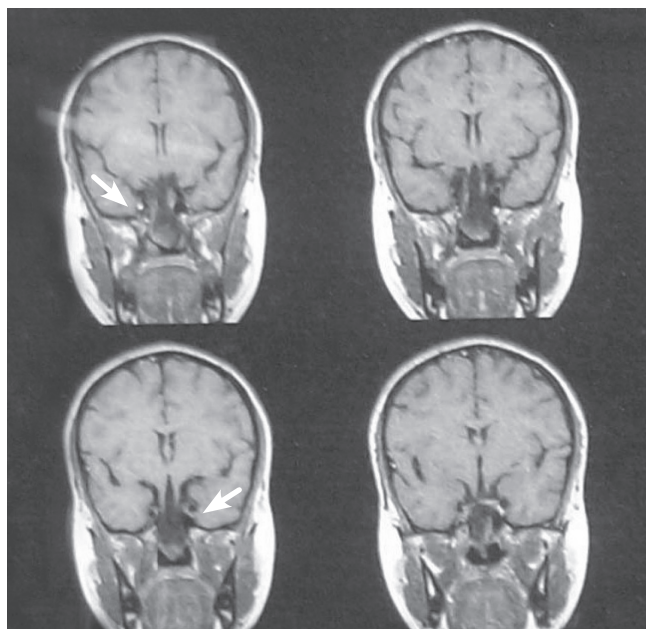


Figure 1. Anterior encephalocele in the sphenothmoidal region

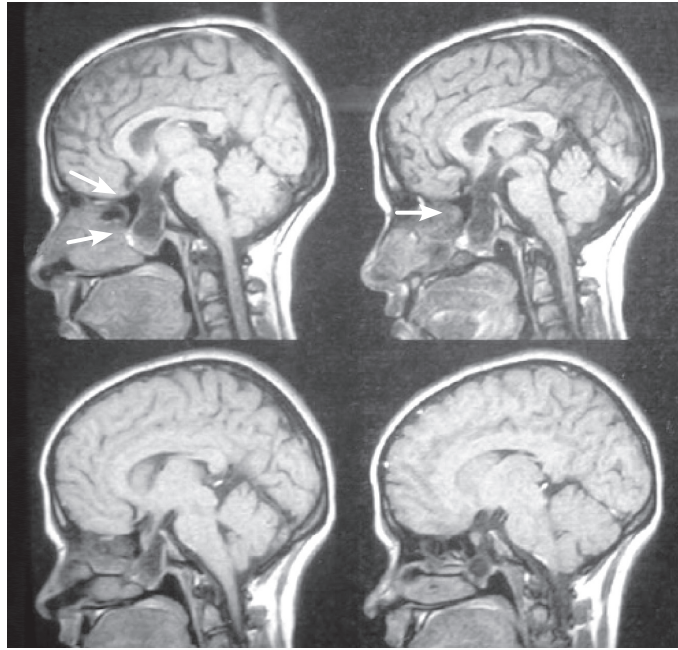


Figure 2. Empty sella with lateral view of anterior encephalocele

and congenital hypopituitarism (9).

Alteration of intrauterine environment, as the second contributing factor, has been suggested from the based on the increasing incidence of maternal drug use and maternal diabetes. Recently Stevens argued that the limb features in this group of patients represent amniotic band disruption, a hypothesis with which the clinical findings are entirely consistent (10). These factors were not detected in our patient except those of the first born child and the young age of her mother.

Malformations of this syndrome are believed to be attributable to an aberration during the early stages of development. At 4-6 weeks of gestation the lamina terminalis thickens and the optic and telencephalic vesicles begin to expand from the prosencephalon. From the dorsal part of the lamina terminalis, the lamina reuniens, and the septum pellucidum appears at 18 weeks. The corpus callosum appears at 10 weeks from the anterior part of lamina terminalis. The malformation associated with this syndrome develops from the pathologic differentiation during these periods. Optic nerve hypoplasia often is complicated by central nervous system malformations, especially with those of the midline structures of the forebrain. Based on these facts and a similar developmental stage of aberration, septo-optic dysplasia is considered to be a mild type of holoprosencephaly (11).

Regarding the diagnostic imaging of this condition, the most important is the examination of the optic nerves (12); in our patient, ophthalmoscopy revealed bilateral optic nerve hypoplasia; also the septum pellucidum was detected by MRI, as has also been reported by Kuriyama and Cameron (13,14). Also a huge anterior encephalocele were seen in the sphenothmoidal region. Occurrences of encephalocele have been reported by some authors; Sami (5) and Cartmill (15) reported patients with skull base associated encephalocele and agenesis of the corpus callosum.

Our patient reported an episode of epilepsy, documented also by Patel (16), who reported several patients with septo-optic dysplasia and epilepsy; Kuriyama (13) also reported a patient with this syndrome who had an infantile spasms.

The present study also found endocrinological deficiencies; Skarf reported that 41% of children with bilateral optic nerve hypoplasia and poor vision had endocrinological deficiencies (17), while Siatkowski reported endocrinological abnormalities in only 27% of 35 children with bilateral optic nerve hypoplasia and 34% had no light perception (18).

A psychiatric evaluation of our patient revealed that our patient was healthy and had normal cognitive functions; our findings are similar to those of Margalith et al., who reported that 27% of their 51 optic nerve

hypoplasia children were healthy, without associated neuropsychiatric handicaps (19).

In the present study, we found no motor impairment (movement disorders or muscular hypotonia) while other studies have reported frequencies of movement disorders ranging from 9% to 57% (19); however the importance of these comparisons is limited because of the small numbers of children involved.

In any child with endocrinopathy, unexplained seizure or failure to thrive, and ocular findings such as nystagmus or poor visual behavior in particular, septo-optic dysplasia should be considered in differential diagnosis. Prompt ophthalmological and endocrine consultation and MRI imaging are mandatory for establishing the extent of hypothalamic-pituitary axis abnormalities, and minimizing morbidity.

In conclusion, in this patient with bilateral optic nerve hypoplasia, hypopituitarism, empty sella and encephalocele the diagnosis is most likely that of septo-optic dysplasia, although the wide variation in clinical expression can make diagnosis difficult. Direct ophthalmoscopy is essential in the diagnosis of septo-optic dysplasia, which in this patient gave a clue to the diagnosis.

Reference

1. De Morsier G. Etudes sur les dystrophies cranieoencephaliques III. Agenesie du septum lucidum avec malformation du tractus optique: La dysplasie septo-optique. *Schweiz Arch Neurol Neurochir Psychiatr* 1956; 77:267-92.
2. Hoyt WF, Kaplan SL, Grumbach MM, Glaser JS. Septo-optic dysplasia and pituitary dwarfism. *Lancet* 1970; 1:893-4.
3. Barkovich AJ. Congenital malformations of the brain and skull. In: Barkovich AJ, editors. *Pediatric neuroimaging*. 4th ed. Philadelphia: Lippincott Williams & Wilkins; 2005. P.291-439.
4. Polizzi A, Pavone P, Iannetti P, Manfre L, Ruggieri M. Septo-optic dysplasia complex: a heterogeneous malformation syndrome. *Pediatr Neurol* 2006; 34:66-71.
5. DA Sami, D Saunders, DA Thompson, IM Russell-Eggitt, KK Nischal, G Jeffrey, et al. The achiasmia spectrum: congenitally reduced chiasmal decussation. *Br J Ophthalmol* 2005 Oct; 89:1311-7.
6. Miller SP, Shevell MI, Patenaude Y, Poulin C, O'Gorman A M. Septo-optic dysplasia plus: spectrum of malformations of cortical development. *Neurology* 2000; 54:1701-1703.
7. Polizzi A, Pavone P, Iannetti P, Manfre L, Ruggieri M. Septo-optic dysplasia complex: a heterogeneous malformation syndrome. *Pediatr Neurol* 2006; 34:66-71.
8. Murray PG, Paterson WF, Donaldson MD. Maternal age in patients with septo-optic dysplasia. *J Pediatr Endocrinol Metab* 2005; 18:471-6.
9. Cohen RN, Cohen LE, Botero D, u C, Sagar A, Jurkiewicz M, et al. Enhanced repression by HESX1 as a cause of hypopituitarism and septo-optic dysplasia. *J Clin Endocrinol Metab* 2003; 88:4832-9.
10. Stevens CA, Dobyns WB. Septo-optic dysplasia and amniotic bands: Further evidence for a vascular pathogenesis. *Am J Med Genet* 2004; 125A: 12-16.
11. Camino R, Arjona A. Septo-optic dysplasia plus. *Lancet Neurol* 2003; 2:436.
12. Hellstrom A, Wiklund LM, Svensson E. The clinical and morphologic spectrum of optic nerve hypoplasia. *J AAPOS* 1999; 3:212-20.
13. Kuriyama M, Shigematsu Y, Konishi K, Konishi Y, Sudo M, Haruki S, Ito H. Septo-optic dysplasia with infantile spasms. *Pediatr Neurol* 1988 Jan-Feb; 4(1):62-5.
14. Cameron FJ, Khadilkar VV, Stanhope R. Pituitary dysfunction, morbidity and mortality with congenital midline malformation of the cerebrum. *Eur J Pediatr* 1999; 158:97-102.
15. Cartmill M, Jaspán T, McConachie N, Vloeberghs M. Neuroendoscopic third ventriculostomy in dysmorphic brains. *Childs Nerv Syst* 2001; 17:391-4.
16. Patel H, Tze WJ, Crichton JU, McCormick AQ, Robinson GC, Dolman CL. Optic nerve hypoplasia with hypopituitarism: Septo-optic dysplasia with hypopituitarism. *Am J Dis Child* 1975; 129:175-80.
17. Skarf B, Hoyt CS. Optic nerve hypoplasia in children. Association with anomalies of the endocrine and CNS. *Arch Ophthalmol* 1984; 102:62-7.
18. Siatkowski RM, Sanchez JC, Andrade R, Alvarez A. The clinical, neuroradiographic, and endocrinologic profile of patients with bilateral optic nerve hypoplasia. *Ophthalmology* 1997; 104: 493-6.
19. Margalith D, Jan JE, McCormick AQ, Tze WJ, Lapointe J. Clinical spectrum of congenital optic nerve hypoplasia: review of 51 patients. *Dev Med Child Neurol* 1984; 26: 311-22.