










## Guided Endodontics in Complex Scenarios of Calcified Molars

Warley Luciano Fonseca Tavares<sup>a\*</sup> , Vinícius de Carvalho Machado<sup>a</sup> , Francielen Oliveira Fonseca<sup>a</sup> ,  
Betânia Canal Vasconcellos<sup>a</sup> , Luiza Cruz Guimarães<sup>a</sup> , Ana Cecília Diniz Viana<sup>a</sup> , Luiz Carlos  
Feitosa Henriques<sup>a</sup> 

<sup>a</sup> Department of Restorative Dentistry, Faculty of Dentistry, Universidade Federal de Minas Gerais, Belo Horizonte, MG, Brazil

### ARTICLE INFO

Article Type: Case Report

Received: 12 Aug 2019

Revised: 09 Oct 2019

Accepted: 23 Oct 2019

Doi: 10.22037/iej.v15i1.26709

\*Corresponding author: Warley Luciano Fonseca Tavares, Universidade Federal de Minas Gerais, Av. Antônio Carlos 6627, Campus Pampulha, Belo Horizonte, MG, 31270-901, Brazil. Tel: +55-31 34092843  
E-mail: warleyt@hotmail.com

This work is licensed under the terms of the Creative Commons Attribution-NonCommercial-ShareAlike 4.0 International.

### ABSTRACT

This study aimed to report a case series and describe the use of guided endodontics in complex symptomatic cases of mandibular and maxillary molars; presenting calcification of all three root canals. The arches of the referred patients were scanned, and high-resolution cone-beam computed tomography (CBCT) imaging was performed. Then, the taken CBCT and tooth scans were aligned and processed using software. A virtual copy of a drill was superimposed onto the scans and evaluated in 3 dimensions. Subsequently, a 3-dimensional (3D) template was designed and printed. Drilling was performed and a radiograph was taken to confirm its position. The canals were reached and endodontic treatment was performed. At the 12-month follow-up, the teeth were completely asymptomatic. The use of guided endodontics in cases of calcification in molars was demonstrated to be a viable and reliable alternative treatment. The technique was based on 3D planning.

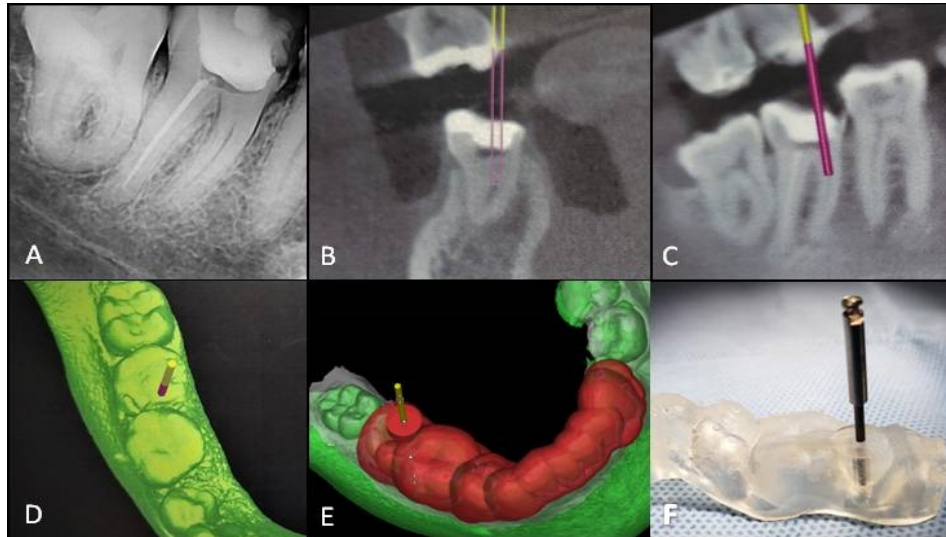
Keywords: Apical Periodontitis; Cone Beam Computed Tomography; Dental Pulp Calcification; Dental Trauma; Guided Endodontics.

### Introduction

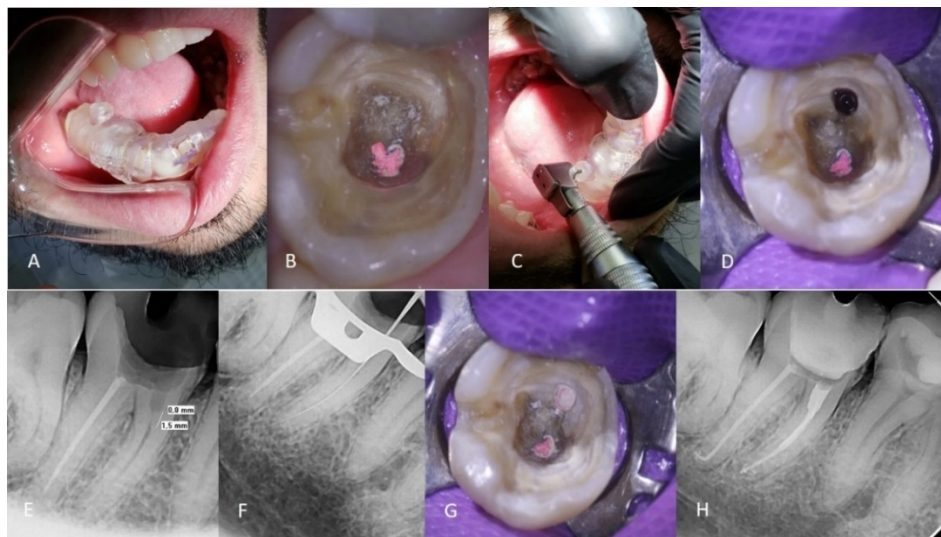
The goals of endodontic treatment may not be achieved in cases of partial or total obliteration of pulp spaces. It is believed that when pulp canal calcification is present, endodontic treatment is only indicated where apical periodontitis is present or pulp symptoms occur [1, 2]. Although many approaches to treat calcified canals have been described, even the most experienced endodontists can face difficulties in reaching patency and performing the proper cleaning and shaping [3-6].

In cases of pulp canal calcification in posterior teeth, the clinical difficulties associated with reaching and using an instrument on the canals are even more pronounced. Limited opening of the mouth and lack of visibility, as well as the thinner dentin walls of the posterior teeth, result in high risk of root perforation. The inclination of the teeth and the presence of root curvature make the localization of calcified canals in molars a risky procedure [7-10].

Recently, "Guided Endodontics (GE)" has been described as an alternative method for the treatment of calcified canals [11-13]. The use of computed aid implantology (CAI) software (Simplant; Materialise Dental, Leuven, Belgium) combined with cone-beam computed tomographic (CBCT) imaging and digital impression 3-dimensional (3D) scanning allows virtual planning of the canal access cavity [14, 15]. Subsequently, a 3D template can be produced and used to guide a drill into the calcified root canal. This technique has been described as a conservative approach without the removal of the incisal edge, and is being considered for use in anterior teeth [16, 17]. Although GE has been investigated in calcified anterior teeth, its application in cases involving obliterated canals of molars has not been well explored. To date, only two studies have described the application of GE in maxillary premolars and maxillary molars presenting calcification in one of the roots [9, 10].



**Figure 1.** Case 1 A) Presence of calcification in the mesial root; B-E) Planning of the drill position and template building; F) 3D template and 1.3-mm drill



**Figure 2.** Case 1 A) Evaluation of the template fit in the mouth; B) Clinical aspect. Note the false orifices created in an attempt to reach the mesial canals; C) Targeted drilling; D) Clinical aspect after initial dentine drilling; E) Radiographic evaluation of wearing; F) Radiographic determination of working length; G) Clinical aspect of root canal obturation; H) Final Radiograph

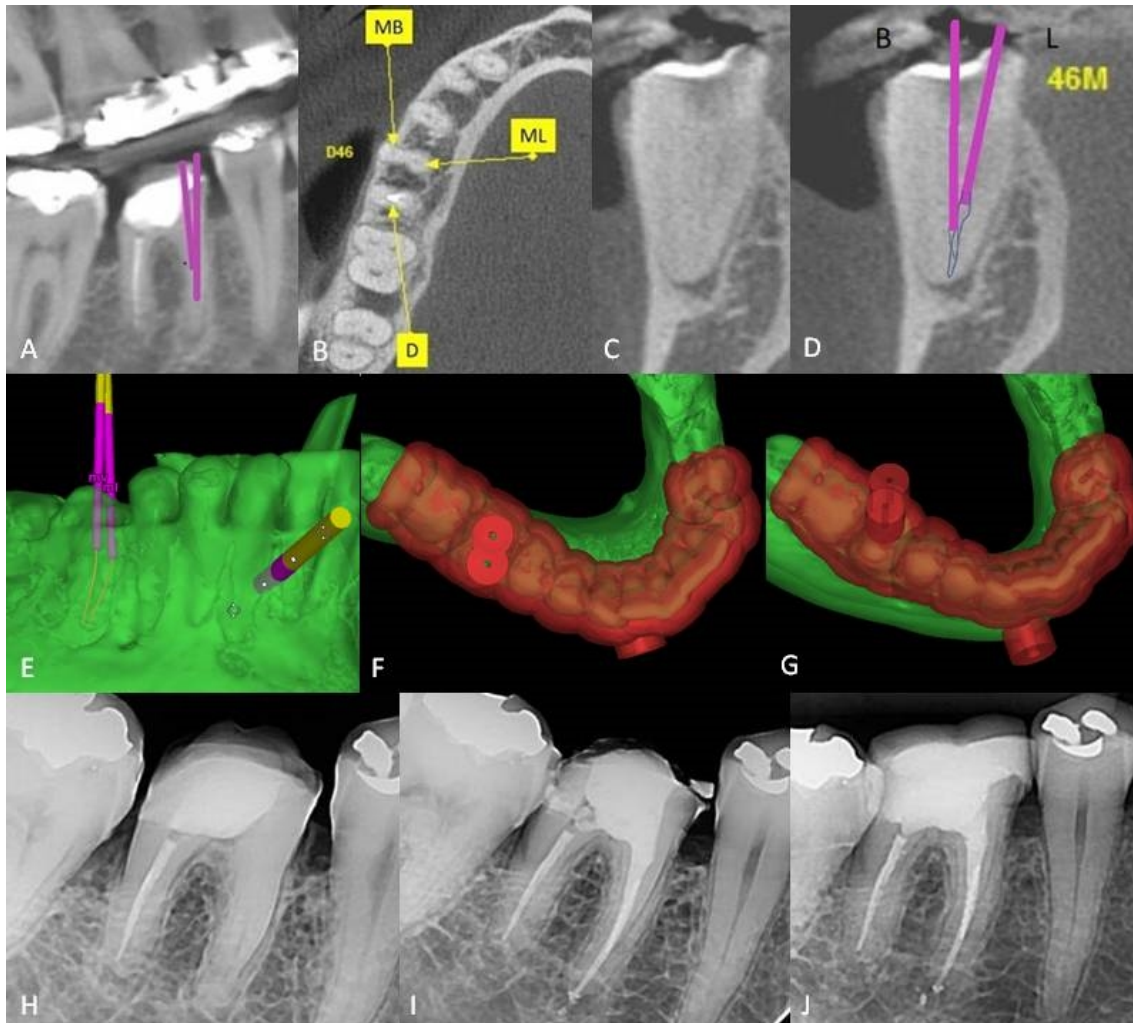
The aim of this case series is to report and describe the use of GE in complex symptomatic cases of two mandibular molars, and one case of a maxillary molar which presented canal calcification of all three root canals.

## Case Reports

### Case 1

A 33-year-old male patient with a history of pain in the mandibular right second molar was referred to a private clinic. The medical history of the patient revealed absence of any systemic disorders, allergies or use of medications. The distal

root of the tooth was endodontically treated, while in clinical examinations, the mesial root presented partially calcified canals. Another professional had tried unsuccessfully to access the mesial root canals, which had led to the creation of false entrance orifices. The presence of canal calcification was confirmed by CBCT scan. Furthermore, in the axial slices by CBCT, a single root canal was identified in the apical third of the mesial root. The patient was a professional judo athlete, and the toothache had limited his sports activities. After orientation and discussion with the patient, GE was chosen as the most appropriate treatment. The patient signed an agreement consent.



**Figure 3.** Case 2. A) Digital planning of the drilling direction; B-E) Mesial canals with a common apical foramen; F-G) 3D template design. H) Pre-operative radiography; I) Immediate post-operative Radiography. J. One-year follow-up

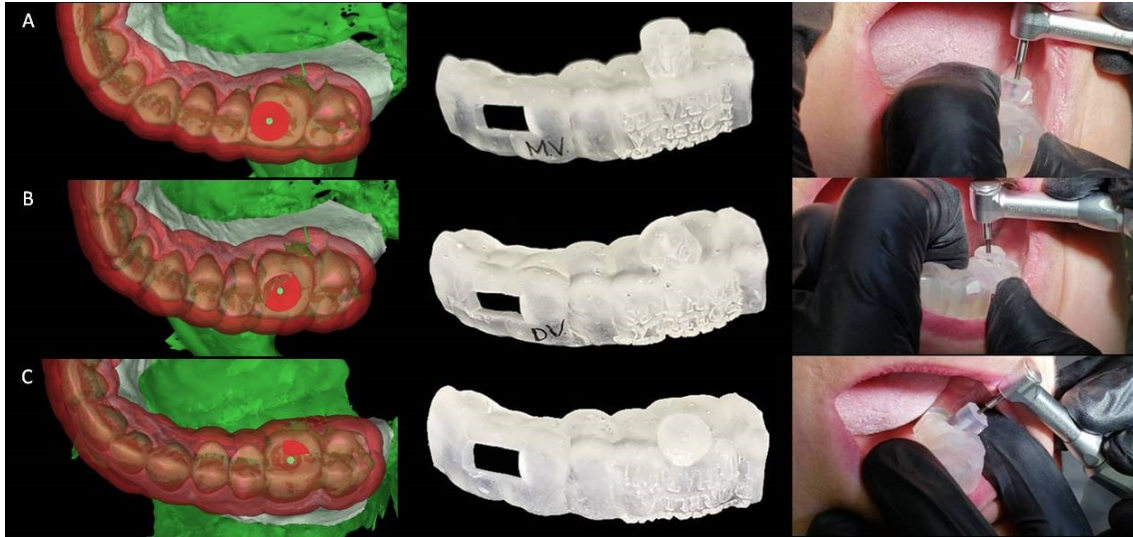
### Building the endodontic 3D Guide

The whole arch was scanned (3 Shape Trios 3-Color Intraoral Scanner; Holmens Kanal, Copenhagen, Denmark). High-resolution CBCT imaging was performed using the following settings: 0.2-mm voxel, grey scale, 14 bits, 26.9-sec X-ray exposure, 120 kV, and 37 mA (iCAT; Imaging Sciences International, Hatfield, PA, USA). A plastic lip retractor was used for CBCT imaging as described by Januario *et al.* [18] to permit a more detailed view of the dentogingival unit. Following imaging, the CBCT and tooth scans were aligned and processed using SimPlant (Version 11; Materialise Dental, Leuven, Belgium). A virtual copy of a drill with a diameter of 1.3 mm and a length of 20 mm (Neodent Drill for Temp Implants, Ref: 103179; JJGC Ind e Comércio de Materiais Dentarios SA, Curitiba, Brazil) was superimposed onto the scans in a position that allowed the drill to have access to the identified root canals. The position of the drill was confirmed in 3 dimensions. Subsequently, the 3D template

was exported as an Stereolithography file and sent to a 3D printer (Formlabs2, Formlab Inc., 35 Medford St. Suite 201, Somerville, MA 02143, USA) (Figure 1).

### Clinical procedures

The procedure was performed under local anaesthesia. The printed 3D template was positioned in the mouth and evaluated for proper placement. A driver located in the guide was precisely positioned on the access cavity to allow stabilization of the selected drill; which was coupled to an endodontic motor set at 900 rpm and 4 N torque. The driver was lubricated with Vaseline™, so that excessive attrition with the drill could be avoided. The procedure was performed under copious irrigation with saline. Drilling was performed using a pumping motion, and after each 2-mm apical advancement of the instrument, a radiograph was taken and used to confirm the correct position of the drill. After reaching the patent canal, the tooth was



**Figure 4.** Case 3. Evaluation of the 3D templates built for each canal A) Mesio-Buccal; B) Disto-Buccal; C) Palatine

isolated with a rubber dam. A #10 K-file was introduced to the canal, and the root canal length was electronically (Root Z X2; J Morita Mfg. Corp., Fushimi-ku, Kyoto, Japan) and radiographically determined and confirmed (Figure 2).

The root canal shaping was performed using 30/0.01 and 30/0.05 rotary NiTi Logic System (Easy Equipamentos Odontológicos, Belo Horizonte, MG, Brazil). The canal was copiously irrigated with 2.5% sodium hypochlorite during instrumentation. After rinsing the canal with 17% ethylenediaminetetraacetic (EDTA) for 1 min, a final irrigation with sodium hypochlorite agitated with Easy Clean (Easy Equipamentos Odontológicos, Belo Horizonte, MG, Brazil) at 20000 rpm for 60 sec (3×20 sec) was performed. After drying the root canal, obturation was performed using gutta-percha and bioceramic sealer (Bio-C Sealer, Angelus, Londrina, Brazil), and condensed with Tagger's hybrid technique. [5, 19] In another appointment, the distal canal was promptly retreated. The access cavity was cleaned and sealed with zinc oxide eugenol cement. The patient was referred for final restoration, and at the 15-day, and 12-month follow-ups, the tooth was found to be completely asymptomatic.

#### Case 2

A 45-year-old female patient presented with pain in the first right mandibular molar. Previous attempts were made to perform root canal treatment; however, having thorough access to the mesial root canals was unsuccessful due to the calcification of the canal orifices. Radiographically, calcification of the mesial roots could be observed.

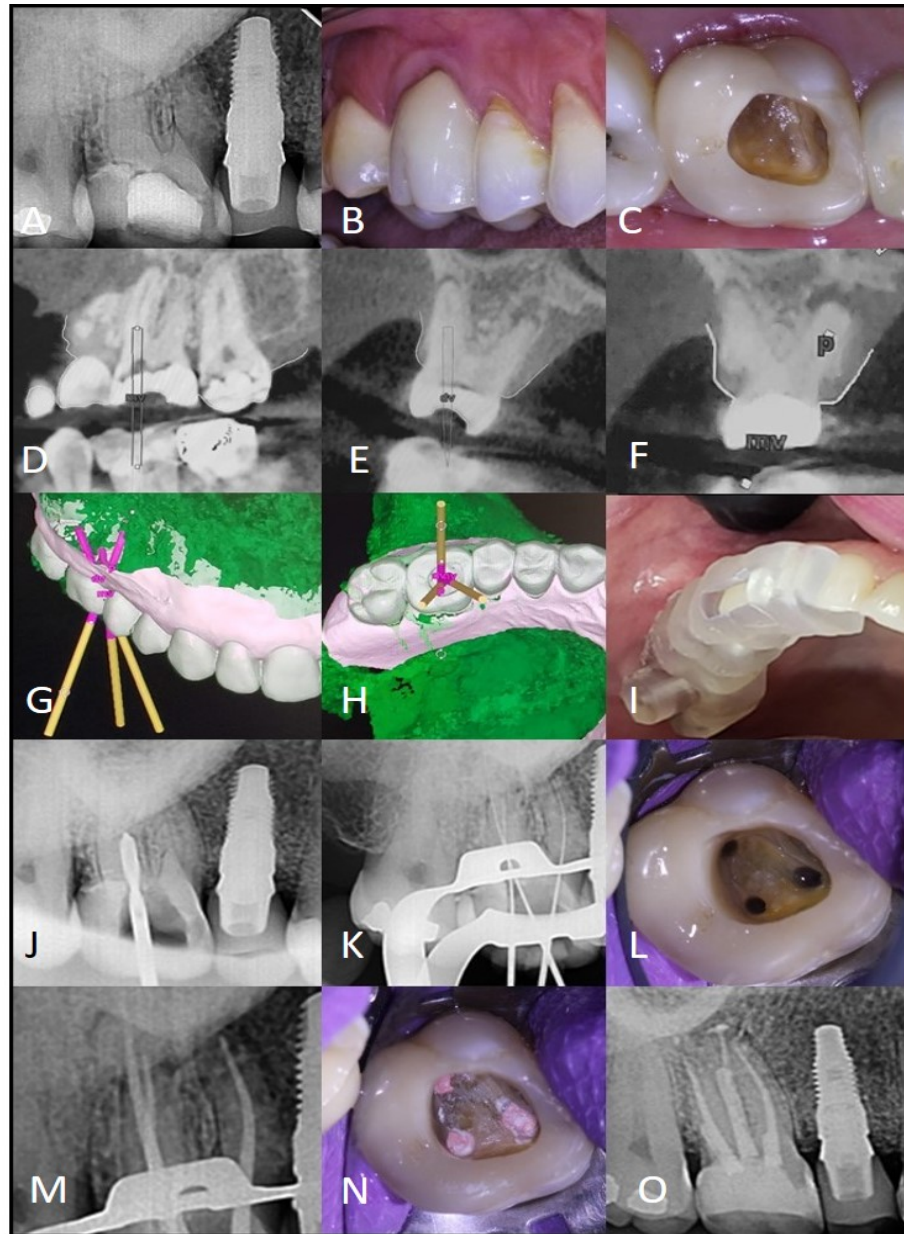
The medical history of the patient revealed absence of any systemic disorders, allergies or use of medications but she

suffered from dental phobia, and thus, it was necessary to perform the treatment under sedation. In this case, because prolonged and multiple visits had to be minimised, GE was considered as the most appropriate solution. The patient was informed about the benefits of GE and agreed to the proposed treatment. Then, the patient was referred for tooth scanning and CBCT examination, which confirmed the presence of canal calcification. However, the canals converged to a single foramen, and root canal space was evident in the middle and apical thirds of the root (Figure 3). The printed 3D template was evaluated in the mouth, and the patient was scheduled for a treatment session under sedation. The patient signed an agreement consent.

Access to of the calcified canals was performed as described in case 1. A #8 K-file was introduced, and the obtained patency was electronically confirmed. The canals were instrumented using 20/0.01, 20/0.04, and 20/0.06 rotary NiTi Logic System (Easy Equipamentos Odontológicos, Belo Horizonte, MG, Brazil). The irrigation protocol was identical to that of case 1. After drying the root canals, obturation was performed with gutta percha and AH-Plus Sealer (Dentsply DeTrey GmbH, Konstanz, Germany) using Tagger's hybrid technique [5, 19].

#### Case 3

A 42-year-old female patient was referred for endodontic treatment of the first right maxillary molar. The medical history of the patient revealed absence of any systemic disorders, allergies or use of medications. The patient presented acute apical periodontitis. In the radiographic examination, complete obliteration of all the canals was observed. An initial attempt to access the orifices of the canals with the use of an endodontic microscope operated by an experienced endodontist was



**Figure 5.** Case 3. A-C) Radiographic and clinical aspects of root canal obliteration; D-H) Digital planning of guided endodontics; I) Evaluation of the 3D template in the mouth; J) Drilling of the palatine canal; K. Radiographic determination of working length; L) Clinical aspect after root canals instrumentation; M) Evaluation of the master cones; N) Root canal obturation; O) One-month follow-up.

unsuccessful. As the CBCT exam confirmed the calcification of the canals to the apical third, GE was proposed. The patient signed an agreement consent.

The maxillary arch was scanned as previously described. In this particular case, it was necessary to build 3 different templates, one designed for each canal. After evaluating the fit of the 3D guides in the mouth, the procedure was implemented and executed separately for each canal (Figure 4). The approach, to reach the individual patent canals at the apical third, was the same as

described in the previous cases. After determination of the working lengths with a #10 and then #15 K-file, the canals were instrumented using a 30.05 rotary NiTi Logic System (Easy Equipamentos Odontológicos, Belo Horizonte, MG, Brazil) under copious irrigation with 2.5% sodium hypochlorite. After rinsing the canals with 17% EDTA, final irrigation with sodium hypochlorite was agitated as previously described. The canals were dressed with calcium hydroxide (Ultracal, Ultradent; South Jordan, UT, USA) for 10 days, and the tooth was sealed using glass ionomer.

In a second appointment, calcium hydroxide was removed under irrigation with sodium hypochlorite. Then, EDTA was applied using the auxilium of Easy Clean at 20,000 rpm. The canals were obturated with gutta-percha and bioceramic sealer (Bio-C Sealer, Ângelus, Londrina, Brazil) using Tagger's hybrid technique [5, 19]. The tooth was restored with composite resin, and at 1-week and 12-month follow-ups, the patient was completely asymptomatic (Figure 5).

## Discussion

There are many clinical difficulties associated with the treatment of calcified posterior teeth. The narrow structure of dentine and the constriction/curvature of canals in the middle and apical thirds of the roots are the most significant [9, 10]. Together, these factors may culminate in iatrogenic errors during efforts to achieve patent canals. In the cases presented in this study, the use of GE managed to minimise such challenging factors.

To date GE has demonstrated itself to be very effective in cases of calcified anterior teeth [13,16]. More recently, two studies have demonstrated its use in maxillary premolars and molars; presenting a single calcified canal [9, 10]. To the best of our knowledge, this is the first time that the use of GE in mandibular molars has been reported. In comparison with the GE used for anterior teeth, GE in mandibular molars has many differences. The lack of vision, restricted mouth opening and inherent difficulties associated with the treatment of posterior teeth reinforce the indication for application of 3D guidance [9, 10]. The use of a shorter bur in the initial drilling helps overcome the limitation of mouth opening. Another important factor is the inclination of the roots associated with the thin dentinal structure of mesial roots. The risk of perforation in this region is more pronounced when the operator is working blindly. Even highly experienced clinicians, working with the operating microscope, would face difficulty in accessing the canals in this clinical situation. In all 3 cases presented here, the planned position of the drill in the designated 3D template allowed precise removal of the dentine and achievement of the lumen of the canals as planned virtually. Following this step, the canals could be promptly and sufficiently instrumented.

Although the patient is exposed to radiation during CBCT, the total exposure is lower than that received during conventional treatments of calcified teeth. This is mainly because it is not necessary to take several radiographs to confirm the position of the instrument used to achieve the canal [5]. In case 2 in particular, this was very relevant to the success of the

treatment. Because the patient was under sedation, obtaining several radiographs would be laborious. In fact, the patient's time in the chair was considerably reduced in this approach. The whole procedure could be performed fastidiously, thereby avoiding another session requiring sedation, since the presence of an anaesthetist was necessary in this especial case.

In case 3, the use of GE was paramount for successful treatment. For the first time, the application of GE was described in a case of a maxillary molar with calcification of all three canals. Without 3D guidance, the procedure would require several sessions, and the case could present limited prognosis, even with the use of an endodontic microscope operated by an experienced endodontist. In such cases, the presence of narrow dentinal walls does not permit any slight error during the process of dentinal wear. In point of fact, the effectiveness of GE was verified in this challenging scenario. The treatment was expeditiously achieved, which was essentially necessary due to the acute symptoms presented by the patient. The complete procedure of reaching and instrumenting the canals required a session of approximately one hour. After CBCT and oral scanning, a few hours were also required to plan the case, and on the following business day, the patient received treatment, thereby avoiding the indiscriminate use of drugs and tooth loss. Interestingly, the technologies utilized in GE \_including dental equipments, tomography, software and 3D printing\_ do not limit the applicability of this treatment since this technologies are accessible worldwide.

Although the diameter of the bur (1.3 mm) could be considered a limitation of the technique, it permitted proper dentine removal without any deviation or iatrogenic error. In this respect, our group is currently working on the development of new instruments that are specifically designed for use in cases involving thinner dentinal walls. It is speculated that GE can be used not only in cases involving calcified teeth but in anatomically complex and difficult-to-reach cases.

The use of GE in cases involving complex scenarios of calcification in molars was shown to be a viable and reliable treatment alternative. The reported cases were treated expeditiously without any risk of perforation. The execution of the technique followed a 3D planning.

## Conclusion

Our case cerise study revealed the use of guided endodontics in cases of calcification in molars could be a viable and reliable alternative treatment.

## Acknowledgement

The authors would like to thank the postgraduate program at the “School of Dentistry”, Universidade Federal de Minas Gerais (UFMG) and Pró- Reitoria de Pesquisa da UFMG (PRPq). The authors also deny any conflict of interest related to this study.

Conflict of Interest: ‘None declared’.

## References

- Andreasen FM, Zhijie Y, Thomsen BL, Andersen PK. Occurrence of pulp canal obliteration after luxation injuries in the permanent dentition. *Endod Dent Traumatol.* 1987;3(3):103-15.
- Oginni AO, Adekoya-Sofowora CA, Kolawole KA. Evaluation of radiographs, clinical signs and symptoms associated with pulp canal obliteration: an aid to treatment decision. *Dent Traumatol.* 2009;25(6):620-5.
- Holcomb JB, Gregory WB, Jr. Calcific metamorphosis of the pulp: its incidence and treatment. *Oral Surg Oral Med Oral Pathol.* 1967;24(6):825-30.
- McCabe PS, Dummer PM. Pulp canal obliteration: an endodontic diagnosis and treatment challenge. *Int Endod J.* 2012;45(2):177-97.
- Tavares W, Lopes R, Menezes G, Henriques L, Ribeiro A. Non-surgical treatment of pulp canal obliteration using contemporary endodontic techniques: case series. *Dental Press Endod.* 2012;2:52-8.
- Tavares W. Management of clinical complications following pulp canal obliteration: a report of two cases. *Dental Press Endod.* 2016;6:54-62.
- Khabbaz MG, Serefoglou MH. The application of the buccal object rule for the determination of calcified root canals. *Int Endod J.* 1996;29(4):284-7.
- Lee JK, Ha BH, Choi JH, Heo SM, Perinpanayagam H. Quantitative three-dimensional analysis of root canal curvature in maxillary first molars using micro-computed tomography. *J Endod.* 2006;32(10):941-5.
- Lara-Mendes STO, Barbosa CFM, Santa-Rosa CC, Machado VC. Guided Endodontic Access in Maxillary Molars Using Cone-beam Computed Tomography and Computer-aided Design/Computer-aided Manufacturing System: A Case Report. *J Endod.* 2018;44(5):875-9.
- Maia LM, de Carvalho Machado V, da Silva N, Brito Junior M, da Silveira RR, Moreira Junior G, Ribeiro Sobrinho AP. Case Reports in Maxillary Posterior Teeth by Guided Endodontic Access. *J Endod.* 2019;45(2):214-8.
- Krastl G, Zehnder MS, Connert T, Weiger R, Kuhl S. Guided Endodontics: a novel treatment approach for teeth with pulp canal calcification and apical pathology. *Dent Traumatol.* 2016;32(3):240-6.
- Zehnder MS, Connert T, Weiger R, Krastl G, Kuhl S. Guided endodontics: accuracy of a novel method for guided access cavity preparation and root canal location. *Int Endod J.* 2016;49(10):966-72.
- Connert T, Zehnder MS, Amato M, Weiger R, Kuhl S, Krastl G. Microguided Endodontics: a method to achieve minimally invasive access cavity preparation and root canal location in mandibular incisors using a novel computer-guided technique. *Int Endod J.* 2018;51(2):247-55.
- Dawood A, Marti Marti B, Sauret-Jackson V, Darwood A. 3D printing in dentistry. *Br Dent J.* 2015;219(11):521-9.
- van der Meer WJ, Vissink A, Ng YL, Gulabivala K. 3D Computer aided treatment planning in endodontics. *J Dent.* 2016;45:67-72.
- Fonseca Tavares WL, Diniz Viana AC, de Carvalho Machado V, Feitosa Henriques LC, Ribeiro Sobrinho AP. Guided Endodontic Access of Calcified Anterior Teeth. *J Endod.* 2018;44(7):1195-9.
- Lara-Mendes STO, Barbosa CFM, Machado VC, Santa-Rosa CC. A New Approach for Minimally Invasive Access to Severely Calcified Anterior Teeth Using the Guided Endodontics Technique. *J Endod.* 2018;44(10):1578-82.
- Januario AL, Barriviera M, Duarte WR. Soft tissue cone-beam computed tomography: A novel method for the measurement of gingival tissue and the dimensions of the dentogingival unit. *Journal of esthetic and restorative dentistry.* 2008;20(6):366-73.
- Tagger M, Tamse A, Katz A, Korzen BH. Evaluation of the apical seal produced by a hybrid root canal filling method, combining lateral condensation and thermatic compaction. *J Endod.* 1984;10(7):299-303.

*Please cite this paper as:* Fonseca Tavares WL, de Carvalho Machado V, Oliveira Fonseca F, Canal Vasconcellos B, Cruz Guimarães L, Diniz Viana AC, Feitosa Henriques LC. Guided Endodontics in Complex Scenarios of Calcified Molars. *Iran Endod J.* 2020;15(1): 50-6. Doi: 10.22037/iej.v15i1.26709.