



Morphology of the Roots and Canals of Mandibular Third Molars, Their Symmetry and Related Factors Using Cone-Beam Computed Tomography

Ladan Hafezi^a , Shirin Sakhdari^a , Negin Moaiyedmohseni^{b*}

^a Department of Oral and Maxillofacial Radiology, Faculty of Dentistry, Tehran Medical Science, Islamic Azad University, Tehran Iran; ^b Dentist, Private Practice; Tehran, Iran

ARTICLE INFO

Article Type: Original Article

Received: 05 Apr 2019

Revised: 12 Aug 2019

Accepted: 31 Aug 2019

Doi: 10.22037/iej.v14i4.24837

*Corresponding author: Negin Moaiyedmohseni, No 70, Foroozanfar St., Gisha St., Tehran, Iran.

Tel: +98-912 6057142

E-mail: neginmoaiyedmohseni@yahoo.com



© The Author(s). 2018 Open Access This work is licensed under the terms of the Creative Commons Attribution-NonCommercial-ShareAlike 4.0 International.

ABSTRACT

Introduction: Adequate knowledge about the anatomy of the roots and canals of mandibular third molars is imperative for a successful treatment. This study aimed to use cone-beam computed tomography (CBCT) to evaluate the morphology of the roots and canals of mandibular third molars and their symmetry. **Methods and Materials:** Totally, 110 CBCT images of bilateral mandibular third molars were evaluated in terms of the number of roots and canals, canal type, isthmus location, location of accessory canals, degree of root curvature and its direction, age and sex of patients and the symmetry of variables in the right and left sides of the mandible. The descriptive statistics, *t*-test and *chi*-square test were applied to analyze data. **Results:** Of all, 71.36% of mandibular third molars had two roots, 20.9% had one single root and 7.72% had three roots. The distal root had one single canal in 89.08%. The mesial root had one single canal in 44.25% and two canals in 49.42%. The Vertucci's types I (45.40%) and IV (34.48%) had the highest frequency in the mesial root while type I (91.95%) had the highest frequency in the distal root. The deviation of mesial root was towards the distal while distal roots were mainly straight. **Conclusion:** The symmetry between the right and left mandibular third molars was significantly high. In case of encountering anatomical complexities in dental treatment of a mandibular third molar, dental clinicians should consider the high possibility of presence of the same condition in the contralateral mandibular third molar.

Keywords: Anatomy; Cone-Beam Computed Tomography; Mandible; Third Molar

Introduction

Variations in third molar roots and canals are among the problems encountered by dental clinicians [1]. Cone-beam computed tomography (CBCT) can be efficiently used to determine the number of third molar roots and canals and assess their anatomy [2]. Considering the increasing popularity of restorative and endodontic dental procedures on third molars, knowledge about their anatomy is imperative for a successful endodontic treatment [3]. In case of loss of the first and second molars, the third molar can be preserved to serve as an abutment for fixed or removable prostheses. It can also be used to preserve alveolar bone and enhance bone regeneration treatments [4].

Adequate knowledge about the anatomy of third molars is also imperative for their extraction [5]. Moreover, auto-transplantation of third molars can be performed to replace the lost teeth [6, 7]. Weine [8] was the first to introduce a classification for the root canal system. Next, Vertucci *et al.* [9] used the clearing and dye penetration technique to offer a more complete classification. Previous studies have shown variability in the number and shape of third molar roots and canals in different ethnic groups [10], males and females [11], and different races [12-14]. Lack of knowledge about this topic significantly increases the risk of failure of such treatments.

Several methods can be used to evaluate third molar morphology. Recently, CBCT was used to precisely assess the

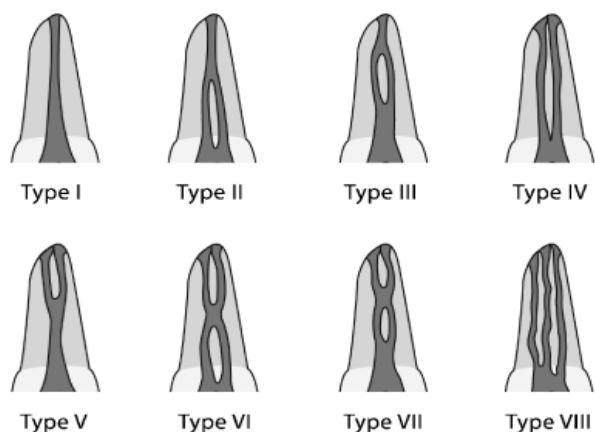


Figure 1. Vertucci's classification

details of tooth anatomy and the jaws [15, 16]. It is easy to use, has adequate diagnostic efficacy and can provide beneficial three-dimensional (3D) data [17].

Considering the gap of information regarding the anatomy of the roots and canals of third molars and their symmetry using CBCT, this study aimed to use CBCT to evaluate a higher number of variables such as symmetry, direction and degree of curvature of the roots, location of isthmus (a thin narrow ribbon-shaped communication between two root canals that contains pulpal tissue) [18, 19] and location of accessory canals (a branch of the main pulp canal or chamber that communicates with the external root surface) [20] which have not been comprehensively studied before. This study aimed to assess the morphology of the roots and canals of mandibular third molars, their symmetry and related factors in a selected Iranian population using CBCT.

Materials and Methods

Over 1000 CBCT scans were evaluated to find 110 CBCT images of bilateral erupted, semi erupted or impacted mandibular third molars without caries, internal/external root resorption, open apices, previous endodontic treatment or root fracture. Based on a pilot study on 10 patients, sample size was calculated to be 110 CBCT scans. In this cross-sectional study, CBCT images of patients between 22 to 50 years that had been obtained for purposes other than this study (such as extraction or implant placement) were retrieved from the archives of the Oral and Maxillofacial Radiology Department of Islamic Azad University, Tehran. Of 110 patients, 55% were females and 45% were males. The patients had a mean age of 25.02 ± 2.21 years. Since presence of both mandibular third molars was imperative for this study, the majority of patients who met our inclusion criteria were

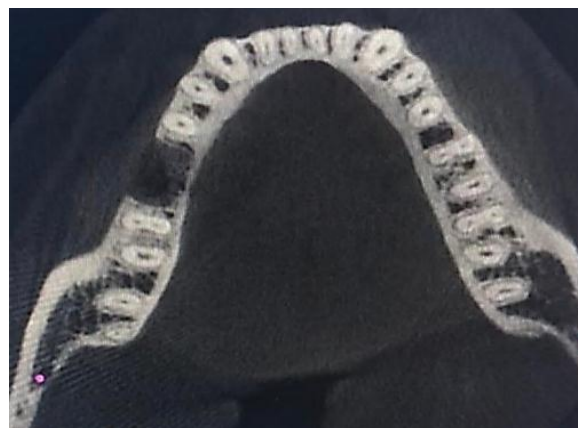

Figure 2. CBCT axial view showing the orifice of canals

younger than 30 years of age. The CBCT scans were evaluated to determine the morphology of mandibular third molars in terms of number and anatomy of the roots and canals and their symmetry. All CBCT scans had been taken by Villa CBCT system (Italy) with the exposure settings of 80 kVp, 85×85 mm field of view, 8-12 mA and 14 sec time. The CBCT scans were evaluated using On Demand 3D software (Cybermed Inc, Irvine, CA, USA). Mandibular third molars were evaluated in terms of the number of roots, number of canals, canal type, isthmus location (presence/absence of isthmus in the roots was first evaluated in all roots and if it was present, its position in the apical, middle or cervical third was reported), location of accessory canal (first, presence/absence of accessory canals was evaluated in all roots and if present, their position in the apical, middle or cervical third was reported) and degree and direction of root curvature (using the Schneider's method) [21, 22] towards the buccal, lingual, mesial or distal. To assess the variables, all CBCT scans were evaluated in the axial, coronal and sagittal planes. Data were recorded in datasheets. The canal type was determined according to the Vertucci's classification [9] (Figure 1). Descriptive statistics (mean, standard deviation, frequency and percentage) and the *t*-test were used to analyze the quantitative data while the *chi*-square test was used to analyze the qualitative data.

Results

In terms of the number of roots in the mandibular right third molars, 70.9% had double roots, 21.81% had one single root and 7.21% had three roots. In the left side, 71.81% had two roots, 20% had one single root and 8.18% had three roots. In general, 71.36% of mandibular third molars had two roots, 20.9% had one single root and 7.72% had three roots.

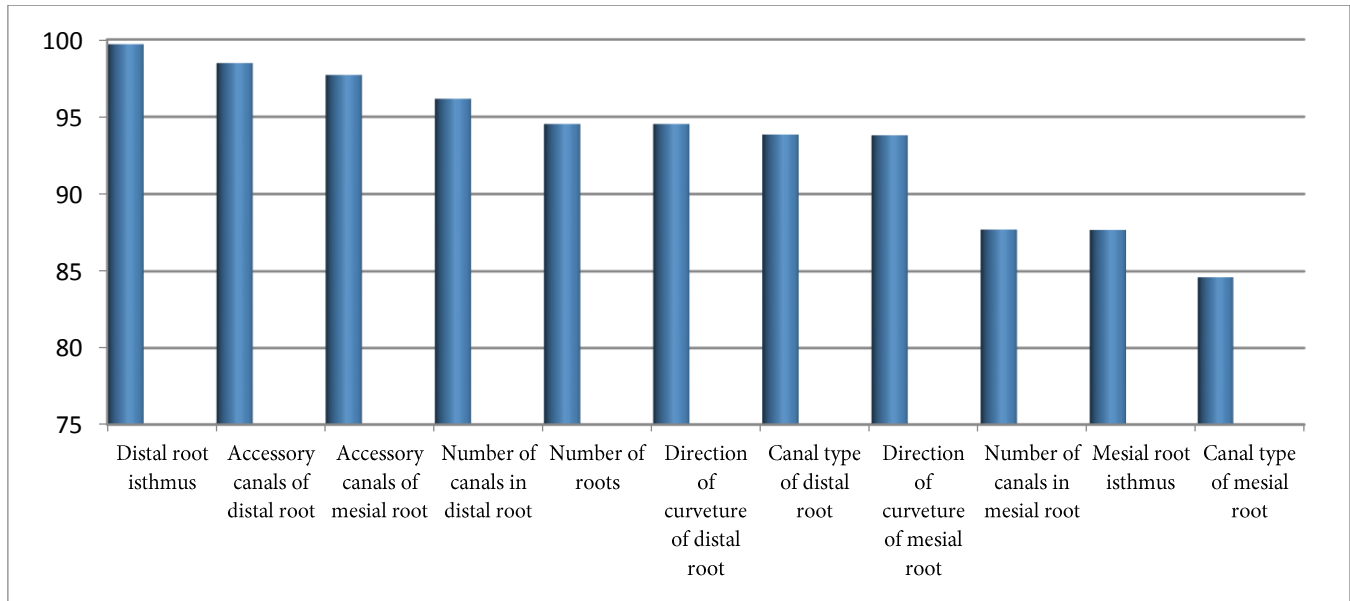


Figure 3. Symmetry of the right and left mandibular third molars in different aspects

Table 1 shows the frequency distribution of the number of roots and canals. As shown, the distal root mainly had one single canal and the mesial root had one single canal in 44.25% and two canals in 49.42% (Figure 2). In cases with a third root, it had one single canal in 100% of the cases and it was mostly located in the distolingual region. Table 2 shows the frequency distribution of the roots according to the canal type. As shown, the Vertucci's types I (45.40%) and IV (34.48%) had the highest frequency in the mesial root while type I (91.95%) had the highest frequency in the distal root.

Table 3 presents the frequency of third molar roots according to the degree of curvature (using the Schneider's method) [21, 22] and its direction. As shown, the curvature of mesial roots was mainly towards the distal while distal roots were mainly straight. The minimum degree of curvature of the mesial and distal roots was 0° while the maximum degree of curvature was 70.4° for the mesial root and 74.1° for the distal root. In single-rooted teeth, the root was mainly straight. Distal deviation ranked second in terms of frequency with a mean degree of curvature of $34.52 \pm 8.17^\circ$. The minimum and maximum degrees of curvature were 0° and 45.4° , respectively.

The difference in the degree of root curvature in the right and left third molars was averagely $6.78 \pm 9.18^\circ$ in the mesial root and $5.95 \pm 12.13^\circ$ in the distal root.

Regarding the presence of accessory canals, accessory canals were noted in the mesial root of 7.71% of third molars. Accessory canals were located in the coronal third in 11.76%,

middle third in 29.41% and apical third of the root in 58.82%.

Accessory canals were found in the distal root of third molars in 3.16%; in which, the accessory canals were in the coronal third in 14.28%, middle third in 28.57% and apical third in 57.14%.

Accessory canals were found in 4.07% of single-canal third molars. Accessory canals were noted in the coronal third in 22.22%, middle third in 33.33% and apical third in 66.66%.

Regarding the location of isthmus, isthmus was found in the mesial root of double-rooted third molars in 16.36%; it was located in the coronal third in 25% of the cases, middle third in 41.66% and apical third in 33.33%.

Isthmus was found in the distal root of double-rooted third molars in 4.09%; it was in the coronal third in 11.11%, in the middle third in 33.33% and in the apical third in 55%.

Isthmus was noted in 1.36% of single-rooted third molars; it was located in the middle third in 33.33% and in the apical third in 66.66%.

Figure 3 shows the symmetry between the right and left third molars from different aspects. As shown, a high percentage of symmetry was noted in all parameters.

No significant difference was noted between males and females in terms of the number of roots ($P=0.9$), number of canals ($P=0.9$), canal type ($P=0.8$), direction of root deviation ($P=0.8$), isthmus location ($P=0.9$), location of accessory canals ($P=0.7$) and symmetry ($P=0.9$).

Discussion

This study found no significant correlation between the number of roots and canals of mandibular third molars and age or sex of patients. Mandibular right third molars had two roots in most cases. Symmetry was noted between the right and left sides in 94.5% of the cases.

Similar to our study, Faramarzi *et al.* [2] reported that third molars mostly had two roots. Third molars with one single root had lower frequency and third molars with three roots had the lowest frequency. However, the percentages reported in their study were different from ours, which may be due to different methodologies of the two studies. We used CBCT while they used preapical radiographs taken from extracted molars. Kuzekanani *et al.* [23] injected dyes into the canals after preparing an access cavity in mandibular third molars. The frequency percentages reported in their study were close to ours; this similarity is probably due to the fact that highly reliable techniques were used in both studies since they used a microscope and we used CBCT.

Jun Beam Park [24] in Korea used CBCT and reported frequency values close to ours. Third molars with two roots had the highest frequency in their study. Single-rooted third molars

ranked second and three-rooted teeth had the lowest frequency. Difference in percentage values can be due to racial differences. Similar to our study, they reported around 93% symmetry between the right and left teeth. However, they only evaluated symmetry in terms of the number of roots. They found no significant difference between males and females, which was in accord with our study.

In Jordan, Ahmad *et al.* [25] used the dye injection technique to assess the mandibular third molar canals. The majority of third molars had two roots. In terms of the number and type of single-rooted mandibular third molars, the majority of them had two canals. In terms of canal type, type IV had the highest frequency followed by type I. In mandibular third molars with two roots, the mesial root mostly had one or two canals. In terms of canal type, type I and then type IV had the highest frequency. Distal root had one single canal in the majority of cases and was type I. The third root (additional root) had one single canal in all cases and it was mainly located in the distolingual region. The rate of symmetry was high in their study. Their results were mainly similar to ours due to their reliable technique of evaluation; however, small differences existed in the reported percentage values due to racial differences.

Table 1. Frequency distribution of roots in terms of number of canals in mandibular third molars

	Single canal	Two canals	Three canals	Four canals	Five canals	Total
Single root	8 (17.39%)	34 (73.91%)	4 (8.69%)	0	0	46 (100%)
Mesial root	77 (44.25%)	86 (49.42%)	11 (6.32%)	0	0	174 (100%)
Distal root	155 (89.08%)	18(10.34%)	1 (0.57%)	0	0	174 (100%)
Additional root	17 (100%)	0	0	0	0	17 (100%)
Total	8 (3.63%)	99 (45%)	103 (46.81%)	9 (4.09%)	1 (0.45%)	220 (100%)

Table 2. Frequency distribution of roots according to the canal type in mandibular third molars

	I	II	III	IV	V	VI
Mesial root	79 (45.40%)	27 (15.51%)	1(0.57%)	60 (34.48%)	6 (3.44%)	1 (0.57%)
Distal root	160 (91.95%)	3 (1.72%)	0	5(2.87%)	6(3.44%)	0
Additional root	17(100%)	0	0	0	0	0
Single root	12 (26.08%)	2 (4.34%)	0	31 (67.39%)	1(2.17%)	0
Total	268 (65.2%)	32 (7.78)	1 (0.24)	96 (23.35)	13(3.16)	1 (0.24)

Table 3. Frequency distribution of mandibular third molar roots according to the degree and direction of root curvature

		Towards distal	Towards mesial	Straight
Right mesial root	Percentage	61.53	7.69	30.76
	Degree of curvature	41.41±11.92°	32.23±13.32°	0
Left mesial root	Percentage	82.65	32.6	27.84
	Degree of curvature	40.49±12.23°	41.72±5.65°	0
Right distal root	Percentage	23.07	11.53	65.38
	Degree of curvature	30.13±12.02°	36.44±15.16°	0
Left distal root	Percentage	18.98	16.47	64.55
	Degree of curvature	31.62±19.17	34.52±12.52	0

Faramarzi *et al.* [2] reported that the majority of third molars in their study had two canals followed by three canals, which was in agreement with our results. The mesial root was mainly type IV or II and the distal root had one single canal. Ahmad *et al.* [25] reported that most third molars in their study had two canals followed by three canals. Small differences in the percentage values between the two studies can be due to racial differences. None of the aforementioned two studies evaluated the symmetry of teeth. Ahmed *et al.* [26] reported that in double-rooted third molars, the mesial root was mainly types I and II; types V and IV had a lower frequency. The distal root was type I in 90% but types V, IV and II were also seen. Their results were in agreement with ours with the difference that type IV had slightly higher frequency than type II.

In our study, accessory canals had a prevalence of 4.07% in single-rooted third molars; this rate was 7.71% in the mesial root of double-rooted mandibular third molars and 3.16% in the distal root of double-rooted mandibular third molars; accessory canals were mostly seen in the apical third. The rate of symmetry in terms of presence of accessory canals was 97.5% in the mesial root and 98.7% in the distal root. Ahmed *et al.* [26] reported the highest frequency of accessory canals in the apical third and then in the middle third and coronal third, which was in line with our results. However, they did not assess the symmetry of the right and left teeth in terms of accessory canals.

In single-rooted mandibular third molars, isthmus was seen in 1.35% of the cases, and was mainly located in the apical third. The prevalence of isthmus in double-rooted third molars was 16.36% in the mesial root (mainly in the middle third) and 4.09% in the distal root (mainly in the apical third). The rate of symmetry in terms of presence of isthmus was 87.6% in the mesial root and 98.7% in the distal root. According to our observations, accessory canals and isthmus are not commonly seen in mandibular third molars. However, if observed at one side, it is highly probable that they are present in the other side as well. Not many studies have evaluated the location and symmetry of isthmuses in mandibular third molars.

Regarding the frequency distribution of roots in terms of the degree and direction of curvature in the mesial root of double-rooted third molars, the curvature was mainly towards the distal in the right and left mandibular third molars in our study. The distal root of double-rooted third molars in both the right and left sides was straight; the root of single-rooted teeth

was mainly straight as well. The direction of curvature of mesial root in the right and left sides was the same in 90.1%; the rate of similarity was 93.8% for the distal root. It should be noted that no comprehensive previous study is available on the degree and direction of root curvature and the symmetry between the right and left teeth in this respect.

Conclusion

Mandibular third molars have high anatomical variations. However, symmetry between the right and left third molars is significantly high. If dental clinicians encounter anatomical complexities in dental treatment of a mandibular third molar, they should consider the high possibility of presence of the same condition in the mandibular third molar of the other side.

Acknowledgment

The Authors thank Department of Oral and Maxillofacial Radiology of Tehran Medical Science Islamic Azad University, Faculty of dentistry, for their supports.

Conflict of Interest: 'None declared'.

References

1. Mohammadi Z, Jafarzadeh H, Shalavi S, Bandi S, Patil S. Root and Root Canal Morphology of Human Third Molar Teeth. *J Contemp Dent Pract.* 2015;16(4):310-3.
2. Faramarzi F, Shahriari S, Shokri A, Vossoghi M, Yaghoobi G. Radiographic evaluation of root and canal morphologies of third molar teeth in Iranian population. *Avicenna J Dent Res.* 2013;5(1):e21102.
3. Abella F, Patel S, Duran-Sindreu F, Mercade M, Roig M. Mandibular first molars with disto-lingual roots: review and clinical management. *Int Endod J.* 2012;45(11):963-78.
4. Akhlaghi NM, Abbas FM, Mohammadi M, Shamloo MR, Radmehr O, Kaviani R, Rakhshan V. Radicular anatomy of permanent mandibular second molars in an Iranian population: A preliminary study. *Dent Res J (Isfahan).* 2016;13(4):362-6.
5. Libersa P, Savignat M, Tonnel A. Neurosensory disturbances of the inferior alveolar nerve: a retrospective study of complaints in a 10-year period. *J Oral Maxillofac Surg.* 2007;65(8):1486-9.
6. Tsurumachi T, Kakehashi Y. Autotransplantation of a maxillary third molar to replace a maxillary premolar with vertical root fracture. *Int Endod J.* 2007;40(12):970-8.
7. Yan Q, Li B, Long X. Immediate autotransplantation of mandibular third molar in China. *Oral Surg Oral Med Oral Pathol Oral Radiol Endod.* 2010;110(4):436-40.
8. Weine FS. *Endodontic therapy.* 5th ed. St. Louis: CV Mosby; 1996.

9. Vertucci FJ. Root canal morphology and its relationship to endodontic procedures. *Endodontic topics*. 2005;10(1):3-29.
10. Peiris R, Takahashi M, Sasaki K, Kanazawa E. Root and canal morphology of permanent mandibular molars in a Sri Lankan population. *Odontology*. 2007;95(1):16-23.
11. Sert S, Bayirli GS. Evaluation of the root canal configurations of the mandibular and maxillary permanent teeth by gender in the Turkish population. *J Endod*. 2004;30(6):391-8.
12. Kottoor J, Velmurugan N, Surendran S. Endodontic management of a maxillary first molar with eight root canal systems evaluated using cone-beam computed tomography scanning: a case report. *J Endod*. 2011;37(5):715-9.
13. Chourasia HR, Meshram GK, Warhadpande M, Dakshindas D. Root canal morphology of mandibular first permanent molars in an Indian population. *Int J Dent*. 2012;2012:745152.
14. Al-Qudah AA, Awawdeh LA. Root and canal morphology of mandibular first and second molar teeth in a Jordanian population. *Int Endod J*. 2009;42(9):775-84.
15. Mokhtari H, Niknami M, Mokhtari Zonouzi HR, Sohrabi A, Ghasemi N, Akbari Golzar A. Accuracy of Cone-Beam Computed Tomography in Determining the Root Canal Morphology of Mandibular First Molars. *Iran Endod J*. 2016;11(2):101-5.
16. Nur BG, Ok E, Altunsoy M, Aglarci OS, Colak M, Gungor E. Evaluation of the root and canal morphology of mandibular permanent molars in a south-eastern Turkish population using cone-beam computed tomography. *Eur J Dent*. 2014;8(2):154-9.
17. Walter C, Weiger R, Zitzmann NU. Accuracy of three-dimensional imaging in assessing maxillary molar furcation involvement. *J Clin Periodontol*. 2010;37(5):436-41.
18. Bhat SP, Sheth R, Kumar P, Khilosiya A. Root canal morphology and assessment of incidence, type, and position of isthmus in permanent mandibular central incisor in North Indian population: An in vitro study. *Endodontology*. 2017;29(2):107-14.
19. Haghanifar S, Moudi E, Madani Z, Farahbod F, Bijani A. Evaluation of the Prevalence of Complete Isthmii in Permanent Teeth Using Cone-Beam Computed Tomography. *Iran Endod J*. 2017;12(4):426-31.
20. Ahmed HMA, Neelakantan P, Dummer PMH. A new system for classifying accessory canal morphology. *Int Endod J*. 2018;51(2):164-76.
21. Schneider SW. A comparison of canal preparations in straight and curved root canals. *Oral Surg Oral Med Oral Pathol*. 1971;32(2):271-5.
22. Kucher M, Dannemann M, Modler N, Hannig C, Weber MT. Effects of Endodontic Irrigants on Material and Surface Properties of Biocompatible Thermoplastics. *Dent J (Basel)*. 2019;7(1).
23. Kuzekanani M, Haghani J, Nosrati H. Root and canal morphology of mandibular third molars in an Iranian population. *J Dent Res Dent Clin Dent Prospects*. 2012;6(3):85-8.
24. Park JB, Kim N, Park S, Ko Y. Evaluation of number of roots and root anatomy of permanent mandibular third molars in a Korean population, using cone-beam computed tomography. *Eur J Dent*. 2013;7(3):296-301.
25. Ahmad IA, Azzeh MM, Zwiri AM, Hajja MASA, Diab MM. Root and root canal morphology of third molars in a Jordanian subpopulation. *Saudi Endod J*. 2016;6(3):113-21.
26. Ahmed HMA. Management of third molar teeth from an endodontic perspective. *Eur J Gen Dent*. 2012;1(3):148-60.

Please cite this paper as: Hafezi L, Sakhdari SH, Moaiyedmohseni N. Morphology of the Roots and Canals of Mandibular Third Molars, Their Symmetry and Related Factors Using Cone-beam Computed Tomography. *Iran Endod J*. 2019;14(4): 283-8. *Doi:* 10.22037/iej.v14i4.24837.