



## Cone-Beam Computed Tomographic Evaluation of Artifact Effects of Three Different Sealers

Maryam Tofangchiha<sup>a</sup> , Marjan Bolbolian<sup>b\*</sup> , Sahar Rahrovan<sup>c</sup> , Monirsadat Mirzadeh<sup>d</sup> ,  
Neda Hajihassani<sup>b</sup>

<sup>a</sup> Department of Oral and Maxillofacial Radiology, Dental Caries Prevention Research Center, Qazvin University of Medical Sciences, Qazvin, Iran; <sup>b</sup> Department of Endodontics, Faculty of Dentistry, Qazvin University of Medical Sciences, Qazvin, Iran; <sup>c</sup> Student Research Committee, Faculty of Dentistry, Qazvin University of Medical Sciences, Qazvin, Iran; <sup>d</sup> Department of Community Medicine, Metabolic Disease Research Center, Qazvin University of Medical Sciences, Qazvin, Iran

### ARTICLE INFO

Article Type:

Original Article

Received: 29 Jun 2018

Revised: 13 Sep 2018

Accepted: 16 Sep 2018

Doi: 10.22037/iej.v13i4.19743

\*Corresponding author: Marjan Bolbolian, Department of Endodontics, Faculty of Dentistry, Qazvin University of Medical Sciences, Bahonar Blvd., Qazvin, Iran.

Tel: +98-283 3353064

E-mail: marjan.bolbolian@yahoo.com



© The Author(s). 2018 Open Access This work is licensed under the terms of the Creative Commons Attribution-NonCommercial-ShareAlike 4.0 International.

### ABSTRACT

**Introduction:** Cone-beam computed tomography (CBCT) is one of the most important diagnostic tools in maxillofacial imaging. Nowadays different sealers are used in root canal therapy and some of them can create artifact in CBCT images. The aim of this study was to evaluate the effect of different sealers including AH-26, Diadent, and Anyseal in creation of artifact bands in the CBCT images based on voxel size. **Methods and Materials:** A total of 44 single rooted extracted teeth were selected. The canals were prepared by crown-down technique. All teeth were manually filed up to master apical file (MAF) size 45 and 1 mm shorter than the apical foramen. The teeth were divided into 4 equal groups. The canals were filled with gutta-percha and either of sealers AH-26, Diadent or Anyseal by lateral condensation technique. The control group were filled just with gutta-percha without any sealer. The CBCT images were taken in voxel sizes of 0.3 and 0.15. The Fisher exact and McNemar tests were used for statistical analysis. **Results:** Although, the control group had the lowest ratio of presence to absence of artifact, the ratio of presence to absence of artifact in voxel size of 0.3 and 0.15 mm were significantly lower in Anyseal than AH-26 ( $P=0.031$ ,  $P=0.020$ ) and Diadent ( $P=0.001$ ,  $P=0.002$ ). No significant difference was detected between two voxel sizes ( $P>0.05$ ). **Conclusion:** In this *in vitro* study, all evaluated sealers induced artifacts in the CBCT images. Anyseal sealer had the lowest artifact in both evaluated voxel sizes.

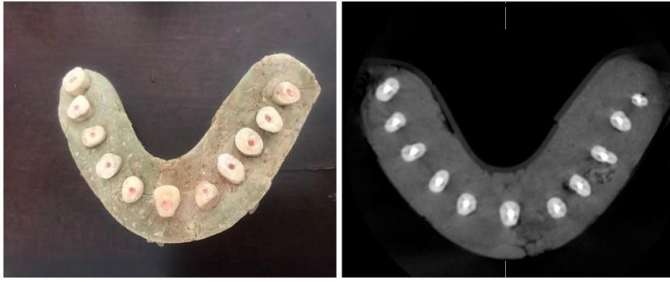**Keywords:** Artifacts; Canal Sealer; Cone-Beam Computed Tomography; Root Canal Filling Material; Root Fracture

## Introduction

Cone-beam computed tomography (CBCT) is an imaging technique, which became available in European market since 1996 and in the US market from 2001 [1]. It can provide whole image of the maxillofacial region, is one of the preferred methods for assessment of implant sites and can be used effectively in clinical dentistry [2, 3]. Also, CBCT is more effective than conventional radiography especially in cases with difficulties in primary diagnosis [4, 5]. Recently CBCT has become an important tool for diagnosis of tooth fractures, root degeneration, dilation of periodontal ligament (PDL), and pathological conditions of pulp and periapical regions due to its abilities [6, 7]. Some parameters related to the imaging steps such as the sizes of field of view and voxel affect the

quality of CBCT images [8]. However, the main factor that decreases the quality of CBCT images is artifact. Artifact includes any distortions or errors in image which are not related to the evaluated object [9, 10]. These artifacts appear in CT images as dark bands, dark lines and streaks [11]. Some artifacts such as distortions and linear and dark bands that can appear between two dense objects can be created due to limitations associated with the physical process [12, 13]. Dark bands artifacts may be due to radiopaque materials such as metals, gutta-percha and sealers. Therefore, identifying the pattern of these artifacts is helpful in differential diagnosis of artifacts from true root fractures [8].

In the present study, we aimed to evaluate the effects of AH-26, Diadent and Anyseal sealers on the induction of artifact bands in CBCT images based on voxel size.



**Figure 1.** Acrylic cassette with mounted teeth (left) and CBCT image of such costumed cast (right)

## Materials and Methods

In an experimental *in vitro* study, forty-four extracted single root human teeth with intact crown, closed apices, straight, smooth, and healthy roots with similar lengths, type 1 Vertucci canal, and quite distinct canal in radiography were included. Any teeth with root fracture, cracks, root degeneration, calcification and open apex were excluded. Extracted teeth were disinfected by keeping in 2.5% Sodium hypochlorite (NaOCl) (Pakshoo, Iran) for 2 days. Then soft tissues were cleaned and teeth were stored in the normal saline (BitalzadDaroo, Iran) until use. Crown was cut below the cemento-enamel junction (CEJ) where the length of remained root was 14 mm. Coronal root portion was prepared with crown-down technique and using Gates Glidden sizes 2 and 3. All teeth were filed manually by stainless steel K-file (Dentsply, Maillefer, Switzerland) to master apical file (MAF)#45 and 1 mm shorter than the apical foramen. Ethylenediaminetetraacetic acid (EDTA) solution (MD, cleanser, Meta Co, Korea) for 2 min to eliminate the smear layer. Again, rinsing with 2.5% NaOCl and normal saline were done. Paper cone #45 (AriaDent, Tehran, Iran) was used to dry the canal before filling. MAC size in all teeth was 45.

Teeth were randomly divided into four equal groups. Canals were filled by lateral condensation method using gutta-percha alone as control groups and with Diadent, AH-26 (Dentsply, Tulsa Dental, Tulsa, OK, USA) or Anyseal (Medicus, Cheongju, Korea). Sealers were used based on the manual instruction and placed in the canal by master cone. Teeth were stored in 37°C and 100% relative humidity for 1 week and then were mounted. To simulate PDL space, root of each tooth was covered by 1 mm of wax and teeth were placed in the custom cast, which was formed, similar to human mandible.

After 24 h, all samples were placed in the container and were imaged using CBCT Promax3D (Planmeca, Finland) with voxel size 0.15 and then 0.3 mm. CBCT images were obtained with 87 kVp, 10 mA, exposure time of 12 sec, field of view (FOV) of 8×8 cm and all teeth were depicted in one image. Finally, 8 CBCT

images with 10 axial plane from each custom cast with 0.2 mm distance were prepared using Romexis viewer 3.4.3 R software (Planmeca Romexis Viewer, Helsinki, Finland). Six sequential images, in which all the samples were depicted, were selected. Images were simultaneously evaluated by two observers, one maxillofacial radiologist and one endodontist, who were not aware of the details of the specimens (Figure 1). In the present study, axial CBCT scans enabled the identification of artifact as hypodense lines crossing the root line [14].

Totally, 66 images were prepared (6 section for each sample) and observers in each section examined and coded 4 regions (buccal, lingual, mesial, and distal) in terms of the presence of a radiolucent band from 0 to 4 codes.

## Statistical analysis

SPSS software (Statistical Package for Social Science, SPSS, version 21.0, SPSS, Chicago, IL, USA) was used for statistical analysis. After weighing the data and using the McNemar test, the ratio of presence to lack of artifacts in two voxel size of 0.3 mm and 0.15 mm and also different sealers were evaluated.  $P < 0.05$  was considered as significant difference.

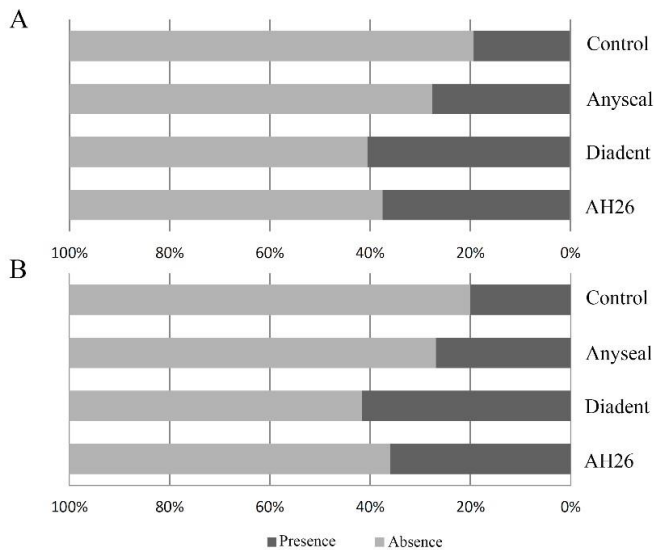
## Results

Comparison of the ratio of presence to lack of artifacts in different groups and voxel size are presented in Table 1. Significant higher percentage of artifacts in AH-26 and Diadent compared to Anyseal ( $P=0.031$  and  $P=0.001$ ) and control groups ( $P=0.001$  and  $P=0.001$ ) in voxel size 0.3 were seen. In 0.15 mm voxel size, all AH-26, Diadent and Anyseal had higher percentage of artifacts in comparison to control group ( $P=0.001$ ,  $P=0.001$ ,  $P=0.031$ , respectively). Also, both AH-26 and Diadent had higher percentage of artifacts against Anyseal ( $P=0.02$  and  $P=0.002$ ). No significant differences were detected between AH-26 and Diadent in neither 0.3 mm nor 0.15 mm voxel sizes as well as between two voxel sizes in all four groups ( $P > 0.05$ ) (Figure 2).

**Table 1.** Comparison of the ratio of presence: absence of artifacts between different groups and two voxel size

Groups	Voxel size (mm)		P-value*
	0.3	0.15	
Control	53:211 <sup>a</sup>	51:213 <sup>a</sup>	0.5
AH-26	95:169 <sup>b</sup>	99:165 <sup>b</sup>	0.12
Diadent	110:154 <sup>b</sup>	107:157 <sup>b</sup>	0.25
Anyseal	71:193 <sup>a</sup>	73:191 <sup>c</sup>	0.15

\* Presented P-values are related to comparison between two voxel sizes in each group; Different superscript letters in each column indicated significant differences between four groups ( $P < 0.05$ )



**Figure 2.** Percentage of presence and absence of artifacts in four different groups at voxel sizes of A) 0.3 mm, and B) 0.15 mm

## Discussion

In the present study, the effects of different sealers on the induction of artifacts in the CBCT images based on voxel size were evaluated and compared. We found that although AH-26 and Diadent induced more artifacts than Anyseal in both voxel sizes, no significant differences were detected between two voxel sizes in the ratio of presence to absence of artifacts in none of sealers.

Studies have shown that the axial plans in the diagnosis of root fractures are more accurate than sagittal and coronal plan. However, artifacts simulate fractures and affects the accurate diagnosis of tooth fracture especially in the primary steps [15, 16].

Several studies evaluated the effects of gutta-percha, different sealers, and implants on the presence of artifacts in CBCT and CT images [8, 17-19]. Although, it has been also reported that root canal filling decreased the specificity of CBCT without any changes on the overall accuracy [8]. Neves *et al.* [20] found that the intracanal material had significant effect on the diagnostic ability of CBCT and this technique is not beneficial for the diagnosis of root fractures in the presence of metal posts. Also, Patel *et al.* [12] expressed that gutta-percha related artifacts caused misinterpretation of the vertical root fractures and decreased the accuracy of CBCT technique. Furthermore, Costa *et al.* [21] reported that the presence of a metallic post significantly decreased the accuracy of CBCT technique. About the sealer-related mechanism of artifact induction, it can be said that bismuth oxide and titanium in the AH-26 and zirconium oxide and calcium tungstate in Diadent are radiopaque materials which can induce certain artifacts [22]. Moreover, induction of artifacts in CBCT

images regardless of the types of CBCT devices by Sealer 26 was recently reported [23]. Although chemical composition of sealers are defined, but concentration percent of any matter is not available. This different percentages could be one reason for different results in the researches according to sealer type in the study. Zirconium oxide is also found in the Anyseal but it probably had lower concentration in comparison to Diadent [23]. Similar highest percentage of artifacts in AH-26 in both voxel sizes also reported previously [14]. Rabelo *et al.* [11] found that metal posts had a higher score for hypodense halos and hypodense lines in comparison to gutta-percha images qualitatively. This means the substantial image loss due to hypodense metal artifacts which is in agreement with our findings and other previous studies [17, 19, 24].

On the other hand, it has been confirmed that the radiation dose to the patient as well as image's resolution will increase when the voxel size decrease [25]. Britojunior *et al.* [14] reported that artifacts were decreased in voxel size of 0.076 mm in comparison to voxel size of 0.2 mm. Also, Ozer *et al.* [26] found that a 0.2 mm voxel size was the best protocol in comparison with 0.125, 0.3, and 0.4 mm voxel size, considering the lower x-ray exposure and good diagnostic performance. Costa *et al.* [27] and colleagues also expressed that CBCT imaging with small voxel is better in detecting horizontal root fracture due to lower patients radiations exposure and higher accuracy. Moreover, Ikubo *et al.* [28] found that for higher accuracy and lower exposure to the patients, it is better to use small voxel size and place the target tooth in the center of the FOV. However, different results in different studies may be influenced by factors such as CBCT brand combination of voxel size and FOV size, sealers type and observers experience. Based on our findings, which detected no differences between two voxel size in the presence of artifacts in the CBCT images, it seems that use of larger voxel size is better to reduce patient's absorption dose.

## Conclusion

In summary, the results of the present *in vitro* study confirmed that all of sealers created artifacts and no significant differences between the two voxel sizes was reported. Anyseal sealer had the lowest artifact in both voxel sizes. Therefore, use of larger voxel size for decrease of radiation dose to the patient regardless of sealers is suggested.

## Acknowledgement

The authors would like to thank the Dental Caries Prevention Research Center of Qazvin University of Medical Sciences.

Conflict of Interest: 'None declared'.

## References

- Hatcher DC. Operational principles for cone-beam computed tomography. *J Am Dent Assoc.* 2010;141:3S-6S.
- Bornstein MM, Horner K, Jacobs R. Use of cone beam computed tomography in implant dentistry: current concepts, indications and limitations for clinical practice and research. *Periodontol* 2000. 2017;73(1):51-72.
- Safi Y, Ghaedsharaf S, Aziz A, Hosseinpour S, Mortazavi H. Effect of field of view on detection of external root resorption in cone-beam computed tomography. *Iran Endod J.* 2017;12(2):179.
- Eslami E, Barkhordar H, Abramovitch K, Kim J, Masoud MI. Cone-beam computed tomography vs conventional radiography in visualization of maxillary impacted-canine localization: A systematic review of comparative studies. *Am J Orthod Dentofacial Orthop.* 2017;151(2):248-58.
- Kajan ZD, Taramsari M, Fard NK, Khaksari F, Hamidi FM. The Efficacy of Metal Artifact Reduction Mode in Cone-Beam Computed Tomography Images on Diagnostic Accuracy of Root Fractures in Teeth with Intracanal Posts. *Iran Endod J.* 2018;13(1):47.
- Mora MA, Mol A, Tyndall DA, Rivera EM. In vitro assessment of local computed tomography for the detection of longitudinal tooth fractures. *Oral Surg Oral Med Oral Pathol Oral Radiol Endod.* 2007;103(6):825-9.
- Ardakani FE, Razavi SH, Tabrizizadeh M. Diagnostic value of cone-beam computed tomography and periapical radiography in detection of vertical root fracture. *Iran Endod J.* 2015;10(2):122.
- Hassan B, Metska ME, Ozok AR, van der Stelt P, Wesselink PR. Detection of vertical root fractures in endodontically treated teeth by a cone beam computed tomography scan. *Journal of endodontics.* 2009;35(5):719-22.
- Chen Y, Li Y, Guo H, Hu Y, Luo L, Yin X, Gu J, Toumoulin C. CT metal artifact reduction method based on improved image segmentation and sinogram in-painting. *Math Probl Eng.* 2012;2012.
- Safi Y, Hosseinpour S, Aziz A, Bamedi M, Malekashtari M, Vasegh Z. Effect of amperage and field of view on detection of vertical root fracture in teeth with intracanal posts. *Iran Endod J.* 2016;11(3):202.
- Rabelo KA, Cavalcanti YW, de Oliveira Pinto MG, Sousa Melo SL, Campos PSF, de Andrade Freitas Oliveira LS, de Melo DP. Quantitative assessment of image artifacts from root filling materials on CBCT scans made using several exposure parameters. *Imaging Sci Dent.* 2017;47(3):189-97.
- Patel S, Dawood A, Wilson R, Horner K, Mannocci F. The detection and management of root resorption lesions using intraoral radiography and cone beam computed tomography—an in vivo investigation. *Int Endod J.* 2009;42(9):831-8.
- White SC, Pharoah MJ. *Oral radiology-E-Book: Principles and interpretation: Elsevier Health Sciences;* 2014.
- Brito-Júnior M, Santos L, Faria-e-Silva A, Pereira R, Sousa-Neto M. Ex vivo evaluation of artifacts mimicking fracture lines on cone-beam computed tomography produced by different root canal sealers. *Int Endod J.* 2014;47(1):26-31.
- Bechara B, Moore W, McMahan C, Noujeim M. Metal artefact reduction with cone beam CT: an in vitro study. *Dentomaxillofac Radiol.* 2012;41(3):248-53.
- Helvacioğlu-Yigit D, Kocasarac HD, Bechara B, Noujeim M. Evaluation and reduction of artifacts generated by 4 different root-end filling materials by using multiple cone-beam computed tomography imaging settings. *J Endod.* 2016;42(2):307-14.
- Vasconcelos K, Nicolielo L, Nascimento M, Haiter-Neto F, Bóscolo F, Van Dessel J, Ezeldeen M, Lambrichts I, Jacobs R. Artefact expression associated with several cone-beam computed tomographic machines when imaging root filled teeth. *Int Endod J.* 2015;48(10):994-1000.
- Benic GI, Sancho-Puchades M, Jung RE, Deyhle H, Hämmerle CH. In vitro assessment of artifacts induced by titanium dental implants in cone beam computed tomography. *Clinical Oral Implants Research.* 2013;24(4):378-83.
- Chindasombatjaroen J, Kakimoto N, Murakami S, Maeda Y, Furukawa S. Quantitative analysis of metallic artifacts caused by dental metals: comparison of cone-beam and multi-detector row CT scanners. *Oral Radiology.* 2011;27(2):114-20.
- Neves FS, Freitas DQ, Campos PSF, Ekestubbe A, Lofthag-Hansen S. Evaluation of cone-beam computed tomography in the diagnosis of vertical root fractures: the influence of imaging modes and root canal materials. *J Endod.* 2014;40(10):1530-6.
- Costa FF, Gaia BF, Umetsubo OS, Cavalcanti MGP. Detection of horizontal root fracture with small-volume cone-beam computed tomography in the presence and absence of intracanal metallic post. *J Endod.* 2011;37(10):1456-9.
- Valiozadeh S, Khosravi M, Azizi Z. Diagnostic accuracy of conventional, digital and Cone Beam CT in vertical root fracture detection. *Iran Endod J.* 2011;6(1):15-20.
- Celikten B, Jacobs R, deFaria Vasconcelos K, Huang Y, Nicolielo LFP, Orhan K. Assessment of volumetric distortion artifact in filled root canals using different cone-beam computed tomographic devices. *J Endod.* 2017;43(9):1517-21.
- Pauwels R, Stamatakis H, Bosmans H, Bogaerts R, Jacobs R, Horner K, Tsiklakis K, Consortium SP. Quantification of metal artifacts on cone beam computed tomography images. *Clin Oral Implants Res.* 2013;24:94-9.
- Spin-Neto R, Gotfredsen E, Wenzel A. Impact of voxel size variation on CBCT-based diagnostic outcome in dentistry: a systematic review. *J Digit Imaging.* 2013;26(4):813-20.
- Edlund M, Nair MK, Nair UP. Detection of vertical root fractures by using cone-beam computed tomography: a clinical study. *J Endod.* 2011;37(6):768-72.
- Costa FF, Gaia BF, Umetsubo OS, Pinheiro LR, Tortamano IP, Cavalcanti MGP. Use of large-volume cone-beam computed tomography in identification and localization of horizontal root fracture in the presence and absence of intracanal metallic post. *J Endod.* 2012;38(6):856-9.
- Iikubo M, Nishioka T, Okura S, Kobayashi K, Sano T, Katsumata A, Ariji E, Kojima I, Sakamoto M, Sasano T. Influence of voxel size and scan field of view on fracture-like artifacts from gutta-percha obturated endodontically treated teeth on cone-beam computed tomography images. *Oral Surg Oral Med Oral Pathol Oral Radiol Endod.* 2016;122(5):631-7.

*Please cite this paper as:* Tofangchiha M, Bolbolian M, Rahrovan S, Mirzadeh M, Hajihassani N. Cone-Beam Computed Tomographic Evaluation of Artifact Effects of Three Different Sealers. *Iran Endod J.* 2018;13(4):545-8. *Doi:* 10.22037/iej.v13i4.19743.