



Incidence of Dentinal Defects and Vertical Root Fractures after Endodontic Retreatment and Mechanical Cycling

Mariana De Carlo Bello^a, Rafael Pillar^b, Pauline Mastella Lang^c, Carina Michelon^d, Ricardo Abreu da Rosa^e,
Carlos Alexandre Souza Bier^f

^a Department of Stomatology, Federal University of Santa Maria (UFSM), Santa Maria, RS, Brazil; ^b Department of Stomatology, Federal University of Santa Maria (UFSM), Santa Maria, RS, Brazil; ^c Department of Conservative Dentistry, Federal University of Rio Grande do Sul, Porto Alegre, RS, Brazil; ^d Department of Stomatology, Federal University of Santa Maria (UFSM), Santa Maria, RS, Brazil; ^e Department of Conservative Dentistry, Federal University of Rio Grande do Sul, Porto Alegre, RS, Brazil; ^f Department of Stomatology, Federal University of Santa Maria (UFSM), Santa Maria, RS, Brazil

ARTICLE INFO

Article Type:

Original Article

Received: 10 Jan 2017

Revised: 02 May 2017

Accepted: 17 May 2017

Doi: 10.22037/iej.v12i4.16587

*Corresponding author: Mariana De Carlo Bello, Avenida Medianeira 1688, apartment 802, 97060002-Santa Maria, RS-Brazil.

Tel: +55-559159-5503

E-mail: maridcbello@yahoo.com.br

ABSTRACT

Introduction: The aim of this study was to evaluate the incidence of dentinal defects and vertical root fractures (VRFs) after endodontic retreatment and mechanical cycling (MC). **Methods and Materials:** Two hundred mandibular premolars were selected. Forty teeth were left unprepared (control group). The remaining 160 root canals were prepared with ProTaper instruments and filled by using two different techniques [eighty with lateral compaction (LC) and eighty with single-cone (SC)]. Forty canals from each group (LC and SC) received no further treatment. The remaining eighty teeth were divided into two groups (LCR and SCR) ($n=40$) in order to undergo the removal of the root filling, re-preparation and refilling with lateral compaction and single-cone, respectively. All of the teeth were subjected to MC (1000000 cycles, 130 N, 2.2 Hz and 37°C). The roots were sectioned at 3, 6 and 9 mm from the apex and observed under 20× magnification. The defects were classified as: *no defect*, *VRF* and *other defects*. Statistical analysis was performed using the Fisher's Exact test and the *Chi-Squared* tests ($\alpha=0.05$). **Results:** MC alone did not promote any other defects or VRFs. Experimental groups presented higher dentinal defects than the control group ($P=0.021$). Retreatment groups did not present a higher amount of dentinal defects than the groups that were subjected to the first treatment ($P>0.05$). **Conclusion:** Endodontic treatment and retreatment, regardless of the filling technique and MC, did not influence the occurrence of dentinal defects or VRFs in the human premolars.

Keywords: Defects; Endodontics; Retreatment; Root Canal

Introduction

An endodontic retreatment is indicated in those cases that experience the failure of an initial treatment and it aims to regain access to the apical foramen by a complete removal of the root canal filling material, and thus, allowing for a new efficient cleaning, a shaping of the root canal system, and a proper course of new root canal filling [1]. However, the additional stress that

is caused in the root walls by the removal of an endodontic filling [2], as well as in the preparation [3] and in the filling [4] of the root canals, is able to generate dentinal defects, which may turn into vertical root fractures (VRFs) [2, 5]. VRFs are a significant complication of root canal therapy and may be explained as being the result of the spread of microscopic cracks from areas of a force concentration [6] which may lead to a tooth or root extraction [7].

Moreover, the forces transferred to the root during a masticatory function can also result in microcracks and VRFs [8, 9]. Mechanical cycling (MC) is a fatigue laboratory test that simulates the masticatory function; it also allows for the aging of specimens and may lead to a structural fracture of the root after repeated loads [10]. Barreto *et al.* [11] observed that MC alone is not able to induce dentinal defects or VRFs; however, when associated with filling techniques that involve apical pressure, VRFs may develop. Nevertheless, they only evaluated the influence of MC during the first endodontic treatment. No reported studies have analyzed the effects of the intermittent loads that are associated with the retreatment procedures on dentinal damage or the VRF formations.

Thus, the aim of this study was to evaluate the incidence of dentinal defects and the VRFs in teeth submitted to an endodontic retreatment and MC. The null hypotheses in this study were: 1) the amount of dentinal defects and the VRFs will be similar irrespective of the filling technique, the use of MC and if the evaluated specimens received endodontic treatment or re-treatment.

Materials and Methods

Teeth selection

This study was submitted and approved by the Ethical Committee of the Federal University of Santa Maria (UFSM) (Ethics Approval Number 166.458). Two hundred extracted mandibular premolars with a single root canal, a straight root, a complete root formation and an intact dental crown, were selected. The teeth were obtained from young patients, who visited the dental clinic school at UFSM, and had an extraction done that was indicated as a result of orthodontic reasons. Mesiodistal and buccolingual radiographs were performed in order to confirm the presence of only one root canal, absence of a previous endodontic treatment, absence of a root canal calcification and absence of internal resorption. All of the roots were observed under 10× magnification of a stereomicroscope (Zeiss Stemi SV6; Carl Zeiss, Gottingen, Niedersachsen, Germany) in order to detect any preexisting cracks or a fracture. Teeth with cracks on the external surface, root caries lesions, cervical lesions, root canal calcification, internal and external resorption, a canal with curvature greater than 20° and any previous endodontic treatments, were excluded. The curvature of the canals was determined by taking into account the angle of curvature according to Schneider [12]. To prevent dehydration, the teeth were kept moist in purified filtered water (Asfer, São Caetano do Sul, São Paulo, Brazil) at 4°C, prior to the experimental procedures.

Cleaning and shaping

The access was achieved by using 1014 diamond burs (KG Sorensen, Cotia, São Paulo, Brazil) and 3082 diamond burs with inactive tips (KG Sorensen, São Paulo, SP, Brazil) under water-cooling at 17 mm from the root apex. The canal patency was established with a size-10 K-file (Dentsply Maillefer, Ballaigues, Switzerland) until its tip was visible at the apical foramen. The working length (WL) was determined by subtracting 1 mm from this measurement. The mean of the WL values was 16 mm.

The periodontal ligament was simulated in all specimens in order to minimize bias caused by handling during the procedures and to mimic the mechanisms of stress distribution according to the protocol as described by Soares *et al.* [13].

The root canals were prepared with ProTaper Universal instruments (Dentsply Maillefer, Ballaigues, Switzerland) and by using a torque-control motor (X-Smart) (Dentsply Maillefer, Ballaigues, Switzerland) rotating at 300 rpm and with a torque of 2.5 N/cm. Initially, the cervical and the middle third of the roots were prepared by using S1, SX, and S2 instruments, with movements of brushing until a resistance was reached. Only teeth with an initial apical instrument of sizes #20 and #25 K-files (Dentsply Maillefer, Ballaigues, Switzerland) were selected and those with an apical anatomic diameter greater than a #25 K-file were excluded from the study and replaced by others that met the inclusion criteria. The teeth were randomly assigned (Random Allocation software, Microsoft, Redmond, Washington, USA) to five groups ($n=40$) as follows: Control group (CT), lateral compaction (LC), single-cone (SC); lateral compaction after retreatment (LCR), and single-cone after retreatment (SCR). Stratified randomization was performed when considering the apical anatomic diameter of the root canal (equal to K-file #20 or #25).

The control group was left unprepared. In the other groups, the root canals were prepared by a pecking motion using ProTaper instruments S1, S2, F1, F2, and F3, in a sequential way in all of the WL. Between each instrument change, the canals were irrigated with 3 mL of a 2.5% solution of sodium hypochlorite (NaOCl) (Biodinâmica, Ibioporã, Paraná, Brazil) using a syringe with a NaviTip irrigation needle (Ultradent, Munich, Bavaria, Germany). After completion of the procedures, the canals were irrigated with 2 mL of 17% ethylenediaminetetraacetic acid (EDTA) (Biodinâmica, Ibioporã, Paraná, Brazil) for 3 min, and then subsequently rinsed with 2 mL of distilled water. Next, the canals were dried using size 30 paper points (Dentsply Maillefer, Ballaigues, Switzerland).

Root canal filling

The epoxy resin-based sealer (AH-Plus, Dentsply, DeTrey GmbH, Konstanz, Germany) was mixed according to the manufacturer's instructions and placed into the canal to be 1 mm short of the WL, by using a 400-rpm Lentulo spiral (Dentsply Maillefer, Ballaigues, Switzerland) for 5 sec. Two of the groups were filled with a lateral compaction (LC/LCR) as follows: *a)* The main gutta-percha cones of size 30 and with a taper of 2% (Dentsply Maillefer, Ballaigues, Switzerland) were coated with the sealer and placed into the root canal to the WL; *b)* Additional FM gutta-percha cones (Dentsply Maillefer, Ballaigues, Switzerland) were placed by using a stainless steel C spreader (D1 diameter 0.3 mm, 0.04 taper) (Dentsply Maillefer, Ballaigues, Switzerland) to the depth at which a resistance was met. The compaction load was controlled by a digital scale and kept at a maximum of 1.3 Kg. The other two groups were filled with a single cone (SC/SCR); the ProTaper F3 gutta-percha cones (Dentsply Maillefer, Ballaigues, Switzerland) were coated with the sealer and placed into the root canal to the WL. The excess gutta-percha was removed with a flame-heated plugger.

In the LC and SC groups, the access cavity was etched with 37% phosphoric acid for 15 sec, rinsed for 30 sec, and then gently air-dried. Single Bond (3M ESPE, St Paul, Minnesota, USA) adhesive system was applied following the manufacturer's instructions. Finally, a Filtek Z350 (3M ESPE) composite resin was adapted into the coronal openings and light-cured from an occlusal aspect for 30 sec. In the LCR and SCR groups, the access cavity was filled with Cavit (3M ESPE, St Paul, Minnesota, USA) and stored until the retreatment procedures were reached.

Retreatment procedures

After three weeks [2], in the LCR and SCR groups, the filling material was removed by using ProTaper retreatment files (D1, D2, and D3) (Dentsply Maillefer, Ballaigues, Switzerland) that were used sequentially until the WL was reached. The instruments were used with a torque-control motor (X-Smart) at a constant speed of 500 rpm and with a torque of 3 N/cm. Hedström files of sizes #20, #25 and #30 (Dentsply Maillefer, Ballaigues, Switzerland) were used to assist with the removal of the filling material. The roots were rendered clean when no filling debris was observed in the instrument flutes or in the irrigation solutions. New radiographs were performed in order to confirm the absence of any bulk filling.

The root canals were re-prepared with ProTaper rotatory files up to the size F5 (Dentsply Maillefer, Ballaigues, Switzerland) as described previously. Thereafter, the samples were dried by using size 50 paper points (Dentsply Maillefer,

Ballaigues, Switzerland). The canals from the LCR group were re-filled by using the lateral compaction technique with a size 50, taper 0.02 gutta-percha cone (Dentsply Maillefer, Ballaigues, Switzerland) plus FM accessory cones (Dentsply Maillefer, Ballaigues, Switzerland). The canals from the SCR group were refilled by the single-cone technique and using a ProTaper F5 gutta-percha cone (Dentsply Maillefer, Ballaigues, Switzerland). AH-Plus was handled and inserted into the root canal as described before. After conclusion, the cavity access was filled with a composite resin using the same protocol as described previously and then the roots were stored for 1 week at 37°C with a 100% humidity to allow the sealer to set [11].

Mechanical cycling

The specimens from all of the groups were then positioned in a mechanical cycling machine (MC) (ERIOS, São Paulo, SP, Brazil). A load was applied to the occlusal aspect of the specimens in a wet environment (MC settings: 130 N, 2.2 Hz and 37°C) [14]. The samples were subjected to 1000000 cycles, which is equivalent to a 1-year clinical function [12].

Sectioning and microscopic observations

All of the roots were horizontally sectioned at 3, 6, and 9 mm from the apex by using a low-speed saw and underwater cooling (ISOMET 1000, Lake Bluff, Illinois, USA). The slices were then viewed through a 20× magnification stereomicroscope using a cold light source (Zeiss Stemi SV6; Carl Zeiss, Gottingen, Germany). The pictures were saved in a TIFF format and analyzed by two blinded examiners who had previously been calibrated to the measurement procedure (Kappa inter- and intra-examiner reliability values were 0.88 and 0.79, respectively). The same observers read the stereomicroscopic images twice with a 1-week interval between the readings. Any cases of disagreement were reanalyzed collectively until a consensus was reached. The dentin was inspected and the specimens were classified as follows: (A) no defect: the root dentin was devoid of any lines or cracks, with no defects on the external root surface, or in the internal root canal wall; (B) vertical root fracture: a line extending from the root canal space to the outer surface of the root; and (C) other defects: all other observable lines that did not extend from the root canal to the outer root surface [4, 12]. The teeth were considered to be fractured whenever a fracture line was observed, regardless of the slice. The most critical defect observed in each specimen was considered as a classification factor. Thus, the classification of "vertical root fracture" was the most critical defect, followed by "other defects", and finally "no defect".

Statistical analysis

The results were expressed as the number and the percentages of the defects and the VRFs in each group. Fisher's exact test and the *Chi-Squared* tests were performed by using SPSS/PC Statistics Software (SPSS version 18.0, SPSS, Chicago, Illinois, USA) in order to compare the presence of dentinal defects among the groups. The significance level was set at 0.05.

Results

The presence of dentinal defects and the VRFs are shown in [table 1](#). The control group did not present any dentinal microcracks or VRFs. The teeth with an endodontic intervention presented more dentinal defects than the unprepared teeth ($P=0.021$). In the groups that received an endodontic intervention or a re-intervention, 10.6% of the specimens presented 'other defects', although no significant differences were observed among them ($P>0.05$). The teeth that received only a primary endodontic treatment presented 8.75% of 'other defects'. The roots that were re-prepared and refilled presented 12.5% of 'other defects'. There was no difference between the different filling techniques, both in the endodontic treatments and in the retreatments ($P>0.05$). Only one VRF was observed in the SCR group. [Figure 1](#) illustrates the cross sections of the roots with and without dentinal defects.

Discussion

The results of the current study suggest that an endodontic retreatment associated with mechanical cycling, regardless of the filling techniques, does not induce a greater number of dentinal defects and VRFs when compared to a primary endodontic treatment.

It has been reported that the damage to a root dentin, that was caused by preparation and filling, have a progressively accumulative nature. The preparation and the filling techniques result in more damage than the preparation alone [4], whereas the preparation, the filling, and the retreatment, result in even more defects [2]. During an endodontic retreatment, the teeth are twice subjected to endodontic procedures. This means that

more dentin is removed and more stresses are generated in the root canal walls [15]. Shemesh *et al.* [2] observed that the removal of the filling material during retreatment caused more dentinal defects than in the preparation and in the obturation alone. In this study, even after the removal of the filling material, the re-preparation, the refilling, and the simulation of a masticatory condition, the groups submitted to the retreatments did not differ statistically from the groups submitted to a primary endodontic treatment. This was with regard to the number of dentinal defects and VRFs.

The low incidence of dentinal defects found in the present study may be attributed to the sample characteristics, since most of the selected teeth were extracted for orthodontic reasons. It indicates that the teeth came mostly from young patients. Shemesh *et al.* [2], reported a high rate of dentinal cracks after an endodontic retreatment. In their study, the premolars that were extracted for periodontal reasons and that were used in their research could infer that these teeth came from older patients. It is known that in the procedures that generate tensions, a young root dentin presents better mechanical properties when in comparison with an older dentin [14, 16]. Furthermore, in this study, we only used teeth with an intact dental crown. According to Sornokul and Stannard [17], the presence of a crown increases the fracture resistance of the tooth structure. Another possible explanation is that the dentin has a proportionality limit of 171 MPa [18, 19], which provides this kind of a structure with a reversible deformation. It means that to get a permanent defect, this limit should be exceeded. Kim *et al.* [20] reported that endodontic procedures generated von Mises values of 98.1 MPa, *ie* the tensions generated by the endodontic procedures do not exceed the limit of proportionality of the dentin (171 MPa) and therefore are not capable of generating irreversible deformations such as cracks and fractures, which is in agreement with the results of this current experiment.

Several studies have reported that the use of rotary instruments may cause a high incidence of root dentinal cracks. The current findings differ from these particular studies, because only low rates of dentinal defects and VRFs were observed.

Table 1. Number and percentages of teeth with 'VRFs' or 'other defects' [lateral compaction (LC), single-cone (SC), lateral compaction retreatment (LCR) and single-cone retreatment (SCR)]

	Control (n=40)	Primary endodontic treatment		Retreatment	
		LCT (n=40)	SCT (n=40)	LCTR (n=40)	SCTR (n=40)
Other defects	0	4 (10%)	3 (7.5%)	7 (17.5%)	3 (7.5%)
Vertical Root Fracture	0	0	0	0	1 (2.5%)

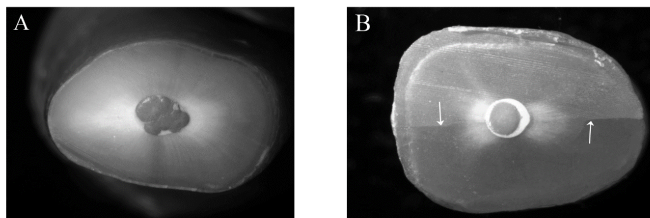


Figure 1: A) Cross section of a root showing: 'no defects'; B) An incomplete microcrack (white arrow) caused by a root canal procedure (20× magnification)

In this study, the teeth with an anatomical diameter of up to 0.25 mm were used. The enlargement of the root canal in the primary treatment and in the retreatment was performed with up to F3 and F5 ProTaper files, which have an initial diameter of 0.30 and 0.50 mm, respectively. Perhaps, the enlargement was not enough to completely touch the canal walls. On the other hand, it is known that due to a high variability and an anatomical complexity of the root canals, no technique and no rotary system is capable of touching all of the walls [21, 22].

This corroborates with De Deus *et al.* [23] evaluated the frequency of dentinal cracks through a micro-computed tomographic and observed that the dentinal defects identified in the postoperative scans were already present in the corresponding preoperative images. They claimed that a root canal preparation did not cause the formation of new dentinal defects. In this study, the outer surface of all roots was inspected with a stereomicroscope and also with periapical radiographs, to exclude those who presented dentinal microcracks prior to the start of the experiment. Some internal cracks can be present and cannot be visible on the external surface of the root. However, the results presented in control group confirmed the absence of VRF's or dentin defects prior to the experiment.

Although some literature studies have associated the lateral compaction technique with a greater presence of dentinal defects [4] and VRFs [6], the results of this study have shown that the root canal filling techniques do not interfere in the development of such defects. It is known that the load required to induce a VRF ranges between 7 and 17 kg [24, 25]. These studies have shown that the force needed to fracture a root is much higher than the force applied to the spacer during a lateral compaction (1.3 Kg) [25]. According to the findings of this study, it is also believed that this strength is not able to generate defects in the root canal walls. This also explains the absence of VRFs in the LC and LCR groups. The fact that only 1 VRF was found in the SCR group, where no compression load was applied during the filling procedures, it could be justified by the previous

existence of internal microcracks that were not visible during the teeth selection. A microscopic evaluation during the tooth selection procedures seems to be a limitation of this study. More accurate methods, such as a micro-CT, have been described, in order to better the detection of preoperative cracks [21]; this could guide the sample selection for new studies.

The induction of additional tensions to the dental structure, such as the simulation of masticatory functions, may contribute to change the small dentinal defects into greater defects or VRFs [5, 7]. However, in the control group, no defects and no VRFs were observed, showing that mechanical cycling alone is not able to induce dentinal defects. This is in accordance with a previous study [9]. One million mechanical cycles were used in the current experiment which is equivalent to a 1-year clinical function [5]. The low incidence of defects showed that this amount of mechanical cycling seems to be not enough to potentiate such defects. It is suggested, therefore, that longer periods of mechanical cycling should be evaluated.

Conclusion

When considering the test conditions and the limitations of this *in vitro* research, it can be concluded that a nonsurgical endodontic retreatment, associated with a masticatory load simulation, led to a low incidence of dentinal defects and VRFs. Furthermore, the filling techniques did not interfere in the incidence of dentinal defects and VRFs in the mandibular premolars.

Acknowledgment

The authors deny any conflict of interest related to this paper

Conflict of Interest: 'None declared'.

References

1. Mandel E, Friedman S. Endodontic retreatment: a rational approach to root canal reinstrumentation. *J Endod.* 1992;18(11):565-9.
2. Shemesh H, Roeleveld AC, Wesselink PR, Wu MK. Damage to root dentin during retreatment procedures. *J Endod.* 2011;37(1):63-6.
3. Bier CA, Shemesh H, Tanomaru-Filho M, Wesselink PR, Wu MK. The ability of different nickel-titanium rotary instruments to induce dentinal damage during canal preparation. *J Endod.* 2009;35(2):236-8.

4. Shemesh H, Bier CA, Wu MK, Tanomaru-Filho M, Wesselink PR. The effects of canal preparation and filling on the incidence of dentinal defects. *Int Endod J*. 2009;42(3):208-13.
5. Gholami F, Kohani P, Aalaei S. Effect of Nickel-Chromium and Non-Precious Gold Color Alloy Cast Posts on Fracture Resistance of Endodontically Treated Teeth. *Iran Endod J*. 2017;12(3):303-6.
6. Wiskott HW, Nicholls JI, Belser UC. Stress fatigue: basic principles and prosthodontic implications. *Int J Prosthodont*. 1995;8(2):105-16.
7. Meister F, Jr., Lommel TJ, Gerstein H. Diagnosis and possible causes of vertical root fractures. *Oral Surg Oral Med Oral Pathol*. 1980;49(3):243-53.
8. Dang DA, Walton RE. Vertical root fracture and root distortion: effect of spreader design. *J Endod*. 1989;15(7):294-301.
9. Jalali S, Eftekhari B, Paymanpour P, Yazdizadeh M, Jafarzadeh M. Effects of Reciproc, Mtwo and ProTaper Instruments on Formation of Root Fracture. *Iran Endod J*. 2015;10(4):252-5.
10. Valandro LF, Baldissara P, Galhano GA, Melo RM, Mallmann A, Scotti R, Bottino MA. Effect of mechanical cycling on the push-out bond strength of fiber posts adhesively bonded to human root dentin. *Oper Dent*. 2007;32(6):579-88.
11. Barreto MS, Moraes Rdo A, Rosa RA, Moreira CH, So MV, Bier CA. Vertical root fractures and dentin defects: effects of root canal preparation, filling, and mechanical cycling. *J Endod*. 2012;38(8):1135-9.
12. Schneider SW. A comparison of canal preparations in straight and curved root canals. *Oral Surg Oral Med Oral Pathol*. 1971;32(2):271-5.
13. Soares CJ, Pizi EC, Fonseca RB, Martins LR. Influence of root embedment material and periodontal ligament simulation on fracture resistance tests. *Braz Oral Res*. 2005;19(1):11-6.
14. Xu H, Zheng Q, Shao Y, Song F, Zhang L, Wang Q, Huang D. The effects of ageing on the biomechanical properties of root dentine and fracture. *J Dent*. 2014;42(3):305-11.
15. Wilcox LR, Roskelley C, Sutton T. The relationship of root canal enlargement to finger-spreader induced vertical root fracture. *J Endod*. 1997;23(8):533-4.
16. Arola D, Reprogl RK. Effects of aging on the mechanical behavior of human dentin. *Biomaterials*. 2005;26(18):4051-61.
17. Sornkul E, Stannard JG. Strength of roots before and after endodontic treatment and restoration. *J Endod*. 1992;18(9):440-3.
18. Craig RG, Peyton FA. Elastic and mechanical properties of human dentin. *J Dent Res*. 1958;37(4):710-8.
19. Renson CE, Braden M. Experimental determination of the rigidity modulus, Poisson's ratio and elastic limit in shear of human dentine. *Arch Oral Biol*. 1975;20(1):43-7.
20. Kim HC, Sung SY, Ha JH, Solomonov M, Lee JM, Lee CJ, Kim BM. Stress generation during self-adjusting file movement: minimally invasive instrumentation. *J Endod*. 2013;39(12):1572-5.
21. Siqueira JF, Jr., Araujo MC, Garcia PF, Fraga RC, Dantas CJ. Histological evaluation of the effectiveness of five instrumentation techniques for cleaning the apical third of root canals. *J Endod*. 1997;23(8):499-502.
22. Evans GE, Speight PM, Gulabivala K. The influence of preparation technique and sodium hypochlorite on removal of pulp and predentine from root canals of posterior teeth. *Int Endod J*. 2001;34(4):322-30.
23. De-Deus G, Belladonna FG, Souza EM, Silva EJ, Neves Ade A, Alves H, Lopes RT, Versiani MA. Micro-computed Tomographic Assessment on the Effect of ProTaper Next and Twisted File Adaptive Systems on Dentinal Cracks. *J Endod*. 2015;41(7):1116-9.
24. Pitts DL, Matheny HE, Nicholls JI. An in vitro study of spreader loads required to cause vertical root fracture during lateral condensation. *J Endod*. 1983;9(12):544-50.
25. Lertchirakarn V, Palamara JE, Messer HH. Load and strain during lateral condensation and vertical root fracture. *J Endod*. 1999;25(2):99-104.

Please cite this paper as: De Carlo Bello M, Pillar R, Mastella Lang P, Michelon C, Abreu da Rosa R, Souza Bier CA. Incidence of Dentinal Defects and Vertical Root Fractures after Endodontic Retreatment and Mechanical Cycling. *Iran Endod J*. 2017;12(4):502-7. Doi: 10.22037/iej.v12i4.16587.