

Safoora Sahebi<sup>1</sup> DDS, MS, Vahid Dolatkhah<sup>2</sup> DDS, Nooshin Sadat Shojaee<sup>2\*</sup> DDS

## Management of a crown-root fracture in central incisors with 180° rotation: A case report

1. Assistant Professor of Endodontics, Dental School, Shiraz University of Medical Science, Shiraz, Iran.

2. Postgraduate Student of Endodontics, Dental School, Shiraz University of Medical Science, Shiraz, Iran. \*Correspondence author E-mail: nooshin\_sadat\_shojaee@yahoo.com

**ABSTRACT:** The crown-root fracture is a common tooth injury which compromises the biological width and need proper endodontic and prosthodontic treatment to achieve acceptable clinical outcome. This case report describes clinical management of crown-root fracture in maxillary central incisors which was successfully treated by forceps eruption with 180° rotation to restore the biological width. The patient was followed-up for 18 months. Clinical and radiographic evaluation showed acceptable results, the replanted teeth have normal function and no obvious inflammatory root resorption was seen on radiographic examination.

**KEYWORDS:** Biologic width, Forceps eruption, Tooth fractures, Tooth injuries.

Received March 2011; accepted July 2011

### INTRODUCTION

Maxillary central incisors are the most prone teeth to traumas and injuries (1,2). The crown-root fracture is a common injury usually occur after sever horizontal trauma. This type of tooth injury is defined as a fracture involving enamel, dentin, and root cementum and sometimes it extends longitudinally to the subgingival area (3) and compromise the biologic width (4). The biological width is the distance from gingival margin to crestal bone, involving biological gingival sulcus; junctional epithelium and conjunctive attachment (4). To perform a coronal restoration, it is necessary to re-establish the biological width so that the margin of restoration can be placed appropriately without invading periodontal structures.

For establishing the invaded biological width there are some therapeutic procedures such as surgical extrusion with osteotomy and apical placement of flap, and orthodontic extrusion (5). Surgical extrusion cannot often provide good esthetic results and relapse of the root is a common finding as a result of stretched marginal periodontal attachment in orthodontic extrusion (6-8).

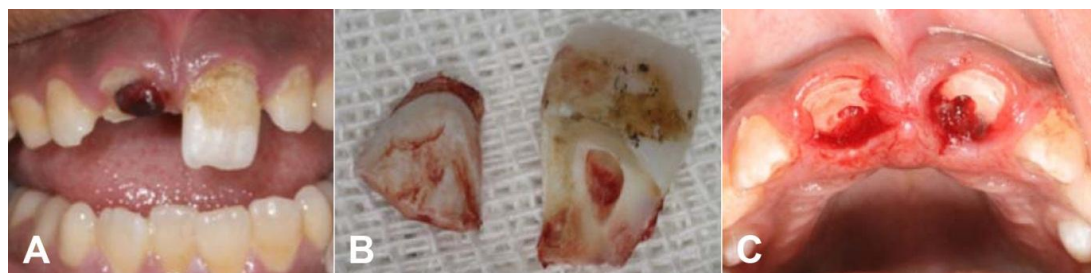
Forceps eruption or intentional replantation is

another therapeutic procedure to achieve biologic width which was first introduced by Tegsjö *et al.* (9) and then was developed by Buhler (10) and Kahnberg *et al.* (11). Intentional replantation with tooth rotation consists of surgically tooth extraction and its placement in a more coronally position; thus, this allows a better restorative re-establishment, and recovers biological width (4). According to Bender and Rossman, the procedure is contraindicated in teeth with periodontal disease and pronounced mobility or gingival inflammation (12). The success of this procedure is directly related to accurate case selection based on clinical and radiographic evaluation (3).

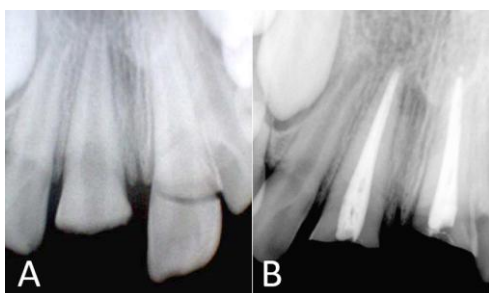
This case reports a crown-root fracture in maxillary central incisors which was successfully treated by forceps eruption with 180° rotation.

### CASE REPORT

A 12-year old male was referred to Shiraz Dental University, Department of Endodontics, because of crown-root fracture of both maxillary central incisors as a result of a bicycle accident 3 days before. The patient had no medical history; periodontal status was normal based on clinical inspection and periodontal probing. The roots had no mobility and no sign of gingival inflammation



**Figure 1. A:** Maxillary central incisors with invasion of biological width. **B:** Fractured fragments of both teeth. **C:** Clinical view (palatal) after coronal fragment was removed.



**Figure 2. A:** Radiographic image before treatment **B:** Radiographic image after root canal therapy

or periodontal attachment loss was detected. Clinical and radiographic examinations confirmed crown-root fracture (Figure 1A). The vitality tests on adjacent teeth revealed that teeth were all within normal limits. After local anesthesia the fracture fragments were carefully removed and the dental remnants were disarticulated (Figure 1B). Delicate inspection revealed that the teeth margins were placed subgingivally and were extended apically to the alveolar crest on the lingual side. As we expected, the pulp injury had been occurred in both teeth (Figure 1C). Intra-canal posts were needed to accomplish good restorations. The root end were mature and developed so that an effective apical seal was expected (Figure 2). Root canal therapy was performed on both teeth. Under isolated condition using cotton rolls the root canals were prepared. The canal enlargement was conducted using Gates Glidden drills no. 2, 3 (Dentsply, Maillefer, Ballaigues, Switzerland) and ProTaper rotary instruments (Dentsply, Maillefer, Ballaigues, Switzerland) according to the manufacturer with 2.5% NaOCl irrigation. After chemical and mechanical root canal preparation, the canals were dried with paper points, and then obturated with gutta-percha and AH Plus (Dentsply DeTrey GmbH, Konstanz, Germany) by lateral compaction technique. Coronal 2mm of gutta-percha was removed with a heated plugger to provide

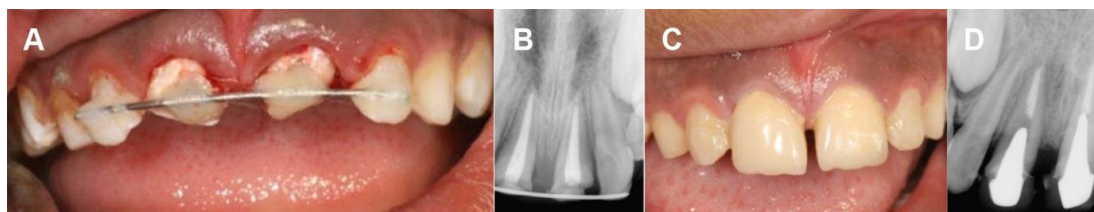
sufficient space for placement of composite resin which was applied as a part of splint. This 2mm plug of composite resin would also provide acceptable coronal seal until the definitive restoration had been placed.

The rotational forceps eruption was used in this case due to extent of fracture and with the purpose of recovering biological width with no damage of clinical crown/root ratio, and to have a better restorative re-establishment. The parents were informed about the risks and benefits of procedure and they assigned the informed consent authorizing the procedure. Teeth luxation was carefully performed with rotational motions avoiding excessive compression of the periodontal ligament towards the alveolar bone. Rotations with 180° provided adequate recovering of the biological width. The roots were inspected for any signs of crack or fracture along their surface. The roots were fixed with orthodontic wire no.5 splinted and light cured resin was applied from the left lateral incisor to the right lateral incisor. (Figure 3) occlusal adjustment was then performed.

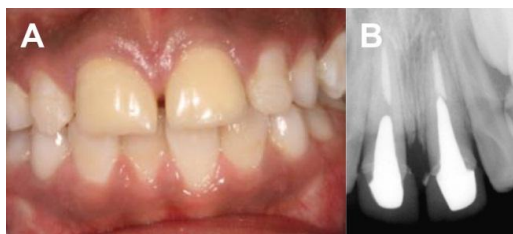The patient was advised to eat a soft diet and avoid biting with the injured teeth. Antibiotic (amoxicillin 500mg) and 0.2% chlorhexidine rinse were prescribed to prevent infection.

Seventeen days after replantation, slight mobility was detected and the splint was removed. The probing depths were normal and re-attachment had been occurred in both of the teeth. After 1 month follow-up, acceptable clinical sign and symptoms was observed, then the teeth were restored using a post and core crown (Figure 4).

The patient was followed-up after 18 months. Clinical and radiographic evaluation showed



**Figure 3.** A. Clinical aspect of the 180° rotation and semi rigid splinting. B. Radiography after splinting. C, D. Clinical photography and radiography after post and core restoration



**Figure 4.** 18 months follow-up, clinical photography and radiography shows acceptable esthetic result and periodontal/periapical status.

acceptable results in mobility test, probing depth, clinical attachment level. There were not any evidence of root resorption and alveolar bone integrity was maintained.

## DISCUSSION

The intentional replantation was first performed by Tegsjö *et al.* and is indicated in cases of crown-root fractures, cervical caries, root resorption or perforations (4). Kim *et al.* described surgical extrusion procedure in which after gentle luxation of the tooth, the position of the tooth was adjusted according to the new biologic width (13). They showed that periodontium can be recovered functionally and esthetically.

There are limited data on the survival rate of intentionally replanted teeth. It is obvious that fracture of the teeth or alveolar bone which lead to missing of teeth is the most concern. Root resorption, inflammatory response or ankylosis can be seen in dental replantation procedures. Success rate of intentional replantation was reported between 72.0% and 80.6% (12,14). A traumatic handling and stabilization of the root were found to be the critical points for achieving good results (15). Kahnberg (15) demonstrated excellent 5 years prognosis for the survival of the teeth which had been treated with this method. Furthermore, complete healing of periodontal ligament was observed in 75% of cases. Bender and Rossman (12) reported success rate of

80.6% for this procedure in cases of previously failed conventional endodontic treatment teeth. They recommended this method for cases which are difficult in accessibility and when there are anatomical limitations. They stated contra-indication of this method in cases with high mobility and gingival inflammation. Khayat and Fatehi demonstrated successful outcomes for this procedure (16). In this study none of the cases showed ankylosis, abnormal mobility, and sensitivity to percussion or palpation. PDL healing was found in 95% of cases after 12 months. But authors also suggest further evaluation of the cases.

Minimal trauma to periodontal ligament, which reduces ankylosis and root resorption of the tooth, is the most critical factor for success. When trauma to the PDL fibers is minimal, the healing process occurs by cemental healing which leads to normal structure of the periodontium. In cases of severe trauma the chance of root resorption or ankylosis increases (17). Preserving severe traumatized tooth, like intrusion or avulsion with prolonged extra-oral time, should be considered with caution. Ankylosis will replace the whole root with bone, arrest the growth of the alveolar process, then tooth will be infra-occlusion. The worst outcome is severe bone defect which is very difficult to recover (18,19). Therefore, if the possibility of ankylosis is high, preserving the tooth is not logical.

The time for the re-attachment of the PDL fibers is about two weeks (20). When the procedure is non-traumatized inflammation is minimum; therefore, PDL cells can differentiate properly and normal re-attachment can be occurred. An old animal study in which intentional replantation on dogs performed showed that periodontal ligament can be re-establish successfully and teeth can survive permanently (21).

In making decisions for treatment of these

teeth, patient age, root developmental stage, patient preference and final outcome of each treatment option should be considered.

There were some possible options for the treatment of this case: orthodontic force eruption, surgical crown lengthening with osseous surgery, decoronation of the teeth and temporary partial denture, and forceps eruption (intentional replantation). Among these options, forceps eruption was selected. Intra-alveolar transplantation or forceps eruption is a kind of intentional replantation which is done in cases of complicated crown root fracture (9).

Considering the esthetic importance in anterior part of the jaw, treatment of the teeth with crown root fractures or deep cervical root caries, can be completed with this method, long duration follow-ups indicated the good long-term prognosis for these teeth (22). Replantation of fractured teeth with compromised margins below the gingival border or bone can improve achieving better periodontal healing. Development of narrow periodontal pockets along the fracture line will be avoided (23). In anterior teeth especially in upper jaw when a deep lingual crown root fracture occurs, tooth can be rotated towards facial side to achieve a more accessible coronal position of the fracture line. This approach is beneficial for re-establishing the biologic width and placement of permanent restoration (3). In this case, incisors were rotated 180° due to the deep fracture line and satisfactory coronal restorations were placed. Another reason for this rotation was the retention of the root in the socket. One of the drawbacks of replantation technique is that the periodontal ligament may fail to attach on the root surface (24), but in this case 18 months follow-up revealed healthy periodontal attachment without any pocket in both teeth. In this case, forceps eruption was the only possible choice between the 4 mentioned options. Orthodontic forced eruption was not a good option because it could lead into the undesirable coronal movement of marginal gingiva and alveolar bone. On the other hand relapse of the extruded tooth is a major problem which can compromise the results (16). Additionally, this procedure is expensive and time consuming.

Surgical crown lengthening with apically positioned flap involves surgical removal of the

marginal gingiva; it can lead to undesirable esthetic results. Performing this procedure, especially in the anterior of the maxilla, should be done with caution. This procedure is contraindicated in patients with high exposure of gingival margin. Surgical crown lengthening also requires osteotomy in this region and it has been said that it could cause resorption of the labial cortical plate and could later compromise the bone configuration for placing dental implants (18). Surgical crown lengthening should be considered with caution. If the prognosis of this treatment is questionable, it should be ruled out.

It should be noted that placement of implant during childhood is contraindicated (25). It has been suggested that the ideal age for implant placement is at the end of alveolar growth (18). Since implants act like an ankylosed tooth, therefore placing an implant before this period will lead to infra-occlusion of the implant. The age of 18 is an ideal time for placement of implant, so considering the age of this patient (11 years old) implant cannot be not a good option.

After removing the coronal fractured segments the teeth was evaluated for the amount of crown/root ratio, which is important for placement of the cast post and core restoration. If the crown/root ratio was not acceptable, the roots of the fractured teeth should be preserved till 18. Since the extraction of the teeth in this region will lead to 40% to 60% bone loss in the first year, especially in the facial part of the alveolar ridge, extraction of these roots is contraindicated (26). The preservation of the roots until the completion of alveolar growth has been suggested. The coronal part of the roots should be blunted with a chisel instrument because the sharp edges of the tooth will compromise the healing process in involved area. Then the roots will be covered with a mucoperiosteal flap. The remaining root will preserve the labiolingual portion of the alveolar process. When the growth has been completed, the alveolar structure will be optimal for implant placement (27,28).

## CONCLUSION

Forceps eruption is one of the alternative procedures in complicated crown root fractures in order to maintain the damaged structures at health

condition aesthetically and functionally. For successful treatment, atraumatic extraction techniques, limited extra-oral time to control damage of the periodontal ligament and appropriate antibiotic therapy for microbiological control should be correctly indicated and performed by dental practitioner in well selected cases. Clinical and radiographic follow-up should be carried out for 5 years.

*Conflict of interest: none declared.*

## REFERENCES

1. Shulman JD, Peterson J. The association between incisor trauma and Occlusal characteristics in individuals 8-50 years of age. *Dent Traumatology* 2004;20:67-74.
2. Caldas AF Jr, Burgos ME. A retrospective study of traumatic dental injuries in a Brazilian dental trauma clinic. *Dent traumatology* 2001;17:250-3.
3. Fariniuk LF, Ferreira EL, Soresini GC, Cavali AE, Baratto Filho F. Intentional replantation with 180 degrees rotation of a crown-root fracture: a case report. *Dent traumatology* 2003;19:321-5.
4. Bittencourt G.S, Almeida F.X, Rold A. Intentional replantation with tooth rotation as indication for treatment of crown-root fractures. *Brazilian Journal of Dental Traumatology* 2009;1:2-6.
5. Magini R S, Censi J C, Bianchini M A. Reimplante intencional para tratamento de fissura longitudinal: relato clínico após acompanhamento de um ano. *Rev. Bras. Odontologia* 1997;54:1297-302.
6. Kozlovsky A, Tal H, Lieberman M. Forced eruption combined with gingival fiberotomy. A technique for clinical crown lengthening. *J Clin Periodontol* 1988;15:534-8.
7. Pontoriero R, Celenza F Jr, Ricci G, Carnevale G. Rapid extrusion with fiber resection: a combined orthodontic-periodontic treatment modality. *Int J Periodontics Restorative Dent* 1987;7:30-43.
8. Nevins M, Mellonig JT. Clinical approaches and evidence of success. *Periodontal therapy vol 1*, Chicago: Quintessence 1998.
9. Tegsjö U, Valerius-Olsson H, Olgart K. Intra-alveolar transplantation of teeth with cervical root fractures. *Swed Dent J* 1978;2:73-82.
10. Buhler H. Intra-alveolar transplantation von Einzel Wurzeln. *Quintessence int* 1987;38:1963-70.
11. Kahnberg KE, Warfvinge J, Birgersson B. Intraalveolar transplantation. (I). The use of autologous bone transplants in the periapical region. *Int J Oral Surg* 1982;11:372-9.
12. Bender IB, Rossman LE. Intentional replantation of endodontic ally treated teeth. *Oral Surg Oral Med Oral Pathol* 1993;76:623-30.
13. Kim SH, Tramontina V, Passanezi E. A new approach using the surgical extrusion procedure as an alternative for the reestablishment of biologic width. *Int J Periodontics Restorative Dent* 2004;24:39-45.
14. Raghoobar GM, Vissink A. Results of intentional replantation of molars. *J Oral Maxillofac Surg* 1999;57:240-4.
15. Kahnberg KE. Intraalveolar transplantation of teeth with crown-root fractures. *J Oral Maxillofacial Surg* 1985;43:38-42.
16. Khayat A, Fatehi SH. Clinical evaluation of forceps eruption: Reestablishing biologic width and restoring no restorable teeth. *Iranian Endodontic Journal* 2006;1:1-5.
17. Tsukiboshi M. Auto transplantation of teeth: requirements for predictable success. *Dent Traumatology* 2002;18:157-80.
18. Schwartz-Arad D, Levin L, Ashkenazi M. Treatment options of untreatable traumatized anterior maxillary teeth for future use of dental implantation. *Implant Dent* 2004;13:120-8.
19. Donaldson M, Kinirons MJ. Factors affecting the time of onset of resorption in avulsed and replanted incisor teeth in children. *Dent Traumatology* 2001;17:205-9.
20. Andreasen J O. Periodontal healing after replantation and auto transplantation of incisors in monkeys. *International Journal of Oral Surgery* 1981;10:54-61.
21. Sherman P Jr. Intentional replantation of teeth in dogs and monkeys. *J Dent Res* 1968;47:1066-71.
22. Kahnberg KE. Intra-alveolar transplantation. I. A 10-year follow-up of a method for surgical extrusion of root fractured teeth. *Swed Dent J* 1996;20:165-72.
23. Kudou Y, Kubota M .Replantation with intentional rotation of a complete vertically fractured root using adhesive resin cement. *Dent Traumatology* 2003;19:115-7.
24. Wang Z, Heffernan M, Vann WF Jr. Management of a complicated crown-root fracture in a young permanent incisor using intentional replantation. *Dent Traumatology* 2008;24:100-3.
25. Davarpanah M, Martinez H, Kebir M. *Clinical Manual of Implant Dentistry: Contraindication for Dental Implants*. St. Louis: Quintessence Publishing Co Ltd, 2003: pp.1-20.
26. Atwood DA, Coy WA. Clinical, cephalometric, and densitometric study of reduction of residual ridges. *J Prosthet Dent* 1971;26:280-95.
27. Ingle J, Bakland L.K , Baumgartner J.C: *Ingles Endodontics*. 6<sup>th</sup> Edition, BC Decker Inc.2008; vol 2: pp 1372-3.
28. Malmgren B. Decoronation: how, why, and when? *J Calif Dent Assoc* 2000;28:846-54.