



Earlobe crease as a marker of coronary heart disease: a systematic review

Jonathan Ricardo Hamonangan^{1*}, Fitri Agustina Huspa², Rien Afrianti³

¹Faculty of Medicine, Universitas Padjadjaran, Bandung, ²Department of Forensic and Medicolegal, Faculty of Medicine, Universitas Padjadjaran/Dr. Hasan Sadikin General Hospital, Bandung, ³Department of Cardiology and Vascular Medicine, Faculty of Medicine, Universitas Padjadjaran/Dr. Hasan Sadikin General Hospital, Bandung, Indonesia

ABSTRACT

Submitted: 2021-02-17
Accepted : 2021-07-03

Earlobe crease (ELC) is a wrinkle-line in the skin that surrounds the ear approximately one third of the length between the tragus and the posteroinferior edge of the earlobe. Since the first study in 1973, the relationship between ELC and coronary heart disease (CHD) remains unclear. In addition, the pathogenesis of ELC has not well described, yet. This review aimed to evaluate the relationship between CHD and the presence of ELC using the preferred reporting items for systematic reviews and meta-analyses (PRISMA) protocol. Eligible studies obtained from PubMed and Google Scholar using relevant keywords were collected. The assessment of quality of the studies was carried out based on the National Heart Lung and Blood Institute. Among 21 studies collected, 19 studies reported a correlation between the ELC and CHD indicating that ELC as a potential marker of CHD. Seven studies reported a significant association of ELC with CHD after adjusting confounding variables such as age, sex and other risk factors for atherosclerosis in analysis. Seven studies reported that subjects with ELC had more significantly severe CHD based on coronary angiography. The sensitivity of the ELC was reported between 30-98% and the specificity between 43-91%. Two studies reported no relationship between ELC and CHD after adjustment of age in analysis. Earlobe crease is a dermatological sign which was reported to have potential as a marker of CHD. Further study with large sample in population from various ethnics is needed in order to obtain a robust conclusion regarding the clinical importance of ELC in predicting CHD.

ABSTRAK

Earlobe crease (ELC) adalah lipatan diagonal pada daun telinga kira-kira sepertiga panjang antara tragus dan tepi posteroinferior daun telinga. Sejak penelitian pertama dilakukan pada 1973, hubungan antara ELC dan penyakit jantung koroner (PJK) tetap belum jelas. Selain itu patogenesis ELC belum digambarkan dengan baik. Kajian pustaka ini bertujuan untuk mengkaji hubungan antara PJK dengan keberadaan ELC menggunakan protokol PRISMA (*preferred reporting items for systematic reviews and meta-analyses*). Penelitian yang memenuhi persyaratan yang diperoleh dari PubMed dan Google Scholar dengan kata kunci yang relevan dikumpulkan. Penilaian kualitas penelitian dilakukan menurut the National Heart Lung and Blood Institute. Di antara 21 penelitian yang diperoleh, 19 penelitian melaporkan adanya korelasi antara ELC dan PJK yang mengindikasikan bahwa ELC merupakan marker potensial PJK. Tujuh penelitian melaporkan hubungan nyata antara ELC dan PJK setelah variabel perancu seperti usia, jenis kelamin dan faktor risiko aterosklerosis lain disesuaikan dalam analisisnya. Tujuh penelitian melaporkan bahwa subjek dengan ELC memiliki PJK lebih parah secara signifikan berdasarkan angiografi koroner. Sensitivitas ELC antara 30-98% dan spesifisitas antara 43-91%. Dua penelitian melaporkan tidak ada hubungan antara ELC dan PJK setelah variabel umur disesuaikan dalam analisisnya. *Earlobe crease* merupakan tanda dermatologis yang berpotensi sebagai penanda PJK. Penelitian lanjut dengan sampel yang lebih besar dalam populasi dari berbagai etnis diperlukan untuk memperoleh kesimpulan yang kuat mengenai pentingnya gambaran klinis ELC dalam memprediksi PJK.

Keywords:

earlobe crease;
frank's sign;
coronary heart disease;
coronary artery disease;

*corresponding author: ricosinaga5@gmail.com

INTRODUCTION

Earlobe crease (ELC) or Frank's sign is a sign of an oblique wrinkle-line in the skin covering the ear approximately one-third of the length between the tragus and the posteroinferior edge of the earlobe. Frank first reported the association between ELC and coronary heart disease (CHD) in 1973. Until now, the examination of the presence of ELC to detect CHD received little attention from health professionals. In the UK, a 1992 postmortem study reported that CHD was identified as the cause of death in men with bilateral ELC twice as likely and in women with bilateral ELC three times as likely. However, there were also several studies that denied the association between ELC and CHD. The first study to deny the association came from the United States in 1974 which examined 211 patients undergoing coronary angiography examination.¹

Since the first study in 1973, numerous reports on the relationship between ELC and CHD reported contradictory results. The pathogenesis of the ELC and its association with CHD is still unclear. Therefore, we aimed to elucidate the latest evidence regarding the association between CHD and the presence of ELC.

MATERIALS AND METHODS

Study design

The authors conducted a qualitative systematic review between July 2020 to November 2020. The study was designed and performed based on preferred reporting items for systematic reviews and meta-analyses (PRISMA) guidelines. Literature searches were conducted using PubMed and Google Scholar on 21st August 2020. The keywords were "earlobe crease" or "earlobe creases" or "earlobe creases" or "frank sign" or "frank's sign" and "coronary artery disease" or

"ischemic heart disease" or "coronary heart disease" or "atherosclerosis coronary artery disease." Observational studies that met the following criteria were included: (1) enrolled patients with CAD and without CAD, (2) investigated the presence of ELC in both group, (3) the outcome was the statistical correlation between ELC and CAD (4) written in English, and published in the last 10 years. Searches were independently conducted by all of the authors. Abstracts for all results were reviewed and relevant studies were selected for further review. Any disagreement was resolved by discussion.

Data extraction

Data were collected from the literature found in PubMed and Google Scholar. The extracted data were names of the authors, year of publication, research method, the ethnicity of subjects, number and recruitment methods of cases and controls, the association between ELC and CHD, association between ELC and CHD severity, the definition of ELC and CHD used in the study, and diagnostic values of ELC. If the data were not available, the authors wrote "not available" in the results table.

Quality assessment

The authors used the National Heart Lung and Blood Institute (NIH) assessment.² This assessment contained 14 criteria for cross-sectional and prospective cohort studies and 12 criteria for case-control studies. We gave each criterion a ranking of "Yes," "No," "cannot determine (CD)," or "not applicable (NA)". "Yes" was given one point, while "No," "CD," and "NA" did not gain any points. The findings of the assessment were set out in the appendix section.

Cross-sectional and prospective

cohort studies with $\geq 11/14$ scores were classified as high-quality studies, 7/14-11/14 scores were defined as moderate quality, and $\leq 7/14$ scores were defined as poor quality studies. Case-control studies with a score of $\geq 9/12$ were classified as high-quality studies, scores of 6/12-9/12 were defined as moderate quality studies, and scores of $\leq 6/12$ were defined as poor quality studies.

RESULTS

The first search resulted in 78 papers in PubMed and 792 articles in Google Scholar. After the authors removed the papers published before 2010, 34 articles on PubMed and 358 articles on Google Scholar were found. In Mendeley, the authors collected 392 papers. The authors then removed 102 duplications, leaving 290 articles. Subsequently, the authors removed 47 articles that were not in English, 66 articles that were not research articles, 5 articles that were not full text, and 82 research articles irrelevant to the subject discussed. Therefore, reducing the number of studies to 90.

The inclusion criteria were original research evaluating the association between ELC and CHD. Of the 90 papers read in the abstract, the authors found 19 case report articles, 5 opinion articles, 5 narrative reviews, 1 meta-analysis, and 39 research articles with irrelevant research variables. Therefore, reducing the number of studies to 21. After reading, these 21 research papers deserved to be included as data (FIGURE 1).

Quality of included studies

Based on the NIH assessment, 2 prospective-cohort studies were of high quality, 11 the cross-sectional studies were of moderate quality, 4 cross-sectional

studies and 4 case-control studies were of poor quality. Poor quality studies rarely reported clear criteria regarding ELC or CHD's operational definition, did not perform the blinded method, and did not adjust for confounding variables in statistical analyses.

The moderate and high quality studies had several strengths. First, some studies showed ELC to be associated with more severe CHD based on angiography.³⁻⁹ Second, most studies used coronary angiography in diagnosing CHD cases.³⁻¹⁶ Third, several studies reported clear criteria regarding the operational definition of ELC. At least two observers also observed the presence of ELC with a blinded method to reduce bias.^{4-7,17,18} Fourth, nine studies adjusted for confounding such as age, gender, and other risk factors for atherosclerosis in statistical analyses.^{4-7,12,17-20}

Overall results of studies

TABLE 1 displays the features of the included studies. A total of 19 studies showed that ELC was significantly associated with CHD.³⁻²² All of these studies reported that the prevalence of the presence of ELC was significantly higher in CHD patients. Kamal *et al.*²² reported that patients with bilateral or unilateral ELC were 5.63 times more likely to develop CHD. Wang *et al.*⁷ reported that patients with ELC were 4.41 times more likely to have CHD. After adjusting for conventional CHD risk factors, seven studies that performed multivariate regression analysis found that ELC remained associated with CHD.^{6,7,12,14,18,19,22} Wakasugi *et al.*²³ reported that ELC was not associated with cardiovascular disease in patients undergoing hemodialysis.

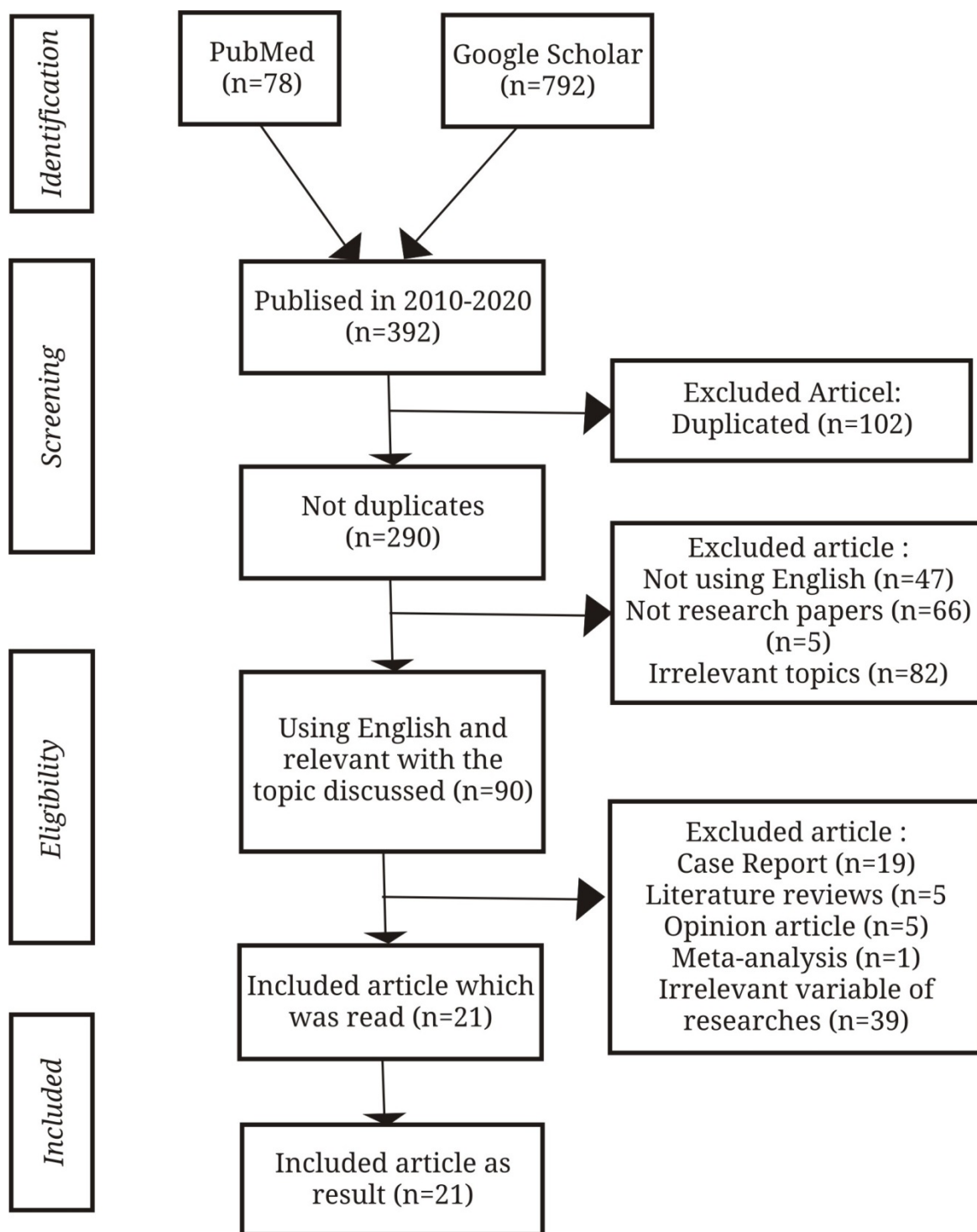


FIGURE 1. Preferred reporting items for systematic reviews and meta-analyses (PRISMA) diagram flow of this study

ELC definition and classification

Earlobe crease was first identified by Frank in 1973 as a diagonal crease in the earlobe lining from the tragus to

the posteroinferior edge of the earlobe at an angle of 45 degrees. Most studies defined ELC as a long diagonal crease over one millimeter linking the tragus to the edge of the earlobe, reaching at least

two thirds of the length of the earlobe and at an angle of about 45 degrees. Some studies also classified the presence of ELC. First, based on laterality, particularly unilateral and bilateral ELC. Second, based on the level, the level 1 as a small wrinkle on the earlobe, level 2a as a superficial fold in the earlobe, level 2b as a fold of more than half the length of the earlobe, and level 3 as a deep crease along the earlobe.^{8,14} Suen *et al.*⁴ classified ELC according to the grade as follows. Grade 0 means no crease at all; grade 1 means any crease greater than 0% but less than or equal to 50%, grade 2 means any crease greater than 50% but less than 100% across the lobe, grade 3 means a complete crease across the lobe that is superficial but not deep; and grade 4 represents any deep and prominent crease in the earlobe.⁴

Characteristics of subjects with ELC

Earlobe crease was most commonly seen in older ages^{3,5-7,12,19,21,22} and men.^{6,7,12,14,18,19,22} The mean age of patients with ELC ranged between 57 and 73. Seven studies that performed multivariate regression analysis reported that ELC was independently and significantly associated with CHD regardless of age.^{6,7,12,14,18,19,22} Patients with ELC had conventional risk factors for CHD. Bilateral and unilateral ELCs were slightly more frequent in patients with CHD who had a history of hypertension,^{3,5,7,9,12,16,22} diabetes mellitus,^{3,22} hypercholesterolemia,^{3,12} hyperlipidemia,^{5,11,13,16} and obesity.^{12,19} Earlobe crease was also commonly found in patients with a history of smoking,^{6,9,12,15,21} alcohol intake,^{6,21} and family history of cardiovascular disease.¹²

Relationship between ELC and CHD severity

Several studies examined the

association of ELC with the severity of CHD. Mishra *et al.*³ reported that the prevalence of multivessel disease (MVD) based on coronary angiography was significantly higher in patients with ELC. Shmilovich *et al.*⁵ and Sousa *et al.*⁸ also reported that the prevalence of double vessel disease (DVD) and triple vessel disease (TVD) based on coronary angiography was significantly higher in subjects with ELC. Wu *et al.*⁶ found that subjects with ELC had significantly more arterial stenosis than subjects without ELC. Wang *et al.*⁷ reported that subjects with bilateral ELC had more arterial stenosis than subjects without ELC. Subjects with ELC also had significantly higher Gensini scores. This was supported by Hou *et al.*¹² who reported that subjects with ELC and had over four risk factors for CHD had significantly higher number of blood vessel stenosis and higher Gensini scores. Hou *et al.*¹² also examined the relationship between ELC and the prognosis of CHD patients after performing percutaneous coronary intervention. Subjects with ELC were grouped based on the number of traditional CHD risk factors. Significantly, subjects with bilateral ELC who had over four risk factors for CHD had a higher risk of experiencing major adverse cardiovascular events.

Diagnostic values of ELC

Eleven studies reported the sensitivity and specificity of ELC examination in CHD as shown in TABLE 2. Sharma *et al.*¹⁴ reported the highest ELC sensitivity value (– i.e., 98.69%). Wakasugi *et al.*²³ rejected the association between ELC and cardiovascular disease and reported the lowest sensitivity value of ELC (– i.e., 30.9%). Sharma *et al.*¹⁴ reported the highest specificity value of ELC (– i.e., 91.49%), while Shmilovich *et al.*⁵ reported the lowest ELC specificity value (– i.e., 43%). Wu *et al.*⁶ reported that the sensitivity value of ELC was

higher in men, whereas the specificity was higher in women. Age >75 years had the highest sensitivity value, while those <45 years had the highest specificity value of ELC. Bawaskar *et al.*¹¹ reported that the highest sensitivity value was in men aged ≥ 50 years (– i.e., 83.5%) while the highest specificity value of ELC was in women aged <50 years (– i.e., 88.7%).

Shmilovich *et al.*⁵ reported that the area under the receiver operating

characteristic curve (AUC) value of ELC for CHD was 0.61 and the AUC value increased to 0.77 when the analysis was performed by combining ELC with the conventional risk factors for CHD. Wu *et al.*⁶ in China reported that the AUC value of ELC for CHD was 0.645 and increased to 0.722 after combining ELC and traditional risk factors for CHD. Wang *et al.*⁷ in China reported that the AUC value of ELC for CHD was 0.693.

TABLE 1. Characteristics of included studies

Methods	Authors (Country, Year)	ELC Definition	CHD definition	Ethnicity	Case Recruitment	No of Cases	Control Recruitment	No of Controls	Significant characteristics of patients with ELC	Association between ELC and CHD Severity	Association of ELC with CHD
Case-control	Suen <i>et al.</i> ⁴ (Hong Kong, 2012)	Diagonal creases on the earlobes from the lower probe of the external auditory meatus diagonally backwards to the edge of the lobe	$\geq 50\%$ stenosis in at least one of the major coronary arteries	Chinese	Angiography	50	Not clear	50	NA	NA	S
Cross-sectional	Shmilovich <i>et al.</i> ⁵ (USA, 2012)	Wrinkle extending diagonally from the tragus to rear edge of the auricle	$>50\%$ narrowing in one of the main epicardial arteries	Caucasia, Hispanic, Asian, African-American.	Angiography	71	Angiography	359	Mean age 64, hypertensive, hyperlipidemia	CHD and MVD were higher in subjects with ELC	S
Cross-sectional	Wu <i>et al.</i> ⁶ (China, 2014)	Deep crease (>1 mm) extending obliquely from tragus towards the outer border of the earlobe, covering at least two-thirds of the earlobe	$>50\%$ narrowing in one of the main epicardial arteries	Han Chinese	Angiography	250	Angiography	199	Mean age 65, males	Subjects with ELC had more CHD vascular stenosis than subjects without ELC	S
Cross-sectional	Montazeri <i>et al.</i> ¹³ (Iran, 2014)	A deep diagonal crease extending obliquely from the outer ear canal towards the border of the earlobe without discontinuity covering at least two-thirds of the earlobe length.	$\geq 50\%$ luminal diameter stenosis in one or more major epicardial vessel	NA	Angiography	80	NA	NA	Hypertensives, hyperlipidemia	NA	S
Cross-sectional	Montazeri <i>et al.</i> ¹⁶ (Iran, 2014)	A deep diagonal crease extending obliquely from the outer ear canal towards the border of the earlobe without discontinuity covering at least two-thirds of the earlobe length.	$\geq 50\%$ luminal diameter stenosis in one or more major epicardial vessel	Iranian	Angiography	100	NA	NA	Hyperlipidemia	NA	S

NA = Not Available; S = Significant; NS = Not Significant

TABLE 1. Continued

Methods	Authors (Country, Year)	ELC Definition	CHD definition	Ethnicity	Case Recruitment	No of Cases	Control Recruitment	No of Controls	Significant characteristics of patients with ELC	Association between ELC and CHD Severity	Association of ELC with CHD
Prospective-cohort	Christoffersen <i>et al.</i> ¹⁸ (Denmark, 2014)	A diagonal fold or wrinkle in the skin of the earlobe	Medical records of myocardial infarction or coronary revascularization	Danish	Medical record	3401	Medical record	7484	NA	NA	S
Cross-sectional	Hou <i>et al.</i> ¹² (China, 2015)	A wrinkle-like line extending diagonally from the tragus across the lobule to the rear edge of the auricle of the ear	>50% narrowing in one of the main epicardial arteries	Han Chinese	Angiography	281	Angiography	305	NA	Subjects with ELC who had more than four risk factors had significantly higher numbers of blood vessels stenosis and higher Gensini scores	S
Cross-sectional	López <i>et al.</i> ¹⁷ (Spain, 2015)	A line covering at least 1/3 of the length between the tragus and the posteroinferior lobe edge.	Medical records of myocardial infarction or coronary revascularization	NA	Medical record	263	NA	NA	Mean age 74.4, diabetes, hypercholesterolemia, hypertriglyceridemia	NA	S
Cross-sectional	Wang <i>et al.</i> ⁷ (China, 2016)	Deep crease (>1 mm) extending obliquely from tragus towards the outer border of the earlobe, covering at least two-thirds of the earlobe	>50% narrowing in one of the main epicardial arteries	Han Chinese	Angiography	368	Angiography	99	Mean age 65.89, males, hypertensive	Subjects with bilateral ELC had significantly more arterial stenosis than subjects with unilateral ELC and without ELC	S
Cross-sectional	Viveka <i>et al.</i> ¹⁰ (India, 2016)	Crease extended for a distance >1/3 of the earlobe length, either unilaterally or bilaterally	Definite myocardial infarction with any degree of stenosis, or >50% stenosis in more than one epicardial branch	Indian	Angiography	50	Angiography	50	NA	NA	S
Cross-sectional	Kumar ⁹ (India, 2016)	Deep diagonal crease extending obliquely from the tragus toward the posteroinferior border of earlobe, covering at least two-thirds of the earlobe length	≥50% luminal diameter stenosis in one or more major epicardial vessel	Indian	Angiography	255	NA	NA	Mean age 61.2, hypertensive, smoker	The prevalence of ELC was higher in subjects with CHD and MVD	S
Cross-sectional	Aligisakis <i>et al.</i> ¹⁹ (Swiss, 2016)	A crease in the lobule portion of the auricle	Medical records of CHD, angina pectoris, myocardial infarction, stroke and coronary artery bypass graft	Caucasian	Medical record	60	Medical record	92	Mean age 63.2, males, obese, diabete, insulin resistance or metabolic syndrome	NA	S
Case-control	Kamal <i>et al.</i> ²² (Pakistan, 2017)	Deep crease angled diagonally from lower meatus to the edge of the lobe at approximately 45 degrees covering at least 2/3rd of the lobe	Not clear	Pakistan	Angiography	100	Other inpatients	100	Hypertensives and diabetics	NA	S
Cross-sectional	Wakasugi, <i>et al.</i> ²³ (Japan, 2017)	Diagonal folds or wrinkles in the skin of the earlobe	Medical records of a clinically or electrocardiographically proven myocardial infarction, cerebrovascular accident, or peripheral vascular disease requiring aortic or peripheral vascular bypass surgery or a below- or above-the knee amputation	Japanese	Medical record	25	Medical record	56	Mean age 73.6, males	NA	NS

NA = Not Available; S = Significant; NS = Not Significant

TABLE 1. Continued

Methods	Authors (country)Research	ELC Definition	CHD definition	Ethnicity	Case Recruitment	No of Cases	Control Recruitment	No of Controls	Significant characteristics of patients with ELC	Association between ELC and CHD Severity	Association of ELC with CHD
Case-control	Ramdurg <i>et al.</i> ²¹ (India, 2018)	Deep crease angled diagonally from lower meatus to the edge of the lobe at approximately 45 degrees covering at least 2/3rd of the lobe	Not clear	Indian	Angiography	118	Not clear	80	Mean age 61.25, males	NA	S
Cross-sectional	Bawaskar <i>et al.</i> ¹¹ (India, 2018)	A deep, obliquely diagonal earlobe creases run from lower pole of the external meatus, diagonally backward to the edge of the lobe at approximately 45°	Not clear	Indian	Angiography, electrocardiography	486	Not clear	402	Diabetes, hyperlipidemia, hypertensive, obesity	NA	S
Cross-sectional	Kumar <i>et al.</i> ⁹ (India, 2018)	Crease extending diagonally from the tragus across the lobule to the rear edge of the auricle without discontinuity	≥50% luminal diameter stenosis in one or more major epicardial vessel	Indian	Angiography	150	NA	NA	Smoker	NA	S
Case-control	Sharma <i>et al.</i> ¹⁴ (India, 2018)	Not clear	Not clear	Indian	Angiography	153	Angiography	47	NA	NA	S
Cross-sectional	Mishra <i>et al.</i> ³ (India, 2020)	Not clear	Luminal stenosis of >50% in at least one epicardial arteries	Indian	Angiography	780	Angiography	290	Mean age 57.14, hypertensive, hypercholesterolemia	The prevalence of MVD was significantly higher in patients with ELC	S
Cross-sectional	Sousa <i>et al.</i> ⁸ (India, 2020)	Crease in the earlobe that extends across the lobule right from the tragus to the posterior edge of the lobule, at an angle of around 45°	History (including past medical and surgical history) and physical examination along with data on laboratory results and coronary angiography	Indian	Angiography	152	NA	NA	Age 51-70, males	DVD and TVD were significantly more common in patients with ELC	S
Prospective-cohort	Wakasugi <i>et al.</i> ²⁰ (Japan, 2020)	A line covering at least 1/3 of the length between the tragus and the posteroinferior lobe edge	Medical records of a clinically or electrocardiographically proven myocardial infarction, cerebrovascular accident, or peripheral vascular disease requiring aortic or peripheral vascular bypass surgery or a below- or above-the knee amputation	Japanese	Medical record	43	Medical record	43	Mean age 72.9	NA	NS

NA = Not Available; S = Significant; NS = Not Significant

TABLE 2. Diagnostic values of ELC

Authors (Country)	Sensitivity (%)	Specificity (%)	AUC
Mishra <i>et al.</i> ³ (India)	74	59	NA
Suen <i>et al.</i> ⁴ (Hong Kong)	61	58	NA
Ramdurg <i>et al.</i> ²¹ (India)	90	52.5	NA
Kamal <i>et al.</i> ²² (Pakistan)	76	64	NA
Shmilovich <i>et al.</i> ⁵ (US)	78	43	0.610
Wu <i>et al.</i> ⁶ (China)	75.2	53.8	0.645
Wang <i>et al.</i> ⁷ (China)	78	61	0.693
Bawaskar <i>et al.</i> ¹¹ (India)			
• Women aged < 50	46.3	88.7	
• Women aged ≥ 50	82.0	80.3	NA
• Men aged < 50	67.0	65.7	
• Men aged ≥ 50	83.5	51.6	
Sharma <i>et al.</i> ¹⁴ (India)	98.69	91.49	NA
López <i>et al.</i> ¹⁷ (Spain)	43.0	70.0	NA
Wakasugi <i>et al.</i> ²⁰ (Japan)	30.9	77.5	NA

NA = Not available

DISCUSSION

Based on this systematic review, most studies published in the last 10 years showed that ELC was associated with CHD. ELC could be an additional physical examination to detect patients who had a high risk of CHD. Most studies found that ELC was associated with more severe CHD based on coronary angiography. Seven studies performed multivariate regression analysis and proved that the relationship of ELC to CHD was independent of age, sex, and other risk factors for atherosclerosis. One of the studies was a high quality prospective cohort study with subjects from the general population conducted by Christoffersen *et al.*¹⁸

Ten studies reported fairly good sensitivity and specificity values of ELC. The sensitivity of ELC was reported to be 30-98%, and the specificity was 43-91%. This result is in line with a meta-analysis that supported ELC as marker for CHD

with a sensitivity value of 0.62 and a specificity of 0.67.²⁴ In this systematic review, Sharma *et al.*⁹ reported the highest sensitivity and specificity of ELC which was 98.69 and 91.49% respectively. This might be due to subjects with even the early grades of ELC being included in the study. Two studies also reported that the AUC value of traditional risk factors for CHD was increased by adding the presence of ELC.^{5,6}

Most studies used high-risk CHD patients as research subjects, but Wakasugi *et al.*²⁰ used patients who were undergoing hemodialysis and reported conflicting results. Based on a four-year prospective cohort study, patients undergoing hemodialysis with ELC had increased cardiovascular disease incidence compared to patients without ELC. The association was no longer significant following age adjustment in statistical analysis. This result was likely because hemodialysis patients had several non-traditional

cardiovascular risk factors, such as anemia, hyperhomocysteinemia, chronic kidney disease and bone mineral disorders, oxidative stress, malnutrition, and chronic inflammation. Substantial differences in traditional risk factors between hemodialysis patients and the non-dialysis population might influence the results. Wakasugi *et al.*²⁰ reported that ELC was only a sign of ageing.

The pathogenesis of ELC remains uncertain. Recent studies proved the role of atherosclerosis in the pathogenesis of ELC. Oda *et al.*²⁵ reported that flow-mediated vasodilation (FMD) and nitroglycerine-induced vasodilation (NID) were significantly lower in subjects with unilateral and bilateral ELC compared to subjects without ELC. Flow-mediated vasodilation (FMD) showed dilatation arteries when there is an increased blood flow caused by the release of nitrogen oxide (NO) from the endothelium. Nitroglycerine-induced vasodilation (NID) is a controlled test of FMD and was reported to be associated with atherosclerosis. Lower FMD and NID values in subjects with ELC suggested that ELC was associated with endothelial dysfunction and atherosclerosis. A recent study by Koyama *et al.*²⁶ also demonstrated the role of atherosclerosis in the pathogenesis of ELC. The study showed that levels of inflammatory markers, high-sensitivity C-reactive protein (hs-CRP) and pentraxin3 (PTX3), and oxidative stress markers, specifically malondialdehyde low-density lipoprotein (MDA-LDL), in patients with ELC were significantly higher in subjects with ELC.

Stoyanov *et al.*²⁷ suggested that the presence of ELC could be related to the embryology of the earlobe, which made the earlobe more prone to chronic hypoxia and blood reperfusion injuries. Chronic hypoxia and blood reperfusion injuries in patients with cardiovascular disease could affect the blood vessels in the ear, causing segmental myoelastofibrosis and nerve

damage, followed by Wallerian-like degeneration, leading to the formation of ELC. This was shown based on autopsy and histopathological research. Wallerian-like degeneration was reported associated with nerve injury which could be found in the myocardial after both myocardial infarction and heart failure.

Different study results from different countries have led previous studies to report the possible influence of race on the ELC pathology.¹ Despite one study by Shmilovich *et al.*⁵ used a multiethnic sample, no study investigated the relationship of ethnicity to ELC. Large research subjects with samples from various ethnicities are still needed to draw robust conclusions about the potential of ELC as an early detection of CHD.

This review has three main limitations. Firstly, although most studies used fairly consistent definitions of ELC and CHD, there were various criteria for the length of ELC. Secondly, several studies used non-CHD patients as controls without undergoing angiography. Lastly, we only select studies written in English; therefore, it may cause bias.

CONCLUSION

Earlobe crease is a dermatological sign which was reported as a marker of CHD. Earlobe crease was also reported to be correlated with ageing, such that previous studies found it was difficult to study the pathology underlying the ELC. Since age progression and other risk factors for atherosclerosis are also correlated with ELC. Future research is important to adjust statistical analyses for age, gender, and other risk factors for CHD. In addition, there is also a need for large-scale studies with samples from the general population with different ethnicities to draw robust conclusions regarding the clinical importance of ELC in detecting CHD. Further prospective-

cohort studies to establish the causal association between ELC and CHD are also needed.

Early detection of CHD patients, especially in primary care, is very critical. Based on this systematic review, the presence of ELC can be observed in patients at high risk for CHD with a reasonably good diagnostic value, accompanied by the examinations of other risk factors for CHD. Patients with ELC may theoretically benefit from further CHD testing.

ACKNOWLEDGEMENTS

We would like to thank all those who provided assistance and support in compiling the sources of this systematic review. The authors declare no conflicts of interest in preparing this article.

REFERENCES

1. Agouridis AP, Elisaf MS, Nair DR, Mikhailidis DP. Ear lobe crease: a marker of coronary artery disease? *Arch Med Sci* 2015; 11(6):1145-55. <https://doi.org/10.5114/aoms.2015.56340>
2. Study Quality Assessment Tools | NHLBI, NIH [Internet]. [cited 2020 Oct 7]. Available from: <https://www.nhlbi.nih.gov/health-topics/study-quality-assessment-tools>
3. Mishra V, Khanra D, Himanshu K, Jain B, Tripathi S, Anggarwal P, et al. Correlation between earlobe crease and coronary artery disease in Indian population-A multicentre experience. *J Clin Prev Cardiol* 2020; 9(2):67-72. https://doi.org/10.4103/JCPC.JCPC_10_20
4. Suen LKP, Lau Y, Ma HC, Lai KW, Holtoyed E. Predictive value of auricular diagnosis on coronary heart disease. *Evid Based Complement Alternat Med* 2012; 2021:706249. <https://doi.org/10.1155/2012/706249>
5. Shmilovich H, Cheng VY, Rajani R, Dey D, Tamaroppo BK, Nakazato R, et al. Relation of diagonal ear lobe crease to the presence, extent, and severity of coronary artery disease determined by coronary computed tomography angiography. *Am J Cardiol* 2012; 109(9):1283-7. <https://doi.org/10.1016/j.amjcard.2011.12.024>
6. Wu XL, Yang DY, Zhao YS, Chai WH, Jin ML. Diagonal earlobe crease and coronary artery disease in a Chinese population. *BMC Cardiovasc Disord* 2014; 14:43. <https://doi.org/10.1186/1471-2261-14-43>
7. Wang Y, Mao LH, Jia EZ, Li ZY, Ding XQ, Ge PC, et al. Relationship between diagonal earlobe creases and coronary artery disease as determined via angiography. *BMJ Open* 2016; 6(2):008558. <https://doi.org/10.1136/bmjopen-2015-008558>
8. Sousa ED, Fernandes VLG, Goel HC, Naik K, Pinto NMG. A study on the prevalence of diagonal earlobe crease in patients with cardiovascular disease and diabetes mellitus. *Indian J Otol* 2020; 26(1):9-14. https://doi.org/10.4103/indianjotol.INDIANJOTOL_117_18
9. Kumar A. Frank's sign and coronary artery disease in Indian population. *Med Hear India*. 2016. <https://doi.org/10.4103/2321-449x.196285>
10. Viveka S, Sagar TV, Kumar JA. Evaluation of 2D:4D digit ratio and diagonal earlobe crease as markers of coronary artery disease. *J Anat Soc India* 2016; 65(2):148-51. <https://doi.org/10.1016/j.jasi.2017.02.004>
11. Bawaskar HS, Bawaskar PH, Bawaskar PH. Diagonal ear lobe crease: A premonitory diagnostic sign of impending ischemic heart disease. *J Fam Med Prim care*. 2018; 7(6):1361-7. https://doi.org/10.4103/jfmpc.jfmpc_181_18
12. Hou X, Jiang Y, Wang N, Shen

- Y, Wang X, Zhong Y, *et al.* The combined effect of ear lobe crease and conventional risk factor in the diagnosis of angiographically diagnosed coronary artery disease and the short-term prognosis in patients who underwent coronary stents. *Medicine (Baltimore)*. 2015; 94(26):815.
<https://doi.org/10.1097/MD.0000000000000815>
13. Montazeri M, Montazeri M, Rashidi N, Montazeri M, Montazeri M. Diagonal earlobe crease and coronary artery disease in Iranian population: A marker for evaluating coronary risk. *Indian J Otol* 2014; 20(4):208-10.
<https://doi.org/10.4103/0971-7749.146941>
 14. Sharma RK, Pulimood S, Peter D, George L. Association of The Cutaneous Markers with Coronary Artery Disease: A Case-control Study. *Indian J Clin Dermatology* 2018; 1(1):6-11.
 15. Kumar A, Kumar A, Kumar P, Kachhap S. Study to evaluate the frequency of diagonal earlobe crease as a marker of coronary artery disease and its risk factors in tertiary hospital of east india. *Int J Sci Res* 2018; 7(1):13-4.
 16. Montazeri M, Rashidi N, Montazeri M, Melaki A, Motazeri M, Motazeri M. Is diagonal earlobe crease a marker for coronary artery disease? *Hear India*. 2014; 2(4):104-6.
<https://doi.org/10.4103/2321-449X.146614>
 17. López CR, Díaz HG, Mariscal RM, Cervilla PJS, Graciani A, Sendón JLL, *et al.* Earlobe crease shapes and cardiovascular events. *Am J Cardiol* 2015; 116(2):286-93.
<https://doi.org/10.1016/j.amjcard.2015.04.02>
 18. Christoffersen M, Frikke-Schmidt R, Schnohr P, Jensen GB, Nordestgaard BG, Tybjaerg-Hansen A. Visible age-related signs and risk of ischemic heart disease in the general population: A prospective cohort study. *Circulation* 2014; 129(9):990-8.
<https://doi.org/10.1161/CIRCULATIONAHA.113.001696>
 19. Aligisakis M, Vidal PM, Guessous I, Vollenweider P. Did Dumbo suffer a heart attack? independent association between earlobe crease and cardiovascular disease. *BMC Cardiovasc Disord* 2016; 16:17.
<https://doi.org/10.1186/s12872-016-0193-7>
 20. Wakasugi M, Nagai M, Yokota S, Omori K, Fujikawa H, Aoike I, *et al.* The association between earlobe creases and cardiovascular events in Japanese hemodialysis patients: a prospective cohort study. *Intern Med* 2020; 59(7):927-32.
<https://doi.org/10.2169/internalmedicine.3943-19>
 21. Ramdurg P, Srinivas N, Puranik S, Sande1 A. “Frank Sign”—A clinical indicator in the detection of coronary heart disease among dental patients: A case control study. *J Indian Acad Oral Med Radiol* 2018; 30(3):241-6.
https://doi.org/10.4103/jiaomr.jiaomr_90_18
 22. Kamal R, Kausar K, Qavi AH, Minto MH, Ilyas F, Assad S, *et al.* Diagonal earlobe crease as a significant marker for coronary artery disease: a case-control study. *Cureus* 2017; 9(2):e1013.
<https://doi.org/10.7759/cureus.1013>
 23. Wakasugi M, Kazama JJ, Kawamura K, Yamamoto S, Nagai M, Omori K, *et al.* Prevalence of earlobe creases and their association with history of cardiovascular disease in patients undergoing hemodialysis: a cross-sectional study. *Ther Apher Dial* 2017; 21(5):478-84.
<https://doi.org/10.1111/1744-9987.12567>
 24. Lucenteforte E, Romoli M, Zagli G, Gensini GF, Mugelli A, Vannacci A. Ear lobe crease as a marker of coronary artery disease: a meta-analysis. *Int J Cardiol* 2014; 175(1):171-5.
<https://doi.org/10.1016/j.ijcard.2014.04.025>
 25. Oda N, Maruhashi T, Kishimoto S,

- Kajikawa M, Iwamoto Y, Iwamoto A, *et al.* Relation of the Bilateral Earlobe Crease to Endothelial Dysfunction. *Am J Cardiol* 2017; 119(12):1983-8. <https://doi.org/10.1016/j.amjcard.2017.03.029>
26. Koyama T, Watanabe H, Ito H. The association of circulating inflammatory and oxidative stress biomarker levels with diagonal earlobe crease in patients with atherosclerotic diseases. *J Cardiol* 2016; 67(4):347-51. <https://doi.org/10.1016/j.jjcc.2015.06.002>
27. Stoyanov GS, Dzhenkov D, Petkova L, Sapundzhiev N, Georgiev S. The Histological Basis of Frank's Sign. *Head Neck Pathol* 2020; 15(2):402-7. <https://doi.org/10.1007/s12105-020-01205-4>